



PATIENT

Rex Grelich

SPECIES

Canine

BREED

Dogo Argentino

SEX

Male

AGE

5 ½ years

WEIGHT

-

INTERPRETED BY

Remo Lobetti, BVSc,
MMedVet (Med),
PhD, Dipl. ECVIM

IMAGING PERFORMED BY

Kerri Becker

HOSPITAL NAME

St George VH

REFERRING VET

Dr. Ng

INVOICE

71279

DATE

2/5/26

PRESENTING CLINICAL SIGNS

- Intermittent hematuria since 8/25 would temporarily resolve w/ carprofen, enroflox. No stranguria or dysuria but noticing polyuria. O declines neuter.

ULTRASONOGRAPHIC EXAMINATION OF THE ABDOMEN

Urinary System

The urinary bladder is small with a normal thickness and smooth appearance of the wall. Normal anechoic urine with no sediment or uroliths evident.

Normal appearance of the trigone area, proximal urethra, and iliac blood vessels.

Normal appearance and size of the iliac lymph nodes. Ureters not visualized, which can be considered a normal finding.

Normal renal size (left measured 7.1 cm, right measured 7.5 cm), architecture, echogenic appearance, cortico-medullary differentiation, which maintains a 1:3 cortex to medulla ratio, pelvis, and capsule. No infarcts, mineralization or renoliths evident. Normal color flow pattern is evident in both kidneys.

The prostate is symmetrically enlarged with a diffuse, hyperechogenic appearance and a regular curvilinear capsule. Normal appearance of the peri-prostatic tissue. The prostate measures 3.9 x 5.0 cm in size. Normal size and appearance of both testicles. The left testicle measured 3.1 cm in length. The right adrenal gland measured 2.9 cm in length.

Adrenal Glands

Normal shape, echogenic appearance, size, position, and appearance of the visible peri-adrenal vasculature. Left adrenal gland measured 2.25 cm in length x 0.64 cm and 0.57 cm in width. The right adrenal gland measured 2.32 cm in length x 0.47 cm in width.

Spleen

Normal size and echogenic appearance. Smooth homogenous parenchyma and regular curvilinear capsule. Normal volume of the splenic vasculature without any overt congestion or thrombosis evident. No inflammatory, neoplastic, infarction, or infiltrative changes evident. The spleen measured 2.1 cm in width.

Liver

Normal size, echogenic appearance, portal markings, and regular curvilinear capsule. No nodules or masses evident. Normal appearance of the hepatic and portal vasculature.



PATIENT

Rex Grelich

SPECIES

Canine

BREED

Dogo Argentino

SEX

Male

AGE

5 ½ years

WEIGHT

-

INTERPRETED BY

Remo Lobetti, BVSc,
MMedVet (Med),
PhD, Dipl. ECVIM

**IMAGING
PERFORMED BY**

Kerri Becker

HOSPITAL NAME

St George VH

REFERRING VET

Dr. Ng

INVOICE

71279

DATE

2/5/26

Gallbladder

The gallbladder is full containing normal anechoic bile. Normal thickness and echogenic appearance of the wall. Normal size and appearance of the cystic and common bile duct.

Gastrointestinal

Normal appearance of the stomach, duodenum, small intestine, ileo-cecal junction, and colon with no loss of layering, 1:3 muscularis to mucosa ratio, normal wall thickness and peristaltic activity, and no distension of the lumen.

Pancreas

The visible sections of the pancreas are of normal size and echogenic appearance with a regular capsule. Normal echogenic appearance of the mesentery and fat surrounding the pancreas.

Free Abdomen

Normal mesenteric lymph nodes.

No ascites evident.

ULTRASONOGRAPHIC FINDINGS

- Prostatomegaly.

INTERPRETATION OF THE FINDINGS & FURTHER RECOMMENDATIONS

The most likely etiology for the prostatomegaly would be benign prostatic hyperplasia with prostatitis a less likely differential diagnosis.

Further assessment that can be considered would be urinalysis, urine culture and prostatic wash for cytology and culture.

Management of the prostatomegaly would be either surgical or chemical castration.

Chemical castration would be the use of osaterone acetate, delmadinone acetate, or deslorelin acetate. This is less invasive and safer than surgical castration in systemically ill and potentially unstable patients.



PATIENT

Rex Grelich

SPECIES

Canine

BREED

Dogo Argentino

SEX

Male

AGE

5 ½ years

WEIGHT

-

INTERPRETED BY

Remo Lobetti, BVSc,
 MMedVet (Med),
 PhD, Dipl. ECVIM

IMAGING PERFORMED BY

Kerri Becker

HOSPITAL NAME

St George VH

REFERRING VET

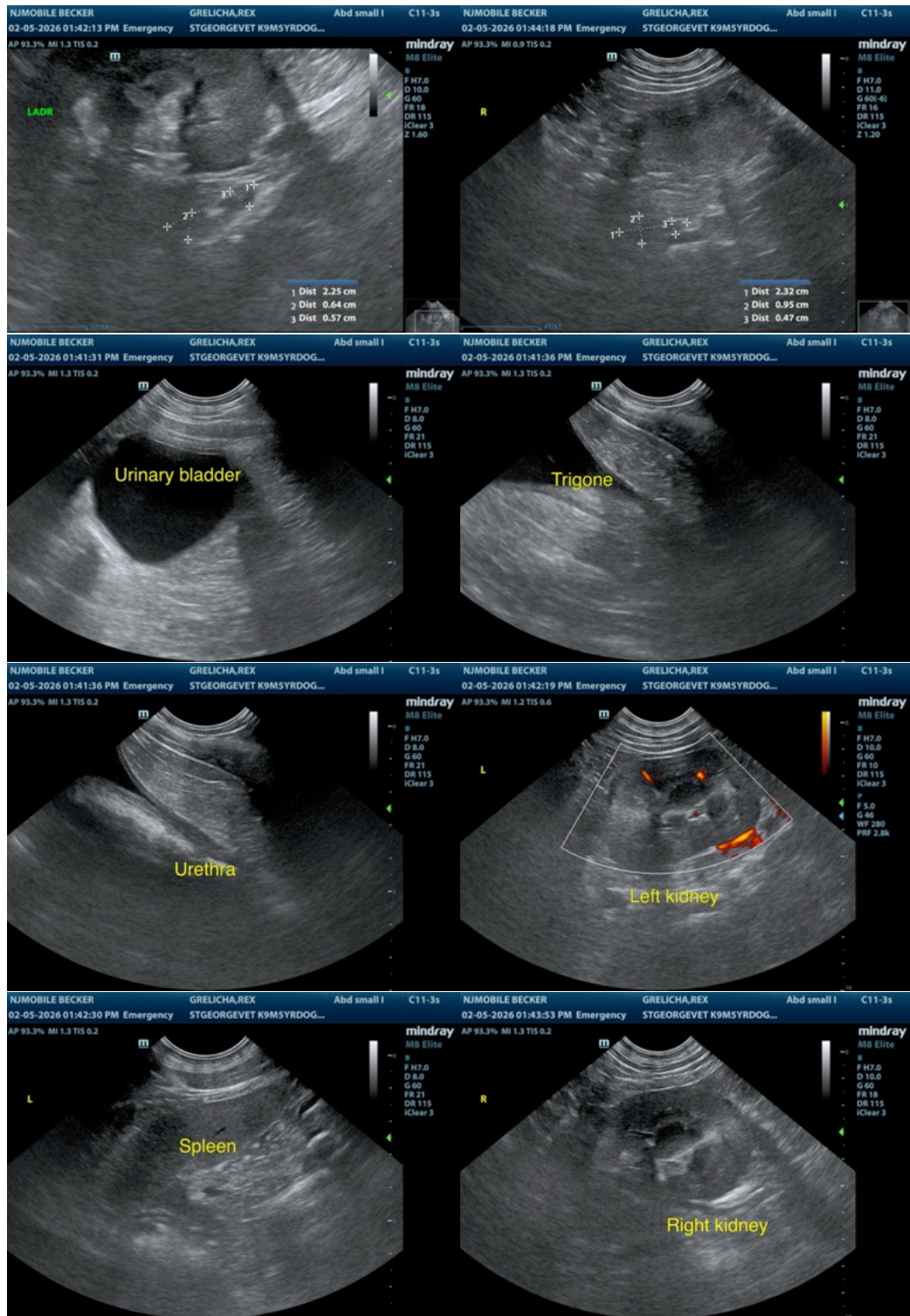
Dr. Ng

INVOICE

71279

DATE

2/5/26





PATIENT

Rex Grelich

SPECIES

Canine

BREED

Dogo Argentino

SEX

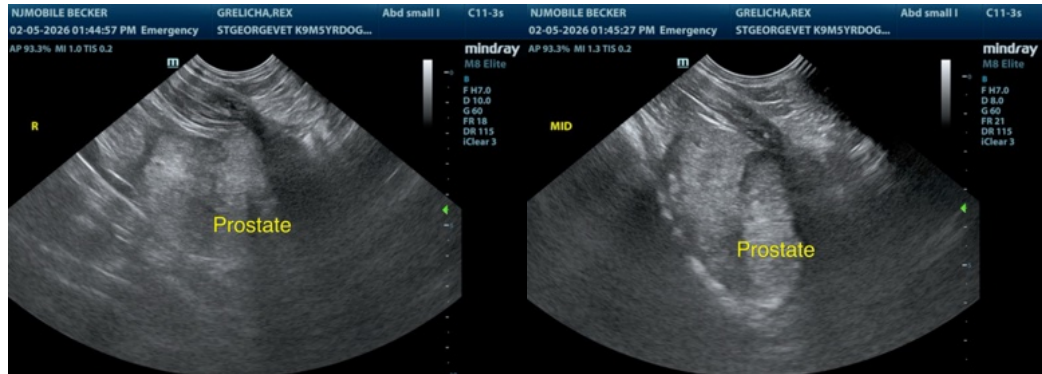Male

AGE

5 ½ years

WEIGHT

-



The information and recommendations provided are based on the images presented by the referring veterinarian/sonographer. No evaluation can be communicated regarding pathology that was not visible in the image/video clips provided.

Thank you for this referral. If the clinical or image interpretation does not parallel your findings or if I can be of any further assistance please contact me.

Remo Lobetti, BVSc, MMedVet (Med), PhD, Dipl. ECVIM (Internal Medicine)

info@sonopath.com

INTERPRETED BY

Remo Lobetti, BVSc,
MMedVet (Med),
PhD, Dipl. ECVIM

IMAGING PERFORMED BY

Kerri Becker

HOSPITAL NAME

St George VH

REFERRING VET

Dr. Ng

INVOICE

71279

DATE

2/5/26