



PATIENT

Jasper Hernandez

SPECIES

Canine

BREED

Maltipoo

SEX

Intact male

AGE

13 years

WEIGHT

15.3 lbs

INTERPRETED BY

Remo Lobetti, BVSc,
MMedVet (Med),
PhD, Dipl. ECVIM

IMAGING PERFORMED BY

Shari Reffi, CVT

HOSPITAL NAME

Smithfield AH

REFERRING VET

Dr. Hull

INVOICE

71265

DATE

2/5/26

PRESENTING CLINICAL SIGNS

- Perineal hernia. Prominent prostate on rads. Rectal-perineal hernia (could not palpate prost)
- Current Meds: Gaba/Traz
- Elevated neuts and monos

ULTRASONOGRAPHIC EXAMINATION OF THE ABDOMEN

Urinary System

The urinary bladder is small with a normal thickness and smooth appearance of the wall. Normal anechoic urine with no sediment or uroliths evident.

Normal appearance of the trigone area, proximal urethra, and iliac blood vessels.

Normal appearance and size of the iliac lymph nodes. Ureters not visualized, which can be considered a normal finding.

Normal renal size (left measured 3.7 cm, right measured 3.3 cm), architecture, echogenic appearance, cortico-medullary differentiation, which maintains a 1:3 cortex to medulla ratio, pelvis, and capsule. No infarcts, mineralization or renoliths evident. Normal color flow pattern is evident in both kidneys.

The prostate is symmetrically enlarged with a diffuse, mottled echogenic and coarse appearance, but maintained a regular curvilinear capsule. The prostate measures 2.8 x 3.0 cm in size. Normal size of both testicles. The left testicle measured 2.3 cm in length. The right testicle measured 2.1 cm in length. Focal, parenchymal hypoechogenic nodule in the left testicle measuring 0.6 cm in size.

Adrenal Glands

Normal shape, echogenic appearance, size, position, and appearance of the visible peri-adrenal vasculature. Left adrenal gland measured 0.54 cm and 0.49 cm in width. The right adrenal gland measured 0.48 cm and 0.68 cm in width.

Spleen

Normal size and echogenic appearance. Smooth homogenous parenchyma and regular curvilinear capsule. Normal volume of the splenic vasculature without any overt congestion or thrombosis evident. No inflammatory, neoplastic, infarction, or infiltrative changes evident. The spleen measured 1.2 cm in width.

Liver

Normal size, echogenic appearance, portal markings, and regular curvilinear capsule. No nodules or masses evident. Normal appearance of the hepatic and portal vasculature.



PATIENT

Jasper Hernandez

SPECIES

Canine

BREED

Maltipoo

SEX

Intact male

AGE

13 years

WEIGHT

15.3 lbs

INTERPRETED BY

Remo Lobetti, BVSc,
MMedVet (Med),
PhD, Dipl. ECVIM

IMAGING PERFORMED BY

Shari Reffi, CVT

HOSPITAL NAME

Smithfield AH

REFERRING VET

Dr. Hull

INVOICE

71265

DATE

2/5/26

Gallbladder

The gallbladder is small containing normal anechoic bile. Normal thickness and echogenic appearance of the wall. Normal size and appearance of the cystic and common bile duct.

Gastrointestinal

Normal appearance of the stomach, duodenum, small intestine, ileo-cecal junction, and colon with no loss of layering, 1:3 muscularis to mucosa ratio, normal wall thickness and peristaltic activity, and no distension of the lumen.

Pancreas

The visible sections of the pancreas are of normal size and echogenic appearance with a regular capsule. Normal echogenic appearance of the mesentery and fat surrounding the pancreas.

Free Abdomen

Normal mesenteric lymph nodes.

No ascites evident.

Perirectal Area

A perineal hernia is evident.

ULTRASONOGRAPHIC FINDINGS

- Prostatomegaly.
- Left testicular nodule.
- Perineal hernia.

INTERPRETATION OF THE FINDINGS & FURTHER RECOMMENDATIONS

The most likely etiology for the prostatomegaly would be age related benign, prostatic hyperplasia.

Etiologies for the left testicular nodule would be granuloma and emerging neoplasia.

Ideal management would be surgical correction of the perineal hernia and castration.



PATIENT

Jasper Hernandez

SPECIES

Canine

BREED

Maltipoo

SEX

Intact male

AGE

13 years

WEIGHT

15.3 lbs

INTERPRETED BY

Remo Lobetti, BVSc,
MMedVet (Med),
PhD, Dipl. ECVIM

IMAGING PERFORMED BY

Shari Reffi, CVT

HOSPITAL NAME

Smithfield AH

REFERRING VET

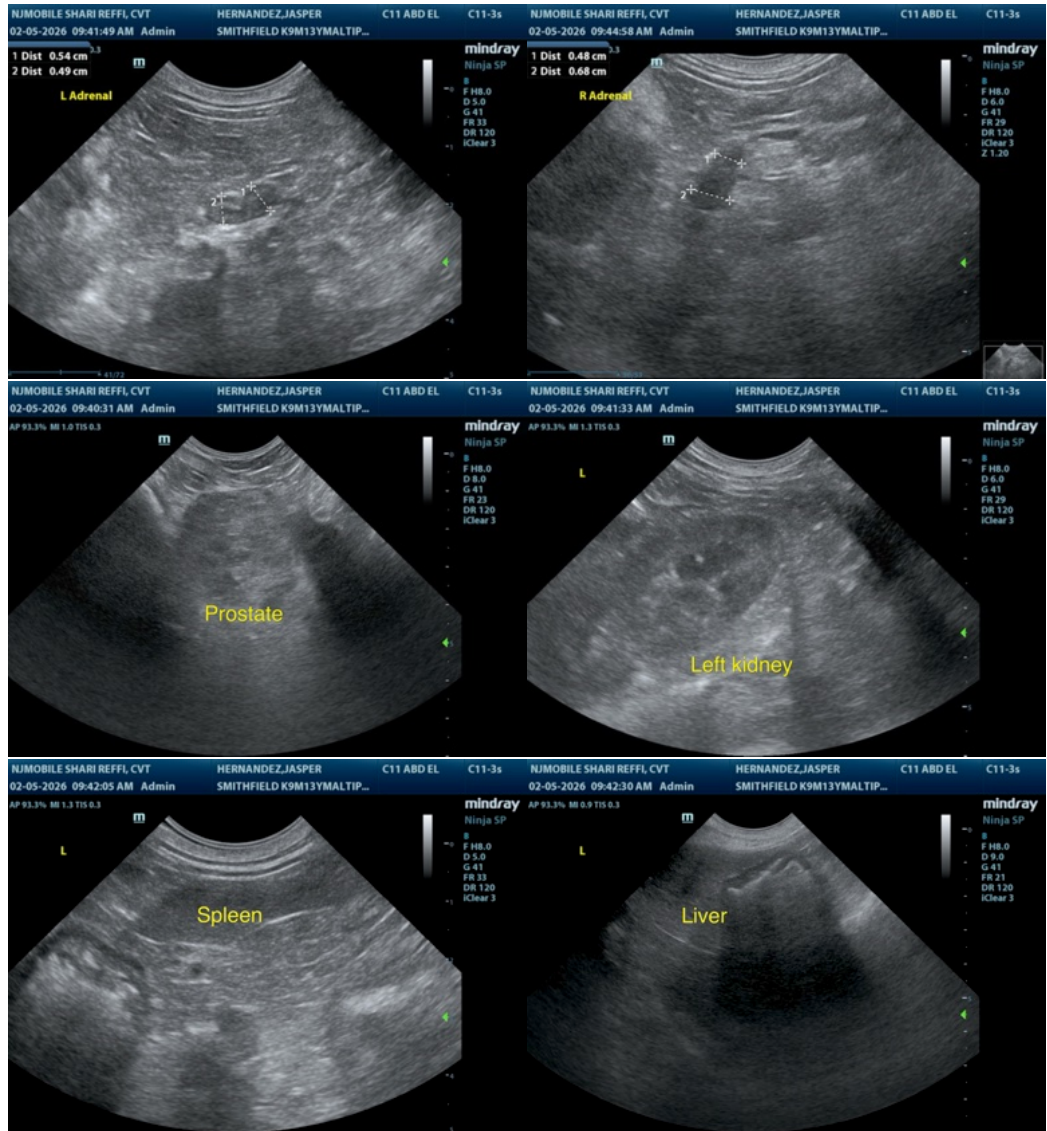
Dr. Hull

INVOICE

71265

DATE

2/5/26





PATIENT

Jasper Hernandez

SPECIES

Canine

BREED

Maltipoo

SEX

Intact male

AGE

13 years

WEIGHT

15.3 lbs

INTERPRETED BY

Remo Lobetti, BVSc,
MMedVet (Med),
PhD, Dipl. ECVIM

IMAGING PERFORMED BY

Shari Reffi, CVT

HOSPITAL NAME

Smithfield AH

REFERRING VET

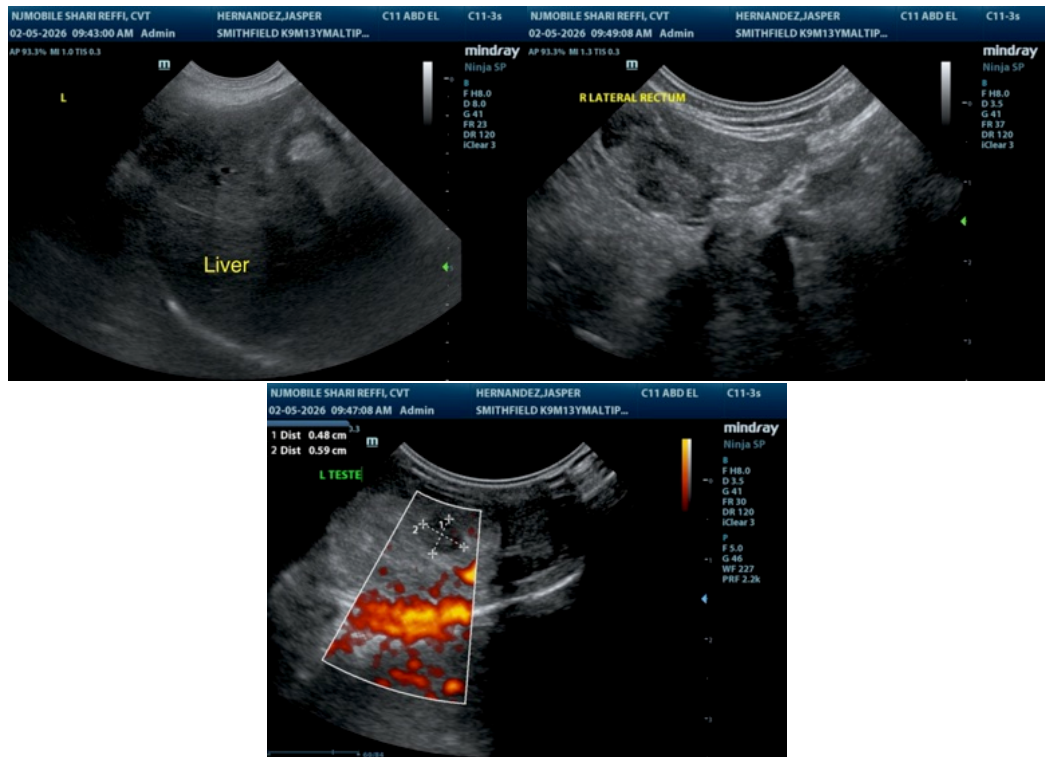Dr. Hull

INVOICE

71265

DATE

2/5/26



The information and recommendations provided are based on the images presented by the referring veterinarian/sonographer. No evaluation can be communicated regarding pathology that was not visible in the image/video clips provided.

Thank you for this referral. If the clinical or image interpretation does not parallel your findings or if I can be of any further assistance please contact me.

Remo Lobetti, BVSc, MMedVet (Med), PhD, Dipl. ECVIM (Internal Medicine)

info@sonopath.com