



PATIENT

Bentley Homlish

SPECIES

Feline

BREED

Persian

SEX

Neutered male

AGE

6 years

WEIGHT

7 lbs

INTERPRETED BY

Remo Lobetti, BVSc,
MMedVet (Med),
PhD, Dipl. ECVIM
(Internal Medicine)

IMAGING PERFORMED BY

Kerri Becker

HOSPITAL NAME

Whippany VH

REFERRING VET

Dr. Cordero

INVOICE

71277

DATE

2/5/26

PRESENTING CLINICAL SIGNS

Chronic vomiting and wt loss. Generalize muscle loss.

ULTRASONOGRAPHIC EXAMINATION OF THE ABDOMEN

Urinary System

The urinary bladder is full with a normal thickness and smooth appearance of the wall. A small amount of amount non-adhered, hyperechogenic sediment is noted.

Normal appearance of the trigone area, proximal urethra, and iliac blood vessels.

Normal appearance and size of the iliac lymph nodes. Ureters not visualized, which can be considered a normal finding.

Normal renal size (left measured 3.2 cm, right measured 3.7 cm), architecture, echogenic appearance, cortico-medullary differentiation, which maintains a 1:3 cortex to medulla ratio, pelvis, and capsule. No infarcts, mineralization or renoliths evident. Normal color flow pattern is evident in both kidneys.

Adrenal Glands

Normal shape, echogenic appearance, size, position, and appearance of the visible peri-adrenal vasculature. Left adrenal gland measured 0.23 cm in width. The right adrenal gland measured 0.32 cm in width.

Spleen

Normal size and echogenic appearance. Smooth homogenous parenchyma and regular curvilinear capsule. Normal volume of the splenic vasculature without any overt congestion or thrombosis evident. No inflammatory, neoplastic, infarction, or infiltrative changes evident. The spleen measured 0.8 cm in width.

Liver

Normal size, echogenic appearance, portal markings, and regular curvilinear capsule. No nodules or masses evident. Normal appearance of the hepatic and portal vasculature.

Gallbladder

The gallbladder is full containing normal anechoic bile. Normal thickness and echogenic appearance of the wall. Normal size and appearance of the cystic and common bile duct.



PATIENT

Bentley Homlish

SPECIES

Feline

BREED

Persian

SEX

Neutered male

AGE

6 years

WEIGHT

7 lbs

INTERPRETED BY

Remo Lobetti, BVSc,
MMedVet (Med),
PhD, Dipl. ECVIM
(Internal Medicine)

IMAGING PERFORMED BY

Kerri Becker

HOSPITAL NAME

Whippany VH

REFERRING VET

Dr. Cordero

INVOICE

71277

DATE

2/5/26

Gastrointestinal

Normal appearance of the stomach, duodenum, small intestine, ileo-cecal junction, and colon with no loss of layering, 1:3 muscularis to mucosa ratio, normal wall thickness and peristaltic activity, and no distension of the lumen.

Pancreas

The visible sections of the pancreas are of normal size and echogenic appearance with a regular capsule. Normal echogenic appearance of the mesentery and fat surrounding the pancreas.

Free Abdomen

Normal mesenteric lymph nodes.

No ascites evident.

ULTRASONOGRAPHIC FINDINGS

- Urinary bladder sediment

INTERPRETATION OF THE FINDINGS & FURTHER RECOMMENDATIONS

The most likely etiology for the urinary bladder sediment would be incidental debris, crystalluria and possibly bacterial cystitis.

On this ultrasound there is no obvious etiology for the presenting clinical signs.

Although the GI tract appears ultrasonographically normal, with the presenting clinical signs an underlying gastroenteropathy such as chronic gastritis, Helicobacter gastritis, ulcerative disease, parasitic gastroenteritis, inflammatory bowel disease and dietary hypersensitivity should still be considered.

Further assessment would be urine and fecal analysis, possibly urine culture, cobalamin and folate assay and endoscopy of the upper GI tract with biopsies.

Specific therapy would be dependent on an etiological diagnosis.

Symptomatic management that can be considered would be feeding small frequent meals of a novel protein/hypoallergenic diet, course of Fenbendazole, cobalamin supplementation. If there is not a satisfactory improvement then triple therapy for Helicobacter gastritis is recommended and if there is still not a satisfactory improvement then a course of Prednisolone would then be indicated.



PATIENT

Bentley Homlish

SPECIES

Feline

BREED

Persian

SEX

Neutered male

AGE

6 years

WEIGHT

7 lbs

INTERPRETED BY

Remo Lobetti, BVSc,
 MMedVet (Med),
 PhD, Dipl. ECVIM
 (Internal Medicine)

IMAGING PERFORMED BY

Kerri Becker

HOSPITAL NAME

Whippany VH

REFERRING VET

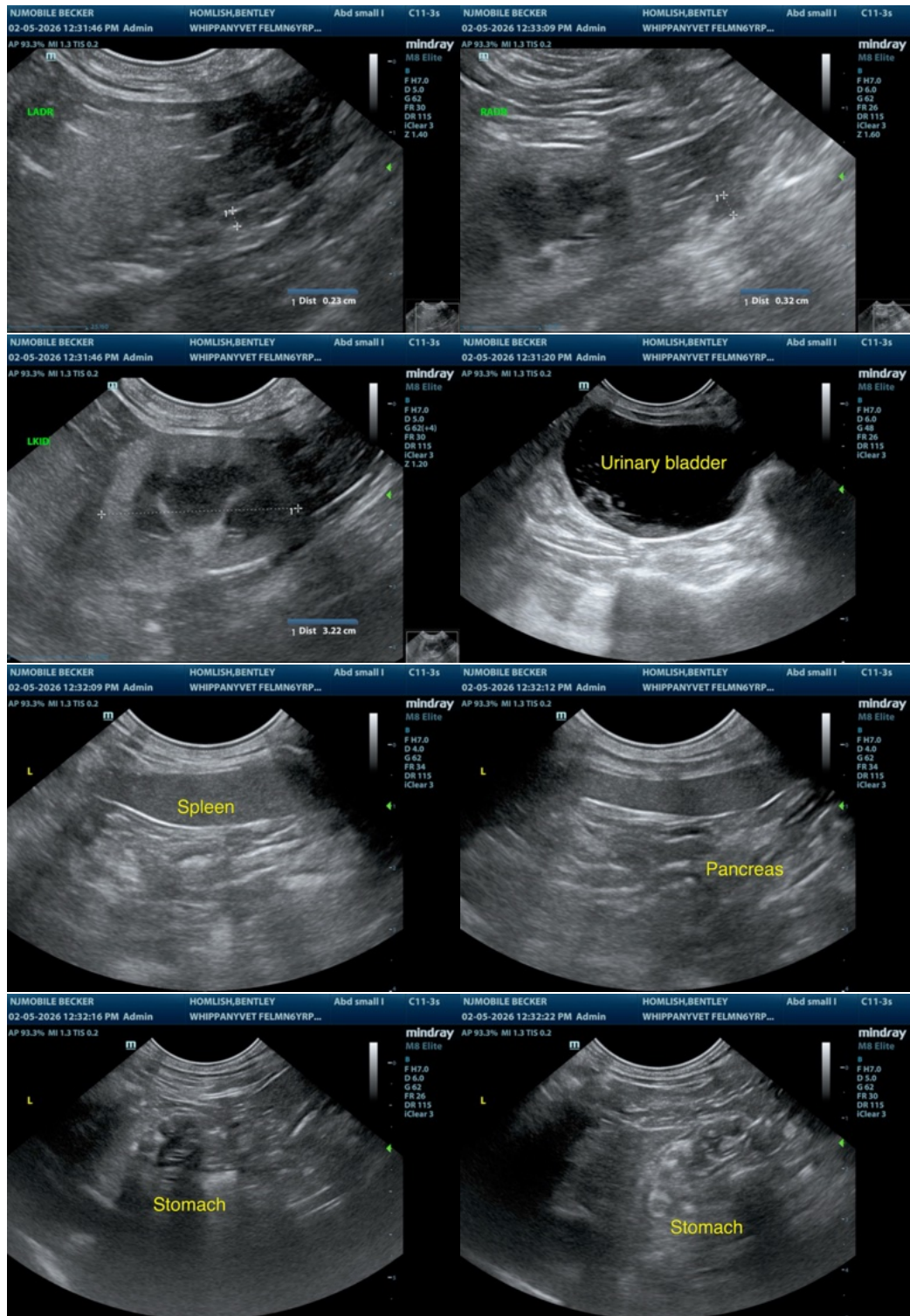
Dr. Cordero

INVOICE

71277

DATE

2/5/26





PATIENT

Bentley Homlish

SPECIES

Feline

BREED

Persian

SEX

Neutered male

AGE

6 years

WEIGHT

7 lbs

INTERPRETED BY

Remo Lobetti, BVSc,
 MMedVet (Med),
 PhD, Dipl. ECVIM
 (Internal Medicine)

IMAGING PERFORMED BY

Kerri Becker

HOSPITAL NAME

Whippany VH

REFERRING VET

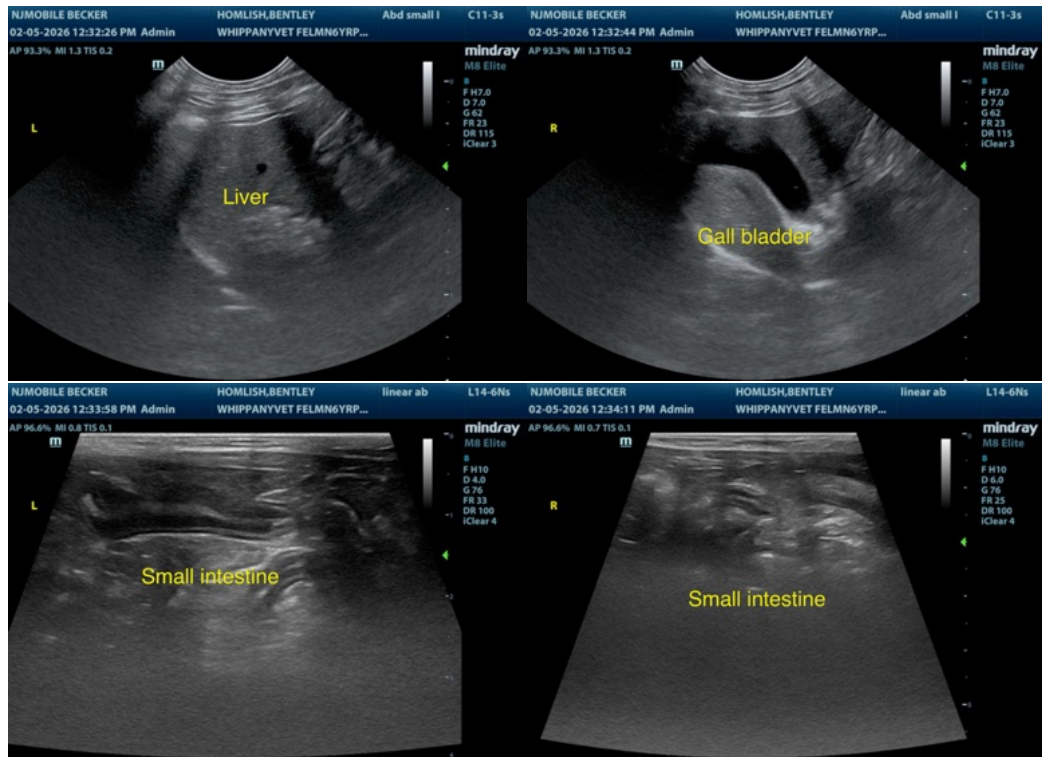
Dr. Cordero

INVOICE

71277

DATE

2/5/26



The information and recommendations provided are based on the images presented by the referring veterinarian/sonographer. No evaluation can be communicated regarding pathology that was not visible in the image/video clips provided.

Thank you for this referral. If the clinical or image interpretation does not parallel your findings or if I can be of any further assistance please contact me.

Remo Lobetti, BVSc, MMedVet (Med), PhD, Dipl. ECVIM (Internal Medicine)

info@sonopath.com