



PATIENT

Luna Panobianco

SPECIES

Feline

BREED

Domestic Shorthair

SEX

Spayed female

AGE

5 years

WEIGHT

10 lbs

INTERPRETED BY

Remo Lobetti, BVSc,
MMedVet (Med),
PhD, Dipl. ECVIM

IMAGING PERFORMED BY

Vincent Ravancho, CVT

HOSPITAL NAME

Englewood Cliffs
Veterinary

REFERRING VET

Dr. Attanasi

INVOICE

71219

DATE

2/4/26

PRESENTING CLINICAL SIGNS

- Int V+; Pain when defecating and sometimes outside the box
- Clinical Findings: Bilateral Hip Dysplasia
- Current Medications: HP Diet
- Sedated with Dex, Ket, Torb

ULTRASONOGRAPHIC EXAMINATION OF THE ABDOMEN

Urinary System

The urinary bladder is full with a normal thickness and smooth appearance of the wall. Normal anechoic urine with no sediment or uroliths evident.

Normal appearance of the trigone area, proximal urethra, and iliac blood vessels.

Normal appearance and size of the iliac lymph nodes. Ureters not visualized, which can be considered a normal finding.

Normal renal size (left measured 3.4 cm, right measured 3.8 cm), architecture, echogenic appearance, cortico-medullary differentiation, which maintains a 1:3 cortex to medulla ratio, pelvis, and capsule. No infarcts, mineralization or renoliths evident.

Adrenal Glands

Normal shape, echogenic appearance, size, position, and appearance of the visible peri-adrenal vasculature. Left adrenal gland measured 0.4 cm in width. The right adrenal gland measured 0.4 cm in width.

Spleen

Normal size and echogenic appearance. Smooth homogenous parenchyma and regular curvilinear capsule. Normal volume of the splenic vasculature without any overt congestion or thrombosis evident. No inflammatory, neoplastic, infarction, or infiltrative changes evident. The spleen measured 1.0 cm in width.

Liver

Normal size, echogenic appearance, portal markings, and regular curvilinear capsule. No nodules or masses evident. Normal appearance of the hepatic and portal vasculature.

Gallbladder

The gallbladder is full containing normal anechoic bile. Normal thickness and echogenic appearance of the wall. Normal size and appearance of the cystic and common bile duct.



PATIENT

Luna Panobianco

SPECIES

Feline

BREED

Domestic Shorthair

SEX

Spayed female

AGE

5 years

WEIGHT

10 lbs

INTERPRETED BY

Remo Lobetti, BVSc,
MMedVet (Med),
PhD, Dipl. ECVIM

IMAGING PERFORMED BY

Vincent Ravancho, CVT

HOSPITAL NAME

Englewood Cliffs
Veterinary

REFERRING VET

Dr. Attanasi

INVOICE

71219

DATE

2/4/26

Gastrointestinal

Normal appearance of the stomach, duodenum, small intestine, ileo-cecal junction, and colon with no loss of layering, 1:3 muscularis to mucosa ratio, normal wall thickness and peristaltic activity, and no distension of the lumen. A small amount of fluid was present in the stomach. Fecal material was present in the colon.

Pancreas

The visible sections of the pancreas are of normal size and echogenic appearance with a regular capsule. Normal echogenic appearance of the mesentery and fat surrounding the pancreas.

Free Abdomen

Normal mesenteric lymph nodes.

No ascites evident.

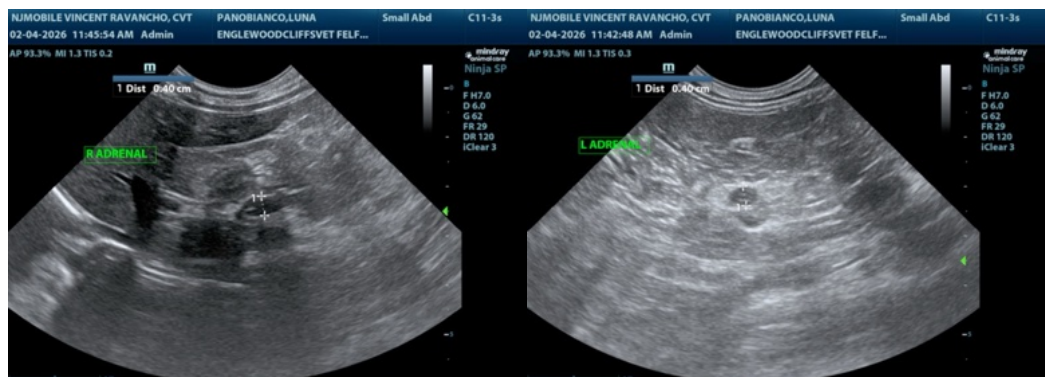
ULTRASONOGRAPHIC FINDINGS

- Normal ultrasound examination of the abdomen.

INTERPRETATION OF THE FINDINGS & FURTHER RECOMMENDATIONS

On this ultrasound there is no obvious etiology for the presenting clinical signs.

An important etiology to consider for the presenting clinical signs would be the bilateral hip dysplasia.





PATIENT

Luna Panobianco

SPECIES

Feline

BREED

Domestic Shorthair

SEX

Spayed female

AGE

5 years

WEIGHT

10 lbs

INTERPRETED BY

Remo Lobetti, BVSc,
MMedVet (Med),
PhD, Dipl. ECVIM

**IMAGING
PERFORMED BY**

Vincent Ravancho, CVT

HOSPITAL NAME

Englewood Cliffs
Veterinary

REFERRING VET

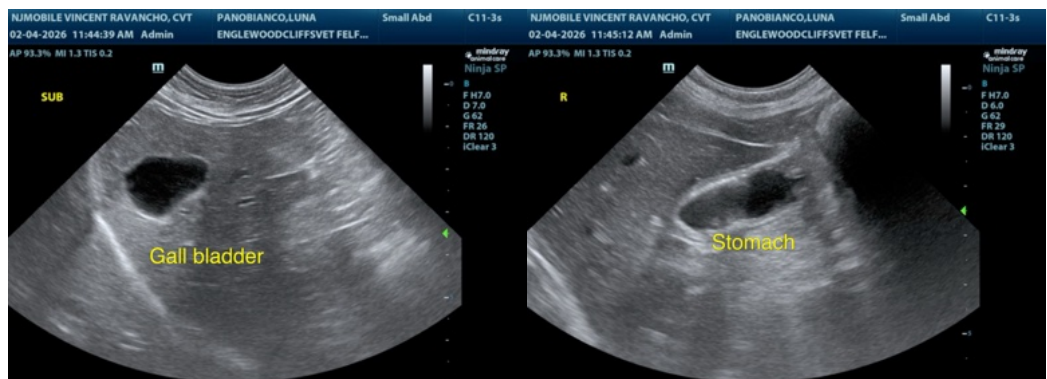
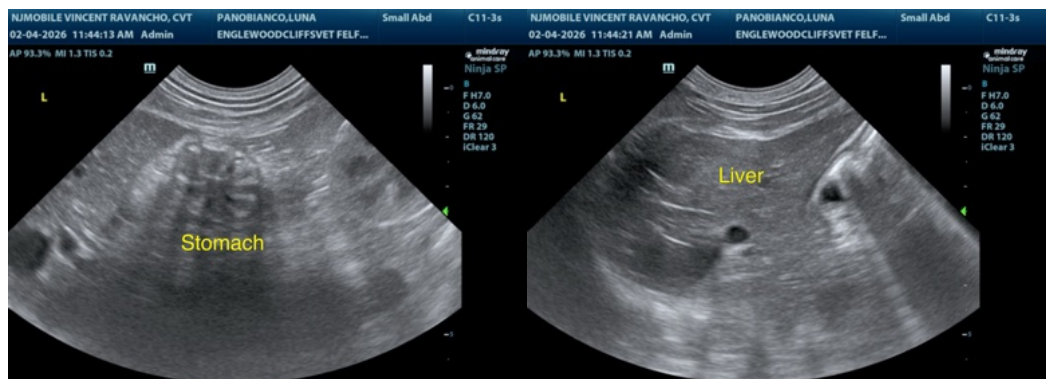
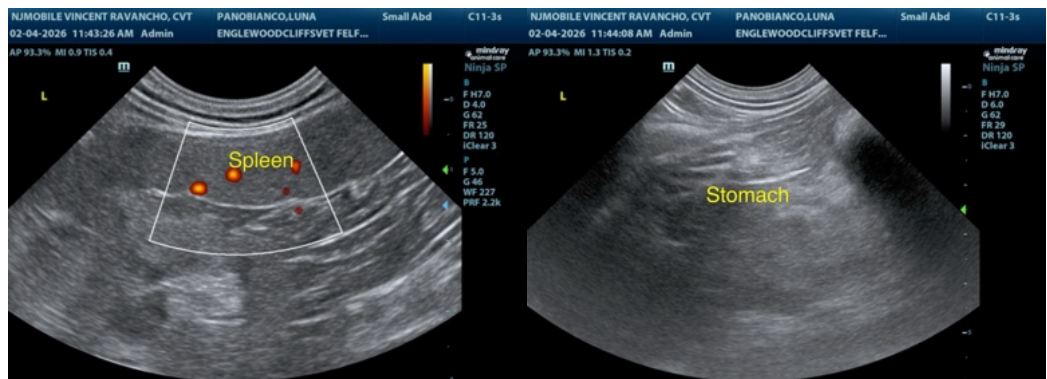
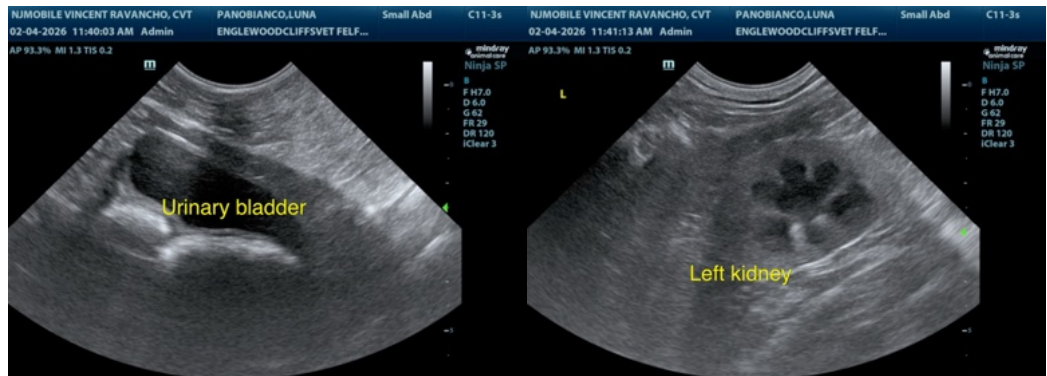
Dr. Attanasi

INVOICE

71219

DATE

2/4/26





PATIENT

Luna Panobianco

SPECIES

Feline

BREED

Domestic Shorthair

SEX

Spayed female

AGE

5 years

WEIGHT

10 lbs

INTERPRETED BY

Remo Lobetti, BVSc,
MMedVet (Med),
PhD, Dipl. ECVIM

IMAGING PERFORMED BY

Vincent Ravancho, CVT

HOSPITAL NAME

Englewood Cliffs
Veterinary

REFERRING VET

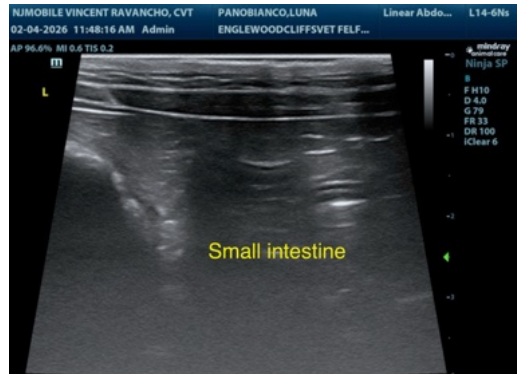Dr. Attanasi

INVOICE

71219

DATE

2/4/26



The information and recommendations provided are based on the images presented by the referring veterinarian/sonographer. No evaluation can be communicated regarding pathology that was not visible in the image/video clips provided.

Thank you for this referral. If the clinical or image interpretation does not parallel your findings or if I can be of any further assistance please contact me.

Remo Lobetti, BVSc, MMedVet (Med), PhD, Dipl. ECVIM (Internal Medicine)

info@sonopath.com