



PATIENT

Yofi Wechter

SPECIES

Canine

BREED

Bichon Frise

SEX

Spayed female

AGE

11 ½ years

WEIGHT

4.5 kgs

INTERPRETED BY

Remo Lobetti, BVSc,
MMedVet (Med),
PhD, Dipl. ECVIM

IMAGING PERFORMED BY

Vincent Ravancho, CVT

HOSPITAL NAME

Bond Vet Montclair

REFERRING VET

Dr. Sposato

INVOICE

71190

DATE

2/3/26

PRESENTING CLINICAL SIGNS

- Hyporexia, Weight Loss
- 11/25/25 - was 5 kgs
- 1/22/26 - CBC/Chem/CPL - all NSF

ULTRASONOGRAPHIC EXAMINATION OF THE ABDOMEN

Urinary System

The urinary bladder is full with a normal thickness and smooth appearance of the wall. A small urolith was noted and measured 0.7 cm in size.

Normal appearance of the trigone area, proximal urethra, and iliac blood vessels.

Normal appearance and size of the iliac lymph nodes. Ureters not visualized, which can be considered a normal finding.

Normal renal size (left measured 3.6 cm, right measured 3.3 cm), architecture, echogenic appearance, cortico-medullary differentiation, which maintains a 1:3 cortex to medulla ratio, pelvis, and capsule. No infarcts, mineralization or renoliths evident. Normal color flow pattern is evident in both kidneys.

Adrenal Glands

The adrenal glands are small in size, but maintained normal shape, echogenic appearance, position, and appearance of the visible peri-adrenal vasculature. Left adrenal gland measured 0.84 cm in length x 0.32 cm and 0.27 cm in width. The right adrenal gland measured 1.1 cm in length x 0.34 cm in width.

Spleen

Normal size and echogenic appearance. Smooth homogenous parenchyma and regular curvilinear capsule. Normal volume of the splenic vasculature without any overt congestion or thrombosis evident. Incidental myelolipoma is present. No inflammatory, neoplastic, infarction, or infiltrative changes evident. The spleen measured 1.4 cm in width.

Liver

Normal size, echogenic appearance, portal markings, and regular curvilinear capsule. No nodules or masses evident. Normal appearance of the hepatic and portal vasculature.

Gallbladder

The gallbladder is full containing normal anechoic bile. Normal thickness and echogenic appearance of the wall. Normal size and appearance of the cystic and common bile duct.



PATIENT

Yofi Wechter

SPECIES

Canine

BREED

Bichon Frise

SEX

Spayed female

AGE

11 ½ years

WEIGHT

4.5 kgs

INTERPRETED BY

Remo Lobetti, BVSc,
MMedVet (Med),
PhD, Dipl. ECVIM

IMAGING PERFORMED BY

Vincent Ravancho, CVT

HOSPITAL NAME

Bond Vet Montclair

REFERRING VET

Dr. Sposato

INVOICE

71190

DATE

2/3/26

Gastrointestinal

Normal appearance of the stomach, duodenum, small intestine, ileo-cecal junction, and colon with no loss of layering, 1:3 muscularis to mucosa ratio, normal wall thickness and peristaltic activity, and no distension of the lumen.

Pancreas

The visible sections of the pancreas are of normal size and echogenic appearance with a regular capsule. Normal echogenic appearance of the mesentery and fat surrounding the pancreas.

Free Abdomen

Normal mesenteric lymph nodes.

No ascites evident.

ULTRASONOGRAPHIC FINDINGS

- Small adrenal glands.
- Urolith.

INTERPRETATION OF THE FINDINGS & FURTHER RECOMMENDATIONS

Although the small adrenal glands may merely be a reflection of the patient's size, with the presenting clinical signs atypical Addison's disease should still be considered.

The urolith can be considered an incidental finding.

Although the GI tract appears ultrasonographically normal, with the presenting clinical signs, an underlying enteropathy such as parasitic enteritis, dietary hypersensitivity and inflammatory bowel disease should still be considered.

Further assessment would be fecal analysis, cobalamin, folate and basal cortisol assay and endoscopy of the upper GI tract with biopsies.

Specific therapy would be dependent on an etiological diagnosis.



PATIENT

Yofi Wechter

SPECIES

Canine

BREED

Bichon Frise

SEX

Spayed female

AGE

11 ½ years

WEIGHT

4.5 kgs

INTERPRETED BY

Remo Lobetti, BVSc,
MMedVet (Med),
PhD, Dipl. ECVIM

**IMAGING
PERFORMED BY**

Vincent Ravancho, CVT

HOSPITAL NAME

Bond Vet Montclair

REFERRING VET

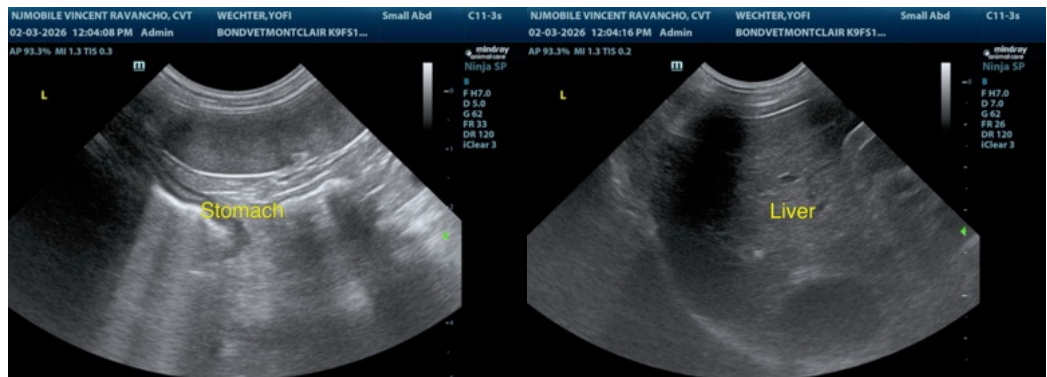
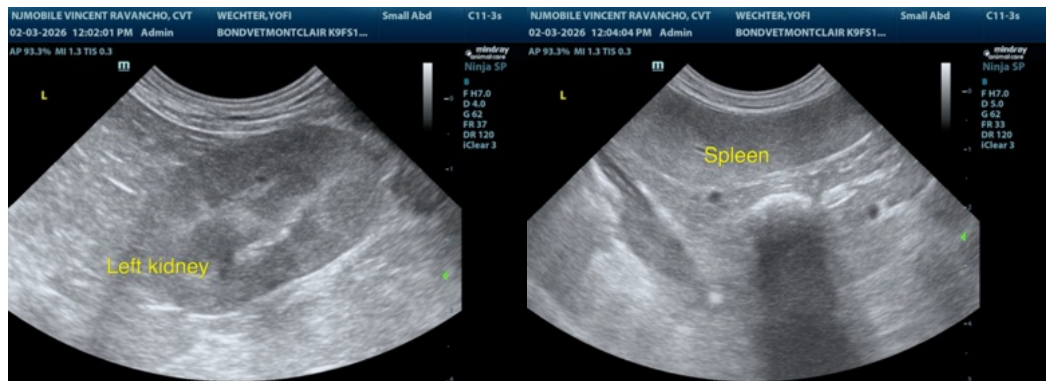
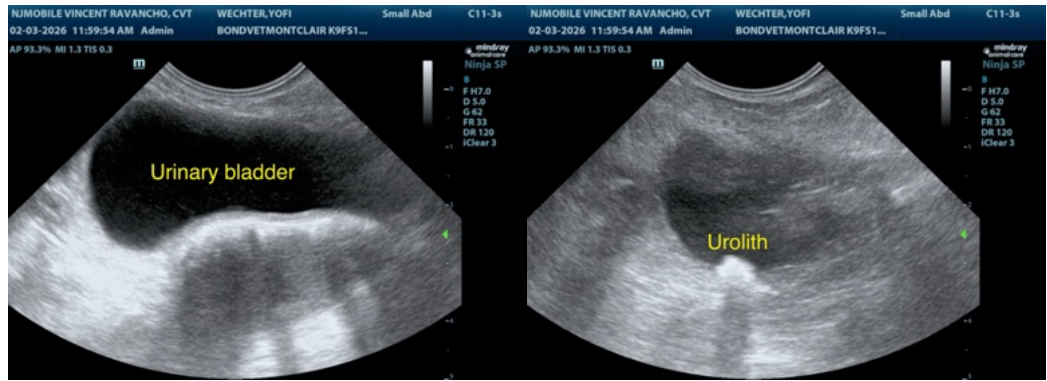
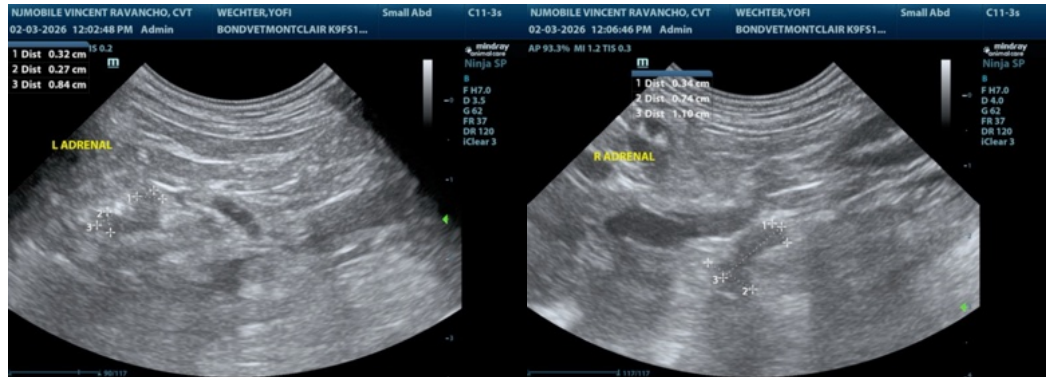
Dr. Sposato

INVOICE

71190

DATE

2/3/26





PATIENT

Yofi Wechter

SPECIES

Canine

BREED

Bichon Frise

SEX

Spayed female

AGE

11 ½ years

WEIGHT

4.5 kgs

INTERPRETED BY

Remo Lobetti, BVSc,
MMedVet (Med),
PhD, Dipl. ECVIM

IMAGING PERFORMED BY

Vincent Ravancho, CVT

HOSPITAL NAME

Bond Vet Montclair

REFERRING VET

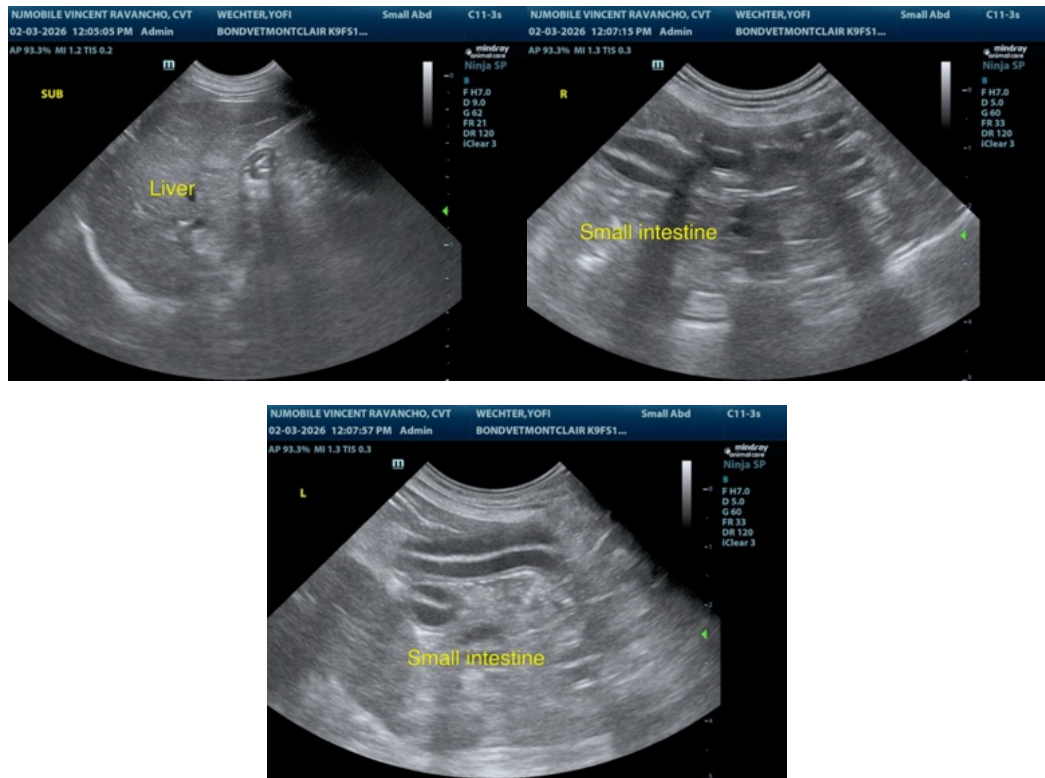
Dr. Sposato

INVOICE

71190

DATE

2/3/26



The information and recommendations provided are based on the images presented by the referring veterinarian/sonographer. No evaluation can be communicated regarding pathology that was not visible in the image/video clips provided.

Thank you for this referral. If the clinical or image interpretation does not parallel your findings or if I can be of any further assistance please contact me.

Remo Lobetti, BVSc, MMedVet (Med), PhD, Dipl. ECVIM (Internal Medicine)

info@sonopath.com