



PATIENT

Magic Janiec

SPECIES

Feline

BREED

Domestic Shorthair

SEX

Neutered male

AGE

10 years

WEIGHT

11.6 lbs

INTERPRETED BY

Remo Lobetti, BVSc,
MMedVet (Med),
PhD, Dipl. ECVIM

IMAGING PERFORMED BY

Vincent Ravancho, CVT

HOSPITAL NAME

Ringwood AH

REFERRING VET

Dr. Wilkes

INVOICE

71189

DATE

2/3/26

PRESENTING CLINICAL SIGNS

- Chronic Diarrhea, 4/9 BCS. Weight loss since diarrhea started in September, otherwise normal exam
- Current medication: Forti Flora
- All labwork WNL

ULTRASONOGRAPHIC EXAMINATION OF THE ABDOMEN

Urinary System

The urinary bladder is full with a normal thickness and smooth appearance of the wall. A large amount of floating, hyperechogenic sediment.

Normal appearance of the trigone area, proximal urethra, and iliac blood vessels.

Normal appearance and size of the iliac lymph nodes. Ureters not visualized, which can be considered a normal finding.

Normal renal size (left measured 4.3 cm, right measured 3.8 cm), architecture, echogenic appearance, cortico-medullary differentiation, which maintains a 1:3 cortex to medulla ratio, pelvis, and capsule. No infarcts, mineralization or renoliths evident. Normal color flow pattern is evident in both kidneys.

Adrenal Glands

Normal shape, echogenic appearance, size, position, and appearance of the visible peri-adrenal vasculature. Left adrenal gland measured 0.32 cm in width. The right adrenal gland measured 0.39 cm in width.

Spleen

Normal size and echogenic appearance. Smooth homogenous parenchyma and regular curvilinear capsule. Normal volume of the splenic vasculature without any overt congestion or thrombosis evident. No inflammatory, neoplastic, infarction, or infiltrative changes evident. The spleen measured 0.9 cm in width.

Liver

Normal size, echogenic appearance, portal markings, and regular curvilinear capsule. No nodules or masses evident. Normal appearance of the hepatic and portal vasculature.

Gallbladder

The gallbladder is small containing normal anechoic bile. Normal thickness and echogenic appearance of the wall. Normal size and appearance of the cystic and common bile duct.



PATIENT

Magic Janiec

SPECIES

Feline

BREED

Domestic Shorthair

SEX

Neutered male

AGE

10 years

WEIGHT

11.6 lbs

INTERPRETED BY

Remo Lobetti, BVSc,
MMedVet (Med),
PhD, Dipl. ECVIM

IMAGING PERFORMED BY

Vincent Ravancho, CVT

HOSPITAL NAME

Ringwood AH

REFERRING VET

Dr. Wilkes

INVOICE

71189

DATE

2/3/26

Gastrointestinal

Normal appearance of the stomach, duodenum, ileo-cecal junction, and colon with no loss of layering, 1:3 muscularis to mucosa ratio, normal wall thickness and peristaltic activity, and no distension of the lumen. Normal thickness of the small intestine (up to 0.2 cm) with no loss of layering, but with a segmental increase in the muscularis to mucosa ratio. Normal peristaltic activity and no distension of the lumen was noted in the small intestines.

Pancreas

The visible sections of the pancreas are of normal size and echogenic appearance with a regular capsule. Normal echogenic appearance of the mesentery and fat surrounding the pancreas.

Free Abdomen

Normal mesenteric lymph nodes.

No ascites evident.

ULTRASONOGRAPHIC FINDINGS

- Enteropathy.
- Urinary bladder sediment.

INTERPRETATION OF THE FINDINGS & FURTHER RECOMMENDATIONS

Etiologies for the enteropathy would be parasitic enteritis, dietary hypersensitivity and inflammatory bowel disease with emerging lymphoma a less likely differential diagnosis.

Etiologies for the urinary bladder sediment would be incidental debris, crystalluria and possibly bacterial cystitis.

Further assessment would be urine and fecal analysis, possibly urine culture, cobalamin and folate assay and endoscopy of the upper GI tract with biopsies.

Specific therapy would be dependent on an etiological diagnosis. Symptomatic management that can be considered would be feeding a novel protein/hypoallergenic diet, course of Fenbendazole, cobalamin supplementation and if there is still not a satisfactory improvement then a course of Prednisolone would then be indicated.



PATIENT

Magic Janiec

SPECIES

Feline

BREED

Domestic Shorthair

SEX

Neutered male

AGE

10 years

WEIGHT

11.6 lbs

INTERPRETED BY

Remo Lobetti, BVSc,
MMedVet (Med),
PhD, Dipl. ECVIM

IMAGING PERFORMED BY

Vincent Ravancho, CVT

HOSPITAL NAME

Ringwood AH

REFERRING VET

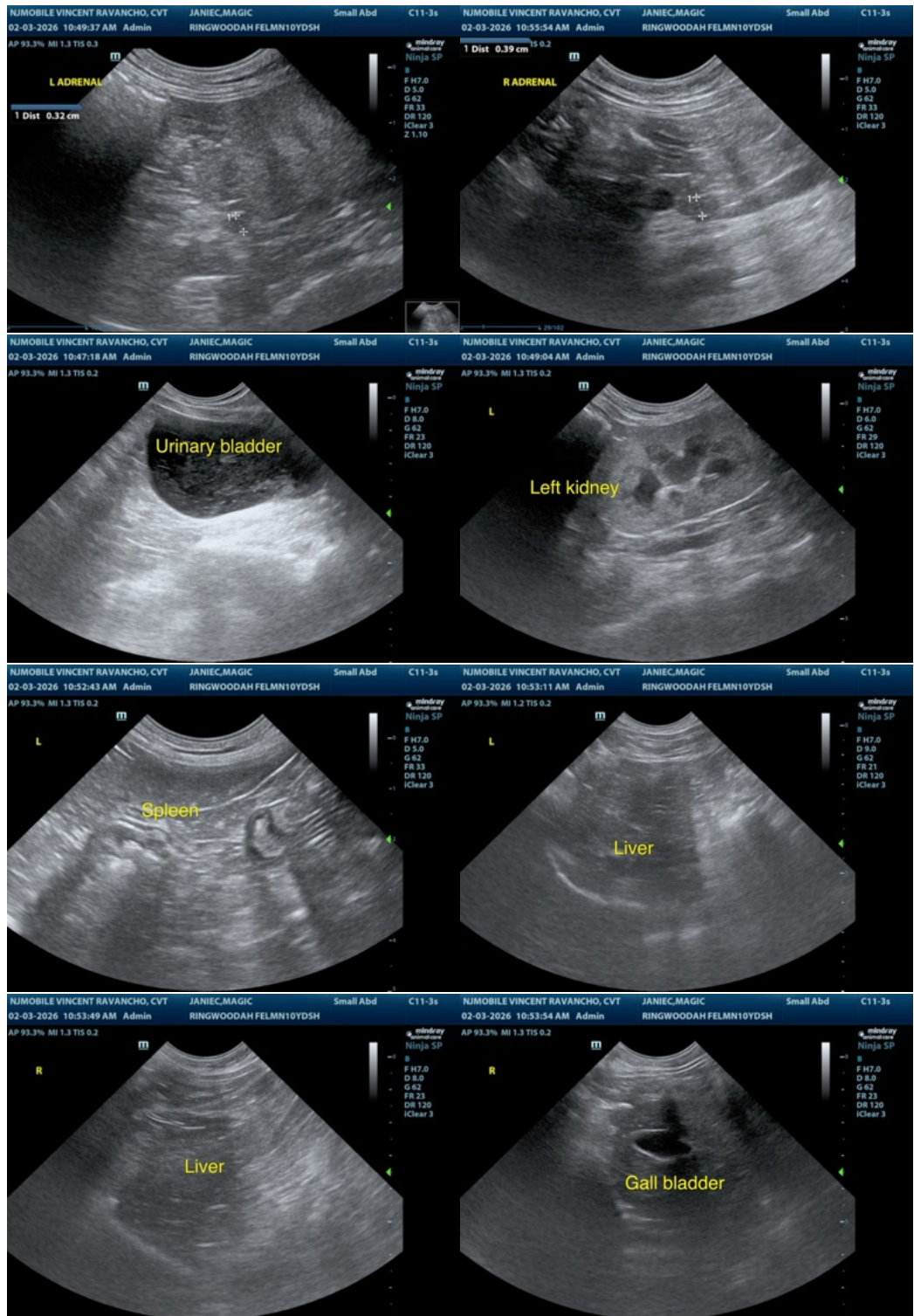
Dr. Wilkes

INVOICE

71189

DATE

2/3/26





PATIENT

Magic Janiec

SPECIES

Feline

BREED

Domestic Shorthair

SEX

Neutered male

AGE

10 years

WEIGHT

11.6 lbs

INTERPRETED BY

Remo Lobetti, BVSc,
MMedVet (Med),
PhD, Dipl. ECVIM

IMAGING PERFORMED BY

Vincent Ravancho, CVT

HOSPITAL NAME

Ringwood AH

REFERRING VET

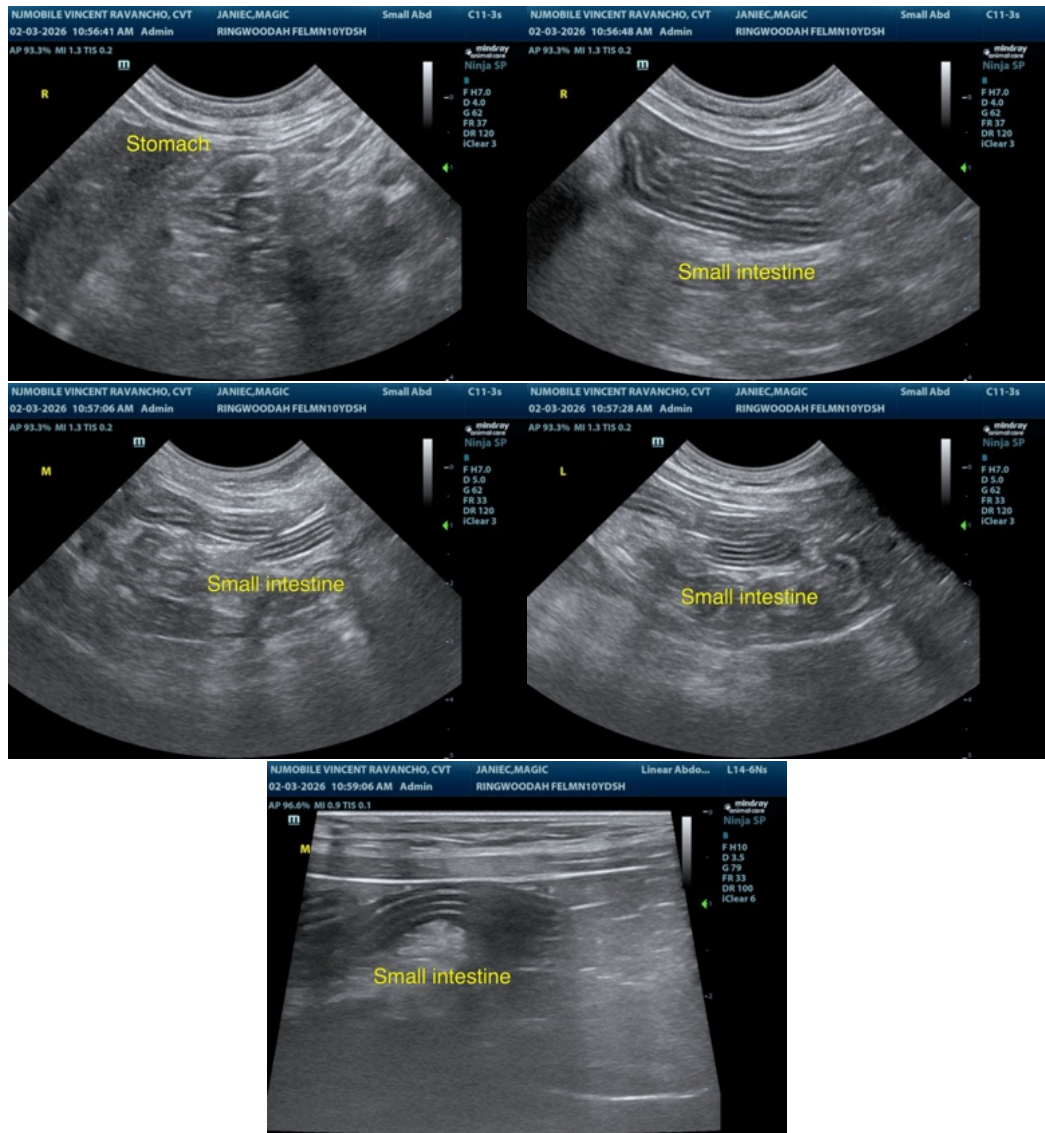
Dr. Wilkes

INVOICE

71189

DATE

2/3/26



The information and recommendations provided are based on the images presented by the referring veterinarian/sonographer. No evaluation can be communicated regarding pathology that was not visible in the image/video clips provided.

Thank you for this referral. If the clinical or image interpretation does not parallel your findings or if I can be of any further assistance please contact me.

Remo Lobetti, BVSc, MMedVet (Med), PhD, Dipl. ECVIM (Internal Medicine)

info@sonopath.com