



PATIENT

Dusty Day

SPECIES

Canine

BREED

Mix

SEX

Neutered male

AGE

10 years

WEIGHT

74.5 lbs

INTERPRETED BY

Remo Lobetti, BVSc,
MMedVet (Med),
PhD, Dipl. ECVIM

IMAGING PERFORMED BY

Meghan Morse, LVT,
CVT

HOSPITAL NAME

Hamburg VC

REFERRING VET

Dr. Branning

INVOICE

71947

DATE

2/26/26

PRESENTING CLINICAL SIGNS

- PU/PD, panting excessively, hx of tremors, coughing
- Current meds: Doxycycline/ Hycodan, Gaba/Traz for AUS
- Abnormal PE/Chem/CBC/UA Results: ALP 688

ULTRASONOGRAPHIC EXAMINATION OF THE ABDOMEN

Urinary System

The urinary bladder is small with a normal thickness and smooth appearance of the wall. Normal anechoic urine with no sediment or uroliths evident.

Normal appearance of the trigone area, proximal urethra, and iliac blood vessels.

Normal appearance and size of the iliac lymph nodes. Ureters not visualized, which can be considered a normal finding.

Normal renal size (left measured 7.2 cm, right measured 6.2 cm), architecture, echogenic appearance, cortico-medullary differentiation, which maintains a 1:3 cortex to medulla ratio, pelvis, and capsule. No infarcts, mineralization or renoliths evident. Normal color flow pattern is evident in both kidneys.

The prostate is small and hypoechogenic.

Adrenal Glands

Normal shape, echogenic appearance, size, position, and appearance of the visible peri-adrenal vasculature. Left adrenal gland measured 2.45 cm in length x 0.63 cm and 0.62 cm in width. The right adrenal gland measured 2.3 cm in length x 0.75 cm in width.

Spleen

Normal size and echogenic appearance. Smooth homogenous parenchyma and regular curvilinear capsule. Normal volume of the splenic vasculature without any overt congestion or thrombosis evident. No inflammatory, neoplastic, infarction, or infiltrative changes evident. The spleen measured 2.9 cm in width.

Liver

Normal size with a diffuse increased echogenic appearance, normal portal markings, and regular curvilinear capsule. No nodules or masses evident. Normal appearance of the hepatic and portal vasculature.



PATIENT

Dusty Day

SPECIES

Canine

BREED

Mix

SEX

Neutered male

AGE

10 years

WEIGHT

74.5 lbs

INTERPRETED BY

Remo Lobetti, BVSc,
MMedVet (Med),
PhD, Dipl. ECVIM

IMAGING PERFORMED BY

Meghan Morse, LVT,
CVT

HOSPITAL NAME

Hamburg VC

REFERRING VET

Dr. Branning

INVOICE

71947

DATE

2/26/26

Gallbladder

The gallbladder is small containing normal anechoic bile. Normal thickness and echogenic appearance of the wall. Normal size and appearance of the cystic and common bile duct.

Gastrointestinal

Normal appearance of the stomach, duodenum, small intestine, ileo-cecal junction, and colon with no loss of layering, 1:3 muscularis to mucosa ratio, normal wall thickness and peristaltic activity, and no distension of the lumen.

Pancreas

The visible sections of the pancreas are of normal size and echogenic appearance with a regular capsule. Normal echogenic appearance of the mesentery and fat surrounding the pancreas.

Free Abdomen

Normal mesenteric lymph nodes.

No ascites evident.

ULTRASONOGRAPHIC FINDINGS

- Hepatopathy.

INTERPRETATION OF THE FINDINGS & FURTHER RECOMMENDATIONS

The likely etiologies for the hepatopathy would be reactive hyperplasia, early nodular hyperplasia, vacuolar and metabolic with hepatitis and infiltrative neoplasia an unlikely differential diagnosis.

Although the adrenal glands appear ultrasonographically normal, with the presenting clinical signs and the elevated ALP activity, pituitary dependent Cushing's disease should still be considered.

Further assessment would be urine specific gravity and urine cortisol to creatinine ratio and if abnormal then adrenal function testing (ACTH stimulation/LDDST) would then be indicated.

If Cushing's disease has been excluded then further assessment would be survey thoracic radiographs and FNA cytology of the liver.

A tru cut or wedge biopsy of the liver may be required for a final etiological diagnosis.

Specific therapy would be dependent on an etiological diagnosis.



PATIENT

Dusty Day

SPECIES

Canine

BREED

Mix

SEX

Neutered male

AGE

10 years

WEIGHT

74.5 lbs

INTERPRETED BY

Remo Lobetti, BVSc,
 MMedVet (Med),
 PhD, Dipl. ECVIM

IMAGING PERFORMED BY

Meghan Morse, LVT,
 CVT

HOSPITAL NAME

Hamburg VC

REFERRING VET

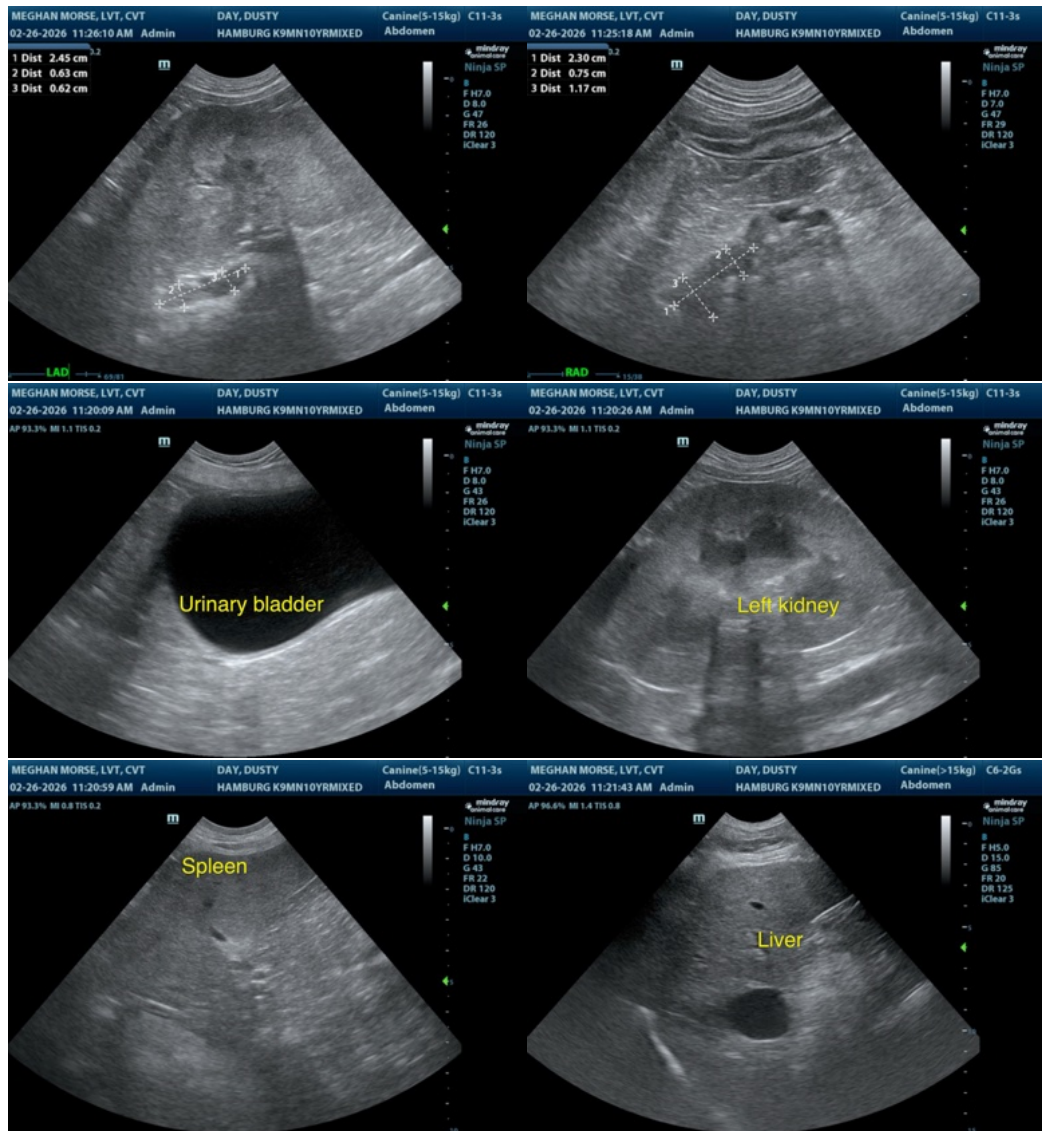
Dr. Branning

INVOICE

71947

DATE

2/26/26





PATIENT

Dusty Day

SPECIES

Canine

BREED

Mix

SEX

Neutered male

AGE

10 years

WEIGHT

74.5 lbs

INTERPRETED BY

Remo Lobetti, BVSc,
 MMedVet (Med),
 PhD, Dipl. ECVIM

IMAGING PERFORMED BY

Meghan Morse, LVT,
 CVT

HOSPITAL NAME

Hamburg VC

REFERRING VET

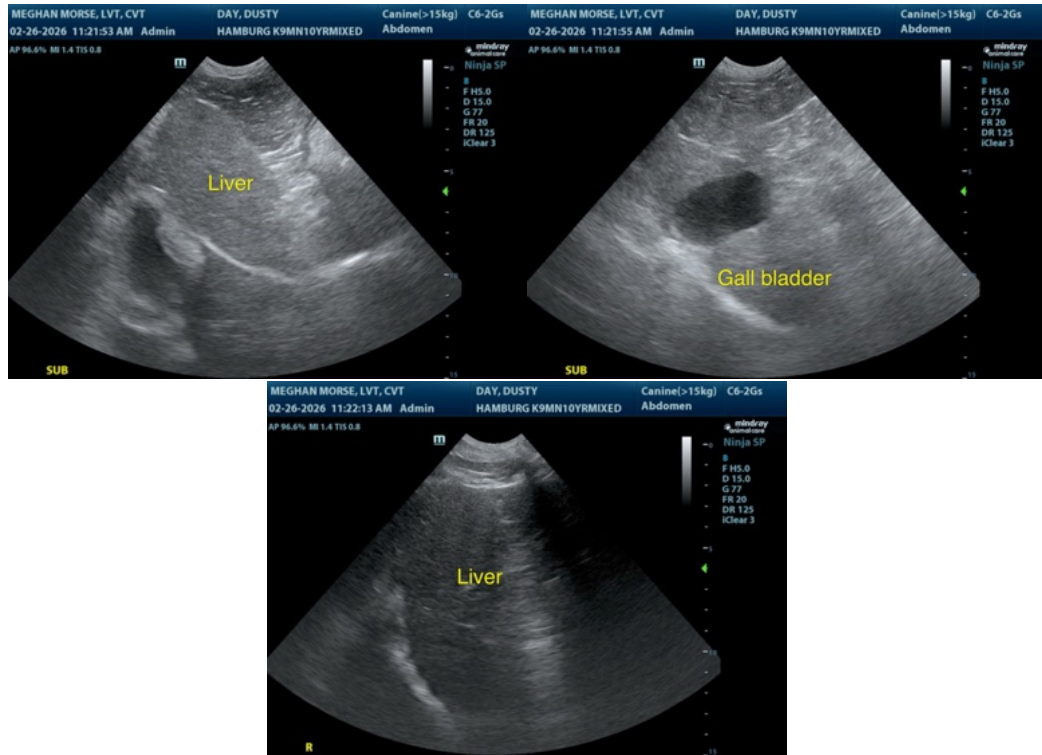
Dr. Branning

INVOICE

71947

DATE

2/26/26



The information and recommendations provided are based on the images presented by the referring veterinarian/sonographer. No evaluation can be communicated regarding pathology that was not visible in the image/video clips provided.

Thank you for this referral. If the clinical or image interpretation does not parallel your findings or if I can be of any further assistance please contact me.

Remo Lobetti, BVSc, MMedVet (Med), PhD, Dipl. ECVIM (Internal Medicine)

info@sonopath.com