



PATIENT

Rusty Kent

SPECIES

Canine

BREED

Yorkshire Terrier

SEX

Neutered male

AGE

8 years

WEIGHT

16.8 lbs

INTERPRETED BY

Remo Lobetti, BVSc,
MMedVet (Med),
PhD, Dipl. ECVIM

IMAGING PERFORMED BY

Dr. Ken Leal

HOSPITAL NAME

Newton VH

REFERRING VET

Dr. Timony

INVOICE

71583

DATE

2/16/26

PRESENTING CLINICAL SIGNS

- Intermittent vomiting and inappetence
- CPL = normal

ULTRASONOGRAPHIC EXAMINATION OF THE ABDOMEN

Urinary System

The urinary bladder is small with a normal thickness and smooth appearance of the wall. Normal anechoic urine with no sediment or uroliths evident.

Normal appearance of the trigone area, proximal urethra, and iliac blood vessels.

Normal appearance and size of the iliac lymph nodes. Ureters not visualized, which can be considered a normal finding.

Normal renal size (left measured 4.6 cm, right measured 4.6 cm), architecture, echogenic appearance, cortico-medullary differentiation, which maintains a 1:3 cortex to medulla ratio, pelvis, and capsule. No infarcts, mineralization or renoliths evident.

The prostate measures 0.8 cm in width.

Adrenal Glands

Normal shape, echogenic appearance, size, position, and appearance of the visible peri-adrenal vasculature. Left adrenal gland measured 1.76 cm in length x 0.47 cm and 0.46 cm in width. The right adrenal gland measured 1.92 cm in length x 0.53 cm in width.

Spleen

Normal size and echogenic appearance. Smooth homogenous parenchyma and regular curvilinear capsule. Normal volume of the splenic vasculature without any overt congestion or thrombosis evident. No inflammatory, neoplastic, infarction, or infiltrative changes evident. The spleen measured 1.2 cm in width.

Liver

Normal size, echogenic appearance, portal markings, and regular curvilinear capsule. No nodules or masses evident. Normal appearance of the hepatic and portal vasculature.

Gallbladder

The gallbladder is small containing normal anechoic bile. Normal thickness and echogenic appearance of the wall. Normal size and appearance of the cystic and common bile duct.



PATIENT

Rusty Kent

SPECIES

Canine

BREED

Yorkshire Terrier

SEX

Neutered male

AGE

8 years

WEIGHT

16.8 lbs

INTERPRETED BY

Remo Lobetti, BVSc,
MMedVet (Med),
PhD, Dipl. ECVIM

IMAGING PERFORMED BY

Dr. Ken Leal

HOSPITAL NAME

Newton VH

REFERRING VET

Dr. Timony

INVOICE

71583

DATE

2/16/26

Gastrointestinal

Normal appearance of the stomach, duodenum, small intestine, ileo-cecal junction, and colon with no loss of layering, 1:3 muscularis to mucosa ratio, normal wall thickness and peristaltic activity, and no distension of the lumen.

Pancreas

Normal size (left pancreas measured 1.1 cm) with the left lobe having a hypoechogenic appearance and the right lobe having a hyperechogenic echogenic appearance with both lobes showing an irregular capsule. Mild increase in the echogenic appearance of the mesentery and fat surrounding the pancreas.

Free Abdomen

Normal mesenteric lymph nodes.
No ascites evident.

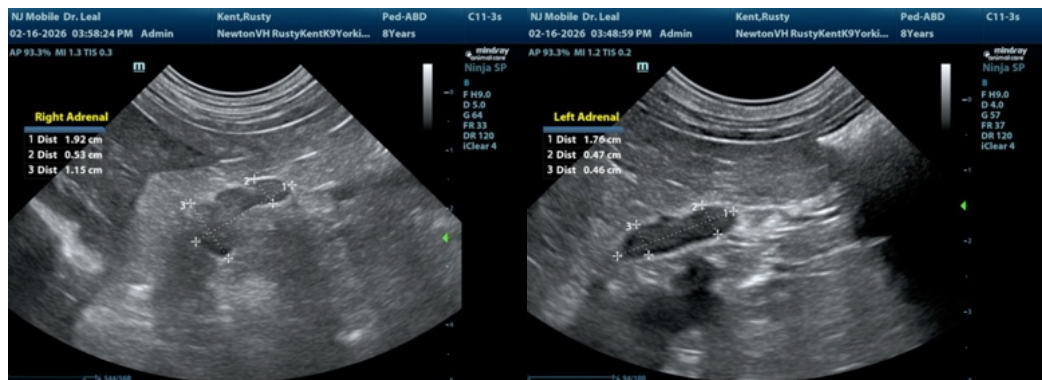
ULTRASONOGRAPHIC FINDINGS

- Pancreatitis.

INTERPRETATION OF THE FINDINGS & FURTHER RECOMMENDATIONS

The appearance of the pancreas would be consistent with chronic active pancreatitis even though CPL is within reference range.

Management of the pancreatitis would be fluid therapy, antiemetics, opioid analgesics and feeding small frequent meals of a low fat intestinal type diet.





PATIENT

Rusty Kent

SPECIES

Canine

BREED

Yorkshire Terrier

SEX

Neutered male

AGE

8 years

WEIGHT

16.8 lbs

INTERPRETED BY

Remo Lobetti, BVSc,
 MMedVet (Med),
 PhD, Dipl. ECVIM

IMAGING PERFORMED BY

Dr. Ken Leal

HOSPITAL NAME

Newton VH

REFERRING VET

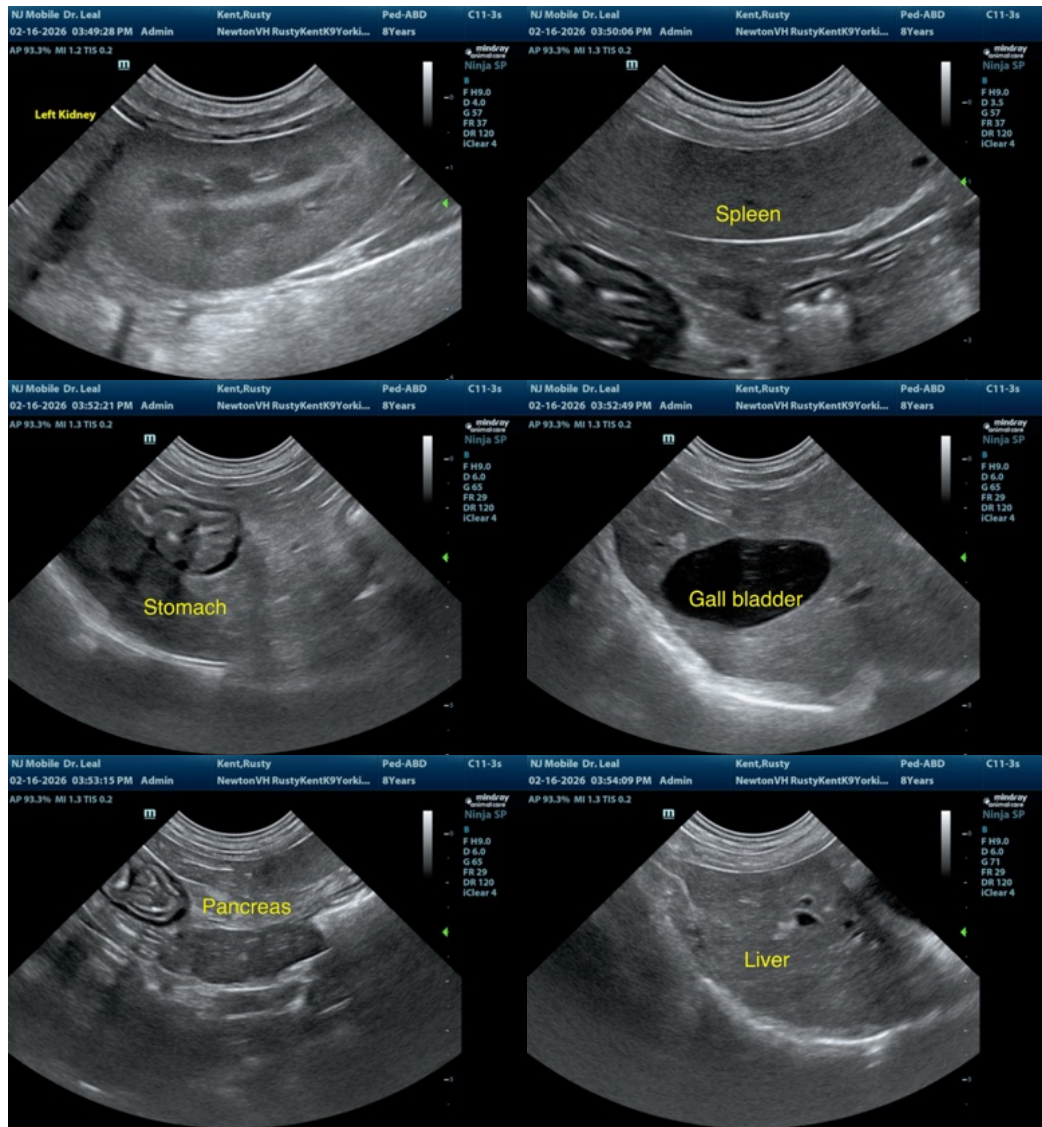
Dr. Timony

INVOICE

71583

DATE

2/16/26





PATIENT

Rusty Kent

SPECIES

Canine

BREED

Yorkshire Terrier

SEX

Neutered male

AGE

8 years

WEIGHT

16.8 lbs

INTERPRETED BY

Remo Lobetti, BVSc,
 MMedVet (Med),
 PhD, Dipl. ECVIM

IMAGING PERFORMED BY

Dr. Ken Leal

HOSPITAL NAME

Newton VH

REFERRING VET

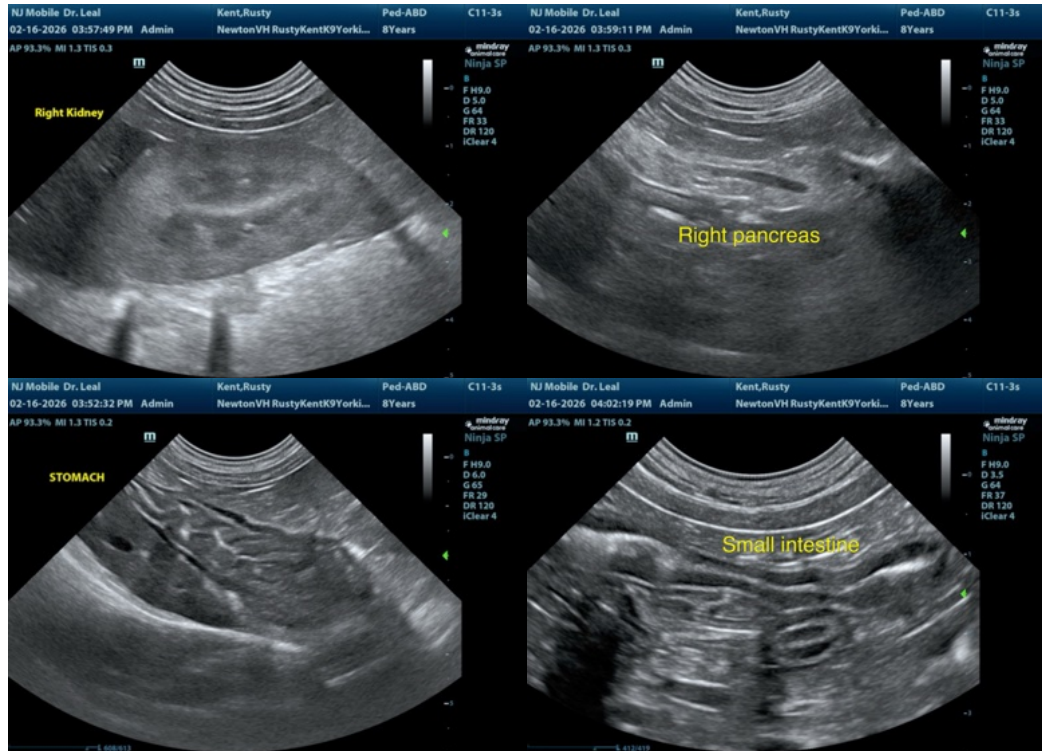
Dr. Timony

INVOICE

71583

DATE

2/16/26



The information and recommendations provided are based on the images presented by the referring veterinarian/sonographer. No evaluation can be communicated regarding pathology that was not visible in the image/video clips provided.

Thank you for this referral. If the clinical or image interpretation does not parallel your findings or if I can be of any further assistance please contact me.

Remo Lobetti, BVSc, MMedVet (Med), PhD, Dipl. ECVIM (Internal Medicine)

info@sonopath.com