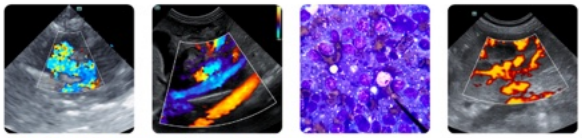

Clinical Sonography & Telecytology
Educational Teleconsultation Services™

PATIENT
Goldie Cerino

SPECIES
Canine

BREED
Mix

SEX
Spayed female

AGE
9 years

WEIGHT
39 lbs

INTERPRETED BY
Remo Lobetti, BVSc, MMedVet (Med), PhD, Dipl. ECVIM

IMAGING PERFORMED BY
Kerri Becker

HOSPITAL NAME
Marsh AH

REFERRING VET
Dr. Armani

INVOICE
69616

DATE
12/29/25

PRESENTING CLINICAL SIGNS

History: HX valve dz. Proteinuria, hypothyroid, allergies, no murmur
Abnormal PE/Chem/CBC/UA Results: ALP-1034 UAprot-3+ UPC-3.5 USG-1.026

ULTRASONOGRAPHIC EXAMINATION OF THE ABDOMEN

Urinary System

The urinary bladder is small with a normal thickness and smooth appearance of the wall. Normal anechoic urine with no sediment or uroliths evident.

Normal appearance of the trigone area, proximal urethra, and iliac blood vessels.

Normal appearance and size of the iliac lymph nodes. Ureters not visualized, which can be considered a normal finding.

Normal renal size (left measured 6.6 cm, right measured 6.9 cm), architecture, echogenic appearance, cortico-medullary differentiation, which maintains a 1:3 cortex to medulla ratio, pelvis, and capsule. No infarcts, mineralization or renoliths evident. Normal color flow pattern is evident in both kidneys.

Adrenal Glands

Normal shape, echogenic appearance, size, position, and appearance of the visible peri-adrenal vasculature. Left adrenal gland measured 2.56 cm in length x 0.77 cm and 0.75 cm in width. The right adrenal gland measured 2.46 cm in length x 0.93 cm and 0.56 cm in width.

Spleen

Normal size and echogenic appearance. Smooth homogenous parenchyma and regular curvilinear capsule. Normal volume of the splenic vasculature without any overt congestion or thrombosis evident. No inflammatory, neoplastic, infarction, or infiltrative changes evident. The spleen measured 2.0 cm in width.

Liver

Normal size with a diffuse increased echogenic, coarse and nodular appearance, prominent portal markings, and regular curvilinear capsule. Nodules are faint, small, parenchymal and hypoechogenic. No masses evident. Normal appearance of the hepatic and portal vasculature.

Gallbladder

The gallbladder is full containing normal anechoic bile. Normal thickness and echogenic appearance of the wall. Normal size and appearance of the cystic and common bile duct.

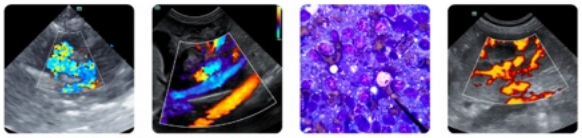

PATIENT

Goldie Cerino

SPECIES

Canine

BREED

Mix

SEX

Spayed female

AGE

9 years

WEIGHT

39 lbs

INTERPRETED BY

Remo Lobetti, BVSc, MMedVet (Med), PhD, Dipl. ECVIM

IMAGING PERFORMED BY

Kerri Becker

HOSPITAL NAME

Marsh AH

REFERRING VET

Dr. Armani

INVOICE

69616

DATE

12/29/25

Gastrointestinal

Normal appearance of the stomach, duodenum, small intestine, ileo-cecal junction, and colon with no loss of layering, 1:3 muscularis to mucosa ratio, normal wall thickness and peristaltic activity, and no distension of the lumen.

Pancreas

The visible sections of the pancreas are of normal size and echogenic appearance with a regular capsule. Normal echogenic appearance of the mesentery and fat surrounding the pancreas.

Free Abdomen

Normal mesenteric lymph nodes.

No ascites evident.

ULTRASONOGRAPHIC FINDINGS

- Nodular hepatopathy.

INTERPRETATION OF THE FINDINGS & FURTHER RECOMMENDATIONS

The appearance of the liver on this ultrasound is similar to that of the previous ultrasound. Therefore, the most likely diagnosis is nodular hyperplasia with granulomatous disease and infiltrative neoplasia highly unlikely differential diagnosis.

Further assessment would be FNA cytology of the liver. However, a tru cut or wedge biopsy may be required for a final etiological diagnosis.

Management of the hepatopathy would be to continue with the current therapy. Additional therapy that can be considered for the proteinuria would be the addition of an angiotensin receptor blocker and Omega 3 fatty acids.

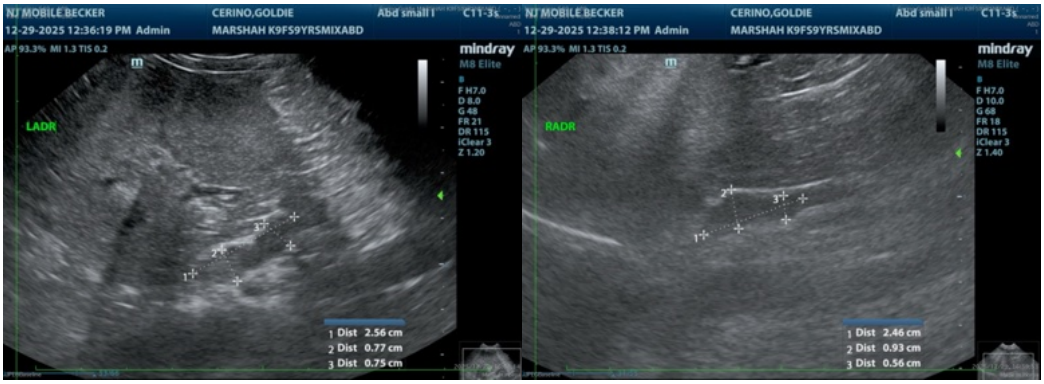

New Jersey Mobile
FUELED BY SONOPATH VETERINARY ULTRASOUND

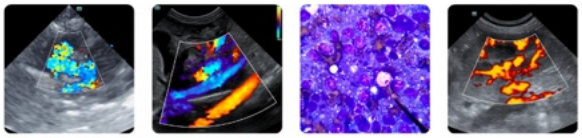

Clinical Sonography & Telecytology
Educational Teleconsultation Services™

SonoPath
FOSTERING THE ART OF VETERINARY MEDICINE™
www.SonoPath.com
info@sonopath.com 800.838.4268

PATIENT

Goldie Cerino

SPECIES

Canine

BREED

Mix

SEX

Spayed female

AGE

9 years

WEIGHT

39 lbs

INTERPRETED BY

Remo Lobetti, BVSc, MMedVet (Med), PhD, Dipl. ECVIM

IMAGING PERFORMED BY

Kerri Becker

HOSPITAL NAME

Marsh AH

REFERRING VET

Dr. Armani

INVOICE

69616

DATE

12/29/25

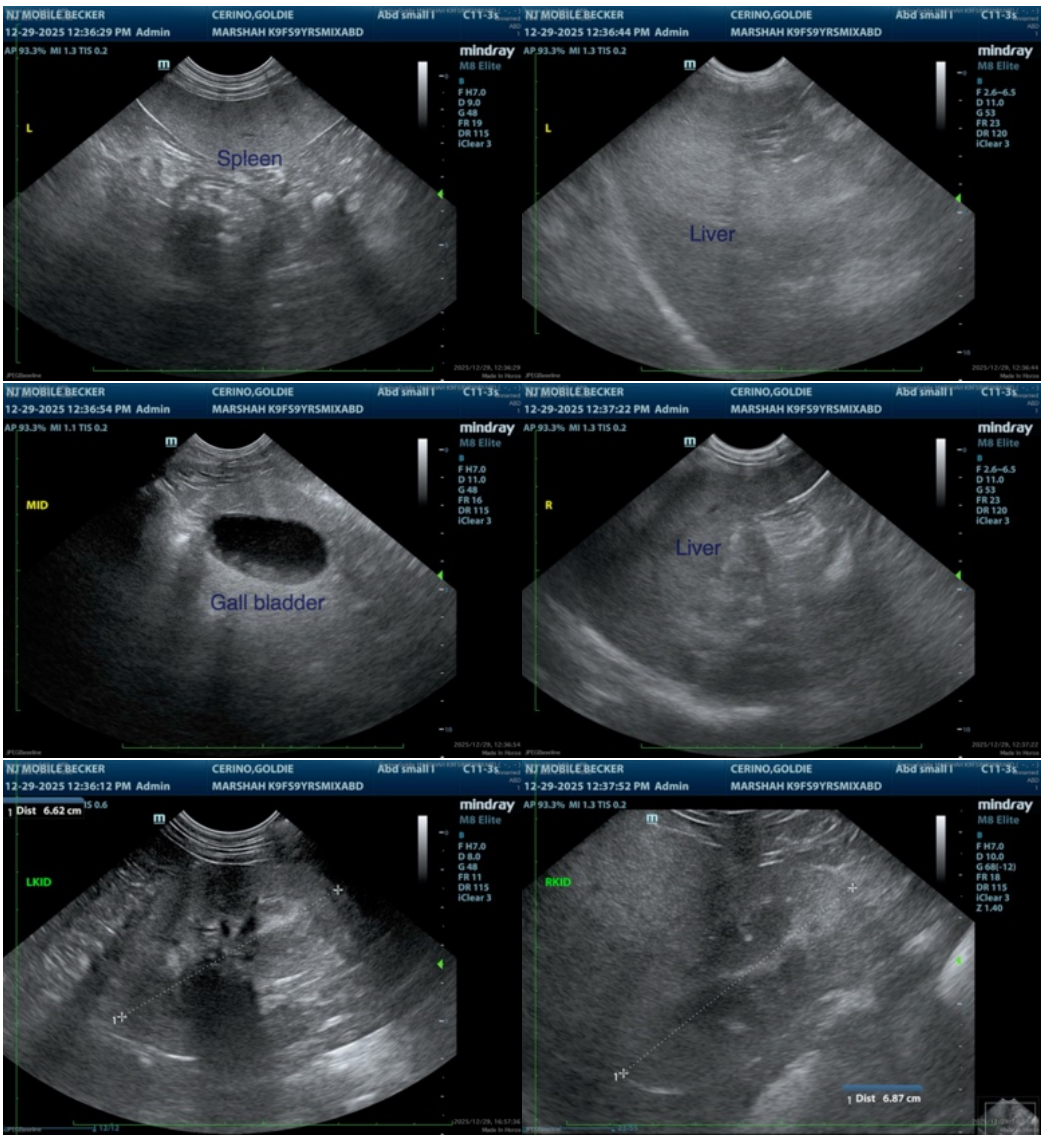

The information and recommendations provided are based on the images presented by the referring veterinarian/sonographer. No evaluation can be communicated regarding pathology that was not visible in the image/video clips provided.

Thank you for this referral. If the clinical or image interpretation does not parallel your findings or if I can be of any further assistance please contact me.

Remo Lobetti, BVSc, MMedVet (Med), PhD, Dipl. ECVIM (Internal Medicine)

info@sonopath.com