



**PATIENT**

Donovan Diiorio

**SPECIES**

Canine

**BREED**

Mastiff

**SEX**

Neutered male

**AGE**

9 years

**WEIGHT**

119.5 lbs

**INTERPRETED BY**

Remo Lobetti, BVSc,  
MMedVet (Med),  
PhD, Dipl. ECVIM

**IMAGING PERFORMED BY**

Kerri Becker

**HOSPITAL NAME**

Legacy AH

**REFERRING VET**

Dr. Pontenzone

**INVOICE**

69482

**DATE**

12/22/25

**PRESENTING CLINICAL SIGNS**

History: Hepatopathy, suspected autoimmune vs. neoplasia. Prev. AUS done elsewhere found nothing. Pred 40mg QD  
ALB-2.0 GLOB-4.2 ALT-593 ALP-5,034 GGT-125 BILI-0.5 lipase-294

**ULTRASONOGRAPHIC EXAMINATION OF THE ABDOMEN**

**Urinary System**

The urinary bladder is full with a normal thickness and smooth appearance of the wall. Normal anechoic urine with no sediment or uroliths evident.

Normal appearance of the trigone area, proximal urethra, and iliac blood vessels.

Normal appearance and size of the iliac lymph nodes. Ureters not visualized, which can be considered a normal finding.

Normal renal size (left measured 7.6 cm, right measured 8.0 cm), architecture, echogenic appearance, cortico-medullary differentiation, which maintains a 1:3 cortex to medulla ratio, pelvis, and capsule. No infarcts, mineralization or renoliths evident. Normal color flow pattern is evident in both kidneys.

The prostate is small and hypoechogenic.

**Adrenal Glands**

The adrenal glands are not visualized.

**Spleen**

Normal size and echogenic appearance. Smooth homogenous parenchyma and regular curvilinear capsule. Normal volume of the splenic vasculature without any overt congestion or thrombosis evident. No inflammatory, neoplastic, infarction, or infiltrative changes evident. The spleen measured 3.5 cm in width.

**Liver**

Normal size, with a diffuse increased echogenic appearance, normal portal markings, and regular curvilinear capsule. No nodules or masses evident. Normal appearance of the hepatic and portal vasculature.

**Gallbladder**

The gallbladder is small containing normal anechoic bile. Normal thickness and echogenic appearance of the wall. Normal size and appearance of the cystic and common bile duct.



**PATIENT**

Donovan Diiorio

**SPECIES**

Canine

**BREED**

Mastiff

**SEX**

Neutered male

**AGE**

9 years

**WEIGHT**

119.5 lbs

**INTERPRETED BY**

Remo Lobetti, BVSc,  
MMedVet (Med),  
PhD, Dipl. ECVIM

**IMAGING PERFORMED BY**

Kerri Becker

**HOSPITAL NAME**

Legacy AH

**REFERRING VET**

Dr. Pontenzone

**INVOICE**

69482

**DATE**

12/22/25

**Gastrointestinal**

Normal appearance of the stomach, duodenum, small intestine, ileo-cecal junction, and colon with no loss of layering, 1:3 muscularis to mucosa ratio, normal wall thickness and peristaltic activity, and no distension of the lumen.

**Pancreas**

The visible sections of the pancreas are of normal size and echogenic appearance with a regular capsule. Normal echogenic appearance of the mesentery and fat surrounding the pancreas.

**Free Abdomen**

Normal mesenteric lymph nodes.

No ascites evident.

**ULTRASONOGRAPHIC FINDINGS**

- Hepatopathy.

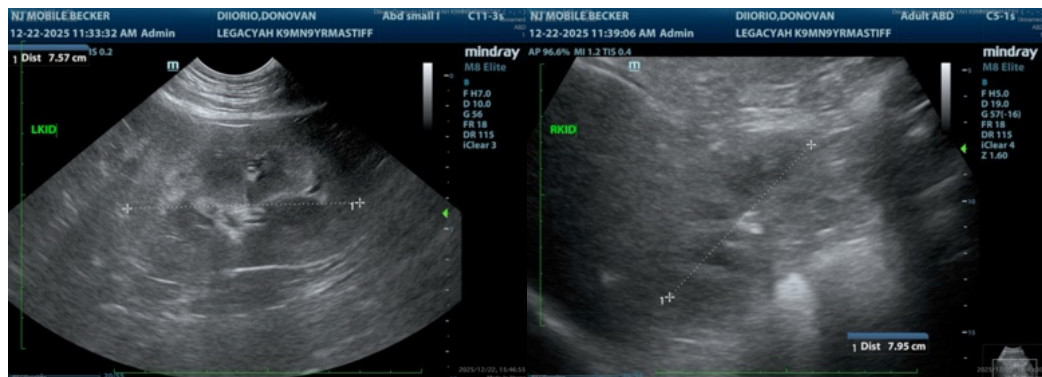
**INTERPRETATION OF THE FINDINGS & FURTHER RECOMMENDATIONS**

Etiologies for the hepatopathy would be reactive hyperplasia, vacuolar, metabolic and possibly drug induced with hepatitis and infiltrative neoplasia a highly unlikely differential diagnosis.

Further assessment would be FNA cytology of the liver. However, a tru cut or wedge biopsy may be required for a final etiological diagnosis.

Specific therapy would be dependent on an etiological diagnosis.

Symptomatic management that can be considered would be the use of Ursodiol with regular monitoring of liver enzyme activity.





**PATIENT**

Donovan Diorio

**SPECIES**

Canine

**BREED**

Mastiff

**SEX**

Neutered male

**AGE**

9 years

**WEIGHT**

119.5 lbs

**INTERPRETED BY**

Remo Lobetti, BVSc,  
MMedVet (Med),  
PhD, Dipl. ECVIM

**IMAGING PERFORMED BY**

Kerri Becker

**HOSPITAL NAME**

Legacy AH

**REFERRING VET**

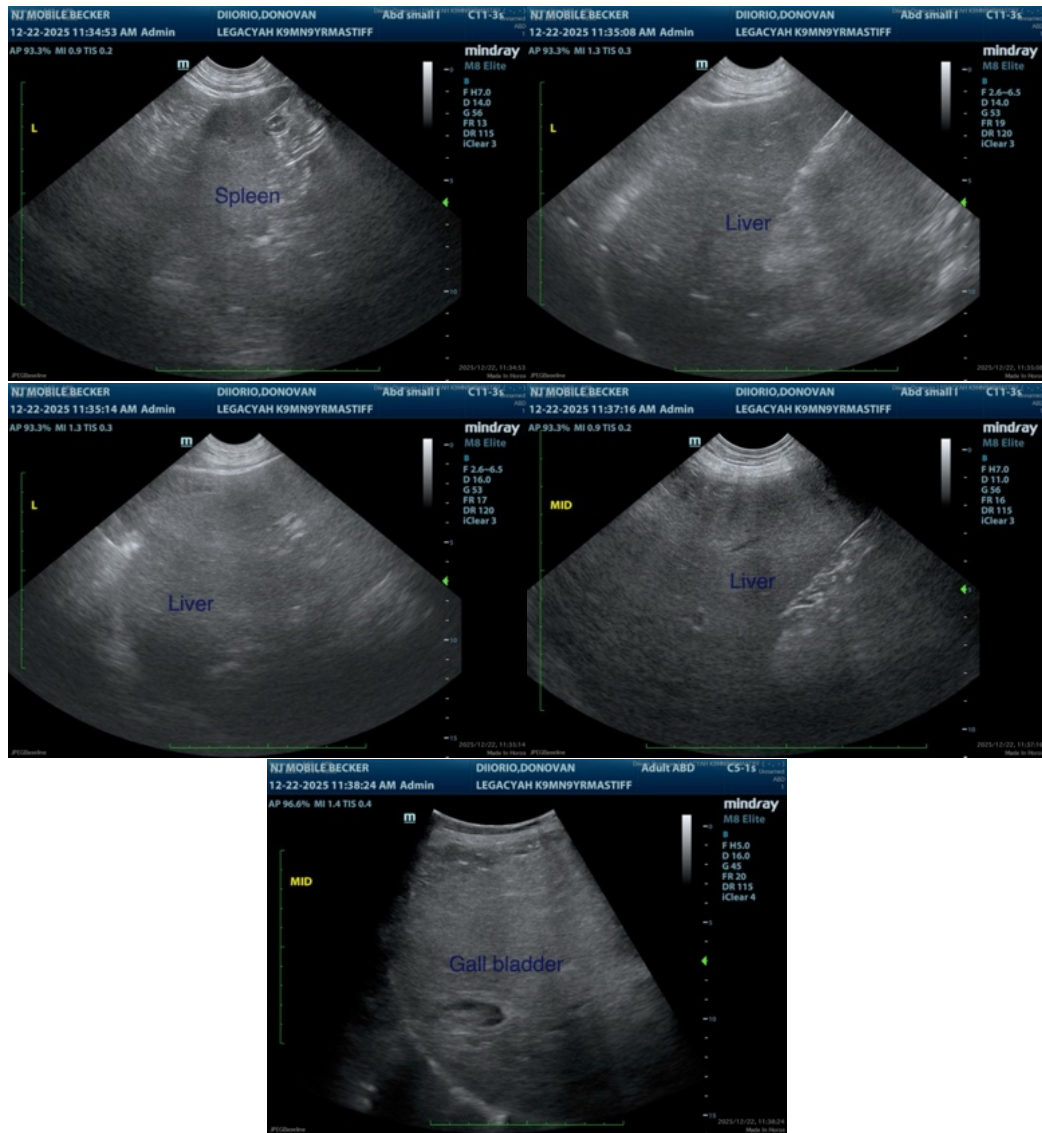
Dr. Pontenzone

**INVOICE**

69482

**DATE**

12/22/25



The information and recommendations provided are based on the images presented by the referring veterinarian/sonographer. No evaluation can be communicated regarding pathology that was not visible in the image/video clips provided.

Thank you for this referral. If the clinical or image interpretation does not parallel your findings or if I can be of any further assistance please contact me.

**Remo Lobetti, BVSc, MMedVet (Med), PhD, Dipl. ECVIM (Internal Medicine)**  
[info@sonopath.com](mailto:info@sonopath.com)