



PATIENT

Sofie Scheffler

SPECIES

Canine

BREED

Golden Retriever

SEX

Spayed female

AGE

12 years

WEIGHT

70 lbs

INTERPRETED BY

Remo Lobetti, BVSc,
MMedVet (Med),
PhD, Dipl. ECVIM

IMAGING PERFORMED BY

Kerri Becker

HOSPITAL NAME

Banfield Pet Hospital
of Bridgewater

REFERRING VET

Dr. Verma

INVOICE

69413

DATE

12/18/25

PRESENTING CLINICAL SIGNS

History: Elev. pre-post bile acid. RT axillary mass 15x20, 8cm mass on lateral aspect of elbow, cystic mass right flank, generalized weakness bilateral rear.
Abnormal PE/Chem/CBC/UA Results: Elev. bile acids

ULTRASONOGRAPHIC EXAMINATION OF THE ABDOMEN

Urinary System

The urinary bladder is small with a normal thickness and smooth appearance of the wall. Normal anechoic urine with no sediment or uroliths evident.

Normal appearance of the trigone area, proximal urethra, and iliac blood vessels.

Normal appearance and size of the iliac lymph nodes. Ureters not visualized, which can be considered a normal finding.

Normal renal size (left measured 6.5 cm, right measured 5.8 cm), architecture, echogenic appearance, cortico-medullary differentiation, which maintains a 1:3 cortex to medulla ratio, pelvis, and capsule. No infarcts, mineralization or renoliths evident.

Adrenal Glands

Normal shape, echogenic appearance, size, position, and appearance of the visible peri-adrenal vasculature. Left adrenal gland measured 3.16 cm in length x 0.94 cm and 0.54 cm in width. The right adrenal gland measured 2.31 cm in length x 0.94 cm and 0.74 cm in width.

Spleen

Normal size and echogenic appearance. Smooth homogenous parenchyma and regular curvilinear capsule. Normal volume of the splenic vasculature without any overt congestion or thrombosis evident. No inflammatory, neoplastic, infarction, or infiltrative changes evident. The spleen measured 2.8 cm in width.

Liver

Normal size, echogenic appearance, portal markings, and regular curvilinear capsule. No nodules or masses evident. Normal appearance of the hepatic and portal vasculature.

Gallbladder

The gallbladder is full containing a moderate amount of non-adhered, hyperechogenic sediment. Normal thickness and echogenic appearance of the wall. Normal size and appearance of the cystic and common bile duct.



PATIENT

Sofie Scheffler

SPECIES

Canine

BREED

Golden Retriever

SEX

Spayed female

AGE

12 years

WEIGHT

70 lbs

INTERPRETED BY

Remo Lobetti, BVSc,
MMedVet (Med),
PhD, Dipl. ECVIM

IMAGING PERFORMED BY

Kerri Becker

HOSPITAL NAME

Banfield Pet Hospital
of Bridgewater

REFERRING VET

Dr. Verma

INVOICE

69413

DATE

12/18/25

Gastrointestinal

Normal appearance of the stomach, duodenum, small intestine, ileo-cecal junction, and colon with no loss of layering, 1:3 muscularis to mucosa ratio, normal wall thickness and peristaltic activity, and no distension of the lumen.

Pancreas

The visible sections of the pancreas are of normal size and echogenic appearance with a regular capsule. Normal echogenic appearance of the mesentery and fat surrounding the pancreas.

Free Abdomen

Normal mesenteric lymph nodes.

No ascites evident.

ULTRASONOGRAPHIC FINDINGS

- Gallbladder sediment.

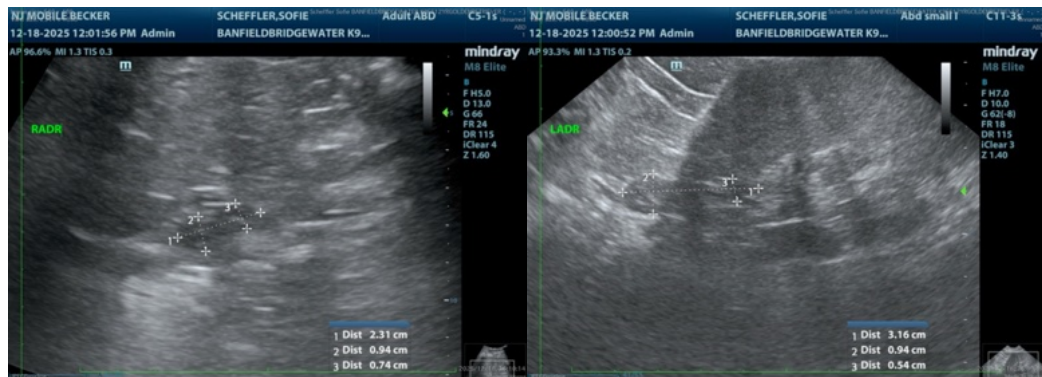
INTERPRETATION OF THE FINDINGS & FURTHER RECOMMENDATIONS

On this ultrasound there was no obvious etiology for the elevated post prandial bile acids, which may be an incidental finding.

The gallbladder sediment is most likely an incidental finding.

Further assessment that can be considered would be FNA cytology of the liver. However, a true cut or wedge biopsy may be required for a final etiological diagnosis.

Specific therapy would be dependent on an etiological diagnosis.





PATIENT

Sofie Scheffler

SPECIES

Canine

BREED

Golden Retriever

SEX

Spayed female

AGE

12 years

WEIGHT

70 lbs

INTERPRETED BY

Remo Lobetti, BVSc,
MMedVet (Med),
PhD, Dipl. ECVIM

IMAGING PERFORMED BY

Kerri Becker

HOSPITAL NAME

Banfield Pet Hospital
of Bridgewater

REFERRING VET

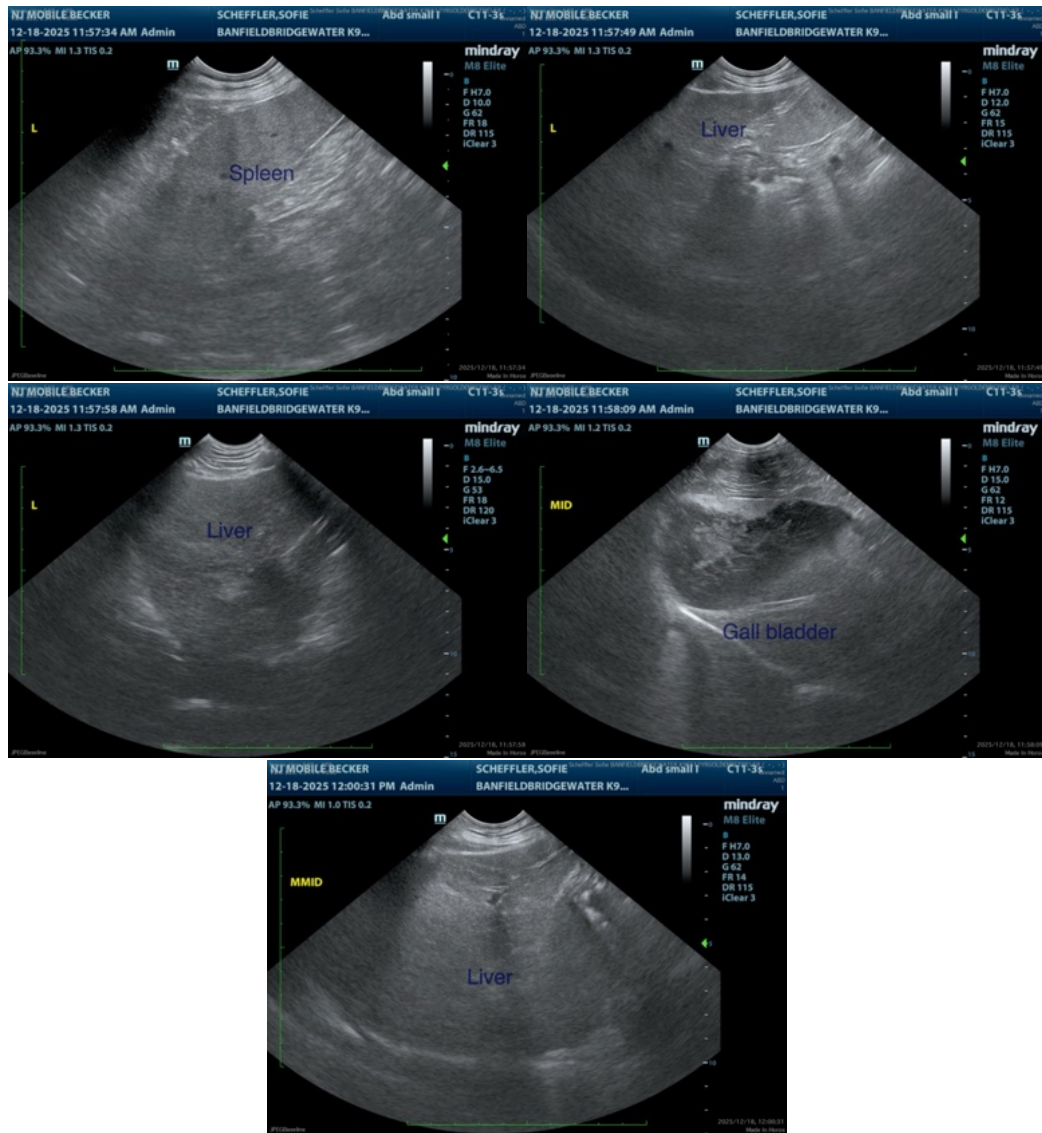
Dr. Verma

INVOICE

69413

DATE

12/18/25



The information and recommendations provided are based on the images presented by the referring veterinarian/sonographer. No evaluation can be communicated regarding pathology that was not visible in the image/video clips provided.

Thank you for this referral. If the clinical or image interpretation does not parallel your findings or if I can be of any further assistance please contact me.

Remo Lobetti, BVSc, MMedVet (Med), PhD, Dipl. ECVIM (Internal Medicine)

info@sonopath.com