



## PATIENT

Gizmo Butcher

## SPECIES

Feline

## BREED

Ragdoll

## SEX

Neutered male

## AGE

4 years

## WEIGHT

4.22 kg

## INTERPRETED BY

Remo Lobetti, BVSc,  
MMedVet (Med),  
PhD, Dipl. ECVIM

## IMAGING PERFORMED BY

Shari Reffi, CVT

## HOSPITAL NAME

Magnolia VP

## REFERRING VET

Dr. Goldstein

## INVOICE

69317

## DATE

12/16/25

## PRESENTING CLINICAL SIGNS

History: Weight loss and chronic anemia. Underweight BCS 3/5. Meds: Carsfate, Famotidinetril (completed).

HCT 25-28 over 1 month, mild regeneration. Fecal neg; Anemia panel wnl.

## ULTRASONOGRAPHIC EXAMINATION OF THE ABDOMEN

### *Urinary System*

The urinary bladder is full with a normal thickness and smooth appearance of the wall. Normal anechoic urine with no sediment or uroliths evident.

Normal appearance of the trigone area, proximal urethra, and iliac blood vessels.

Normal appearance and size of the iliac lymph nodes. Ureters not visualized, which can be considered a normal finding.

Normal renal size (left measured 3.9 cm, right measured 3.6 cm), architecture, echogenic appearance, cortico-medullary differentiation, which maintains a 1:3 cortex to medulla ratio, pelvis, and capsule. No infarcts, mineralization or renoliths evident. Normal color flow pattern is evident in both kidneys.

### *Adrenal Glands*

Normal shape, echogenic appearance, size, position, and appearance of the visible peri-adrenal vasculature. Left adrenal gland measured 0.42 cm in width. The right adrenal gland measured 0.51 cm in width.

### *Spleen*

The spleen was diffusely enlarged and measured 1.4 cm in width maintaining a normal echogenic appearance, smooth homogenous parenchyma and a regular curvilinear capsule.

### *Liver*

Normal size, echogenic appearance, portal markings, and regular curvilinear capsule. No nodules or masses evident. Normal appearance of the hepatic and portal vasculature.

### *Gallbladder*

The gallbladder is small containing normal anechoic bile. Normal thickness and echogenic appearance of the wall. Normal size and appearance of the cystic and common bile duct.



## PATIENT

Gizmo Butcher

## SPECIES

Feline

## BREED

Ragdoll

## SEX

Neutered male

## AGE

4 years

## WEIGHT

4.22 kg

## INTERPRETED BY

Remo Lobetti, BVSc,  
MMedVet (Med),  
PhD, Dipl. ECVIM

## IMAGING PERFORMED BY

Shari Reffi, CVT

## HOSPITAL NAME

Magnolia VP

## REFERRING VET

Dr. Goldstein

## INVOICE

69317

## DATE

12/16/25

## Gastrointestinal

Normal appearance of the stomach, duodenum, small intestine, ileo-cecal junction, and colon with no loss of layering, 1:3 muscularis to mucosa ratio, normal wall thickness and peristaltic activity, and no distension of the lumen.

## Pancreas

The visible sections of the pancreas are of normal size and echogenic appearance with a regular capsule. Normal echogenic appearance of the mesentery and fat surrounding the pancreas.

## Free Abdomen

Normal mesenteric lymph nodes.

No ascites evident.

## ULTRASONOGRAPHIC FINDINGS

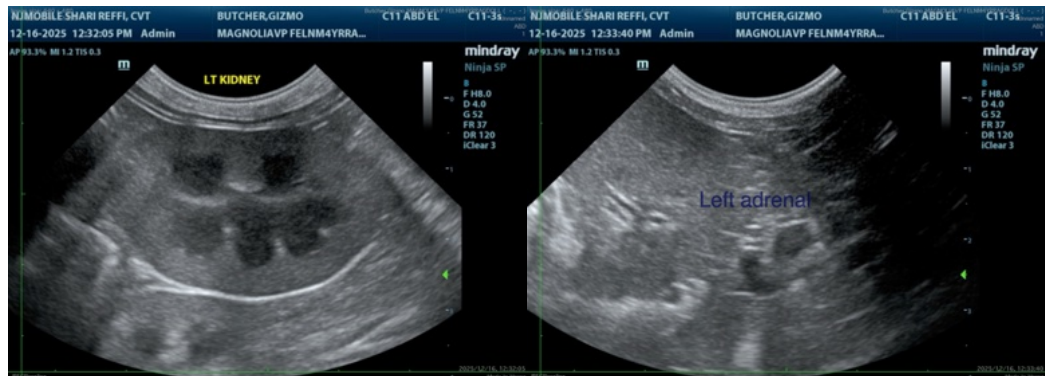
- Splenomegaly.

## INTERPRETATION OF THE FINDINGS & FURTHER RECOMMENDATIONS

Etiologies for the splenomegaly would be reactive hyperplasia, splenitis and possibly infiltrative neoplasia.

Further assessment would be FNA cytology of the spleen, bone marrow cytology/biopsy could also be considered.

Specific therapy would be dependent on an etiological diagnosis.





**PATIENT**

Gizmo Butcher

**SPECIES**

Feline

**BREED**

Ragdoll

**SEX**

Neutered male

**AGE**

4 years

**WEIGHT**

4.22 kg

**INTERPRETED BY**

Remo Lobetti, BVSc,  
MMedVet (Med),  
PhD, Dipl. ECVIM

**IMAGING PERFORMED BY**

Shari Reffi, CVT

**HOSPITAL NAME**

Magnolia VP

**REFERRING VET**

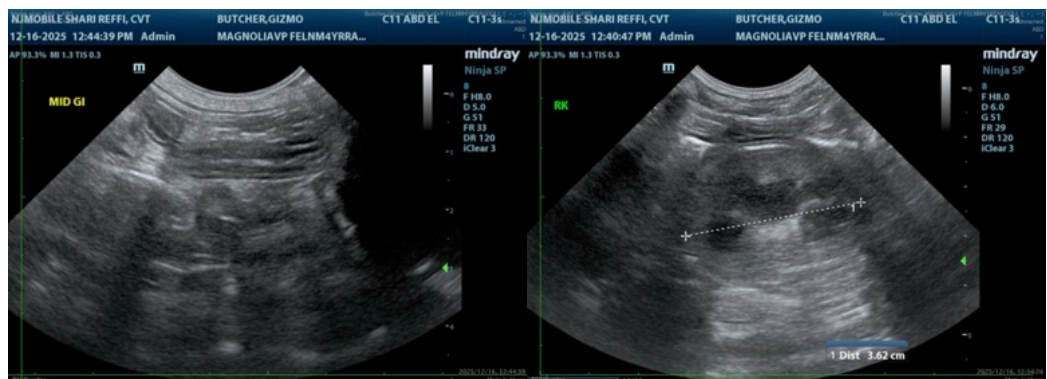
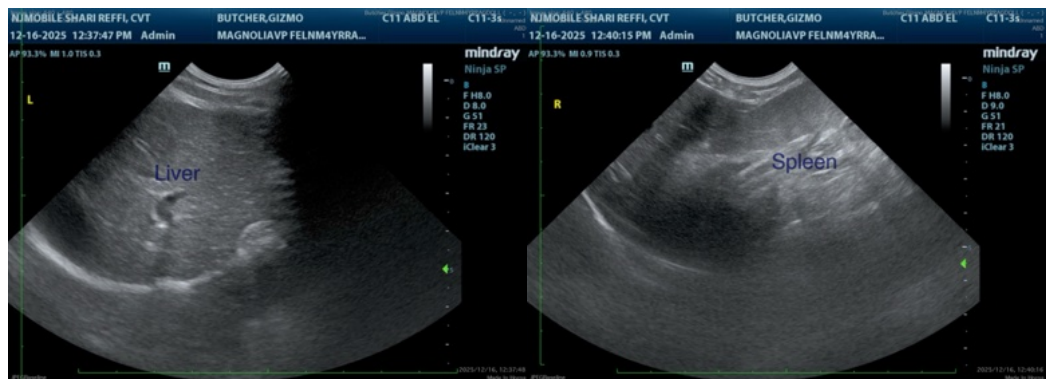
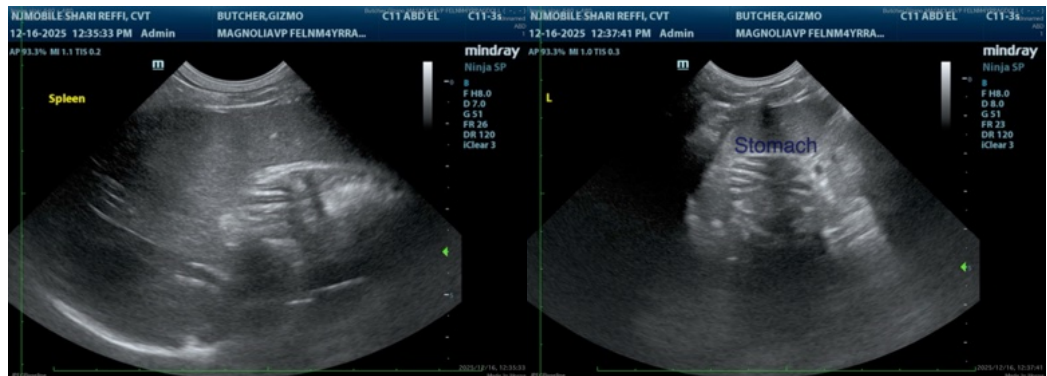
Dr. Goldstein

**INVOICE**

69317

**DATE**

12/16/25



The information and recommendations provided are based on the images presented by the referring veterinarian/sonographer. No evaluation can be communicated regarding pathology that was not visible in the image/video clips provided.

Thank you for this referral. If the clinical or image interpretation does not parallel your findings or if I can be of any further assistance please contact me.

Remo Lobetti, BVSc, MMedVet (Med), PhD, Dipl. ECVIM (Internal Medicine)

[info@sonopath.com](mailto:info@sonopath.com)



## **PATIENT**

Gizmo Butcher

## **SPECIES**

Feline

## **BREED**

Ragdoll

## **SEX**

Neutered male

## **AGE**

4 years

## **WEIGHT**

4.22 kg

## **INTERPRETED BY**

Remo Lobetti, BVSc,  
MMedVet (Med),  
PhD, Dipl. ECVIM

## **IMAGING PERFORMED BY**

Shari Reffi, CVT

## **HOSPITAL NAME**

Magnolia VP

## **REFERRING VET**

Dr. Goldstein

## **INVOICE**

69317

## **DATE**

12/16/25