



PATIENT

Peeve Abramowitz

SPECIES

Canine

BREED

Flat Coated Retriever

SEX

Intact male

AGE

10 years

WEIGHT

lbs

INTERPRETED BY

Remo Lobetti, BVSc,
MMedVet (Med),
PhD, Dipl. ECVIM

IMAGING PERFORMED BY

Meghan Morse, LVT,
CVT

HOSPITAL NAME

Animal General
Hudson

REFERRING VET

Dr. DiGiuseppi

INVOICE

69294

DATE

12/15/25

PRESENTING CLINICAL SIGNS

History: Met check for cutaneous digit melanoma Current meds: Claro AU, Clindamycin
Abnormal PE/Chem/CBC/UA Results: Pending

ULTRASONOGRAPHIC EXAMINATION OF THE ABDOMEN

Urinary System

The urinary bladder is full with a normal thickness and smooth appearance of the wall. Normal anechoic urine with no sediment or uroliths evident.

Normal appearance of the trigone area, proximal urethra, and iliac blood vessels.

Normal appearance and size of the iliac lymph nodes. Ureters not visualized, which can be considered a normal finding.

Normal renal size (left measured 7.7 cm, right measured 7.3 cm), architecture, echogenic appearance, cortico-medullary differentiation, which maintains a 1:3 cortex to medulla ratio, pelvis, and capsule. No infarcts, mineralization or renoliths evident. Normal color flow pattern is evident in both kidneys.

The prostate is symmetrically enlarged with a diffuse, hyperechogenic appearance and a smooth curvilinear capsule. Normal echogenic appearance of the peri-prostatic tissue. The prostate measures 4.0 x 5.0 cm in size. Normal size and appearance of both testicles. The left testicle measured 3.5 cm in length and the right testicle measured 3.3 cm in length.

Adrenal Glands

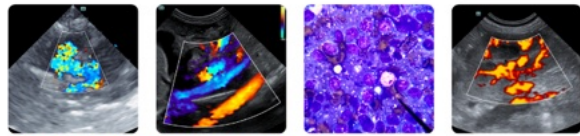
Normal shape, echogenic appearance, size, position, and appearance of the visible peri-adrenal vasculature. Left adrenal gland measured 2.68 cm in length x 0.52 cm and 0.82 cm in width. The right adrenal gland measured 2.68 cm in length x 0.46 cm in width.

Spleen

Normal size and echogenic appearance. Smooth homogenous parenchyma and regular curvilinear capsule. Normal volume of the splenic vasculature without any overt congestion or thrombosis evident. No inflammatory, neoplastic, infarction, or infiltrative changes evident. The spleen measured 2.2 cm in width.

Liver

Normal size, echogenic appearance, portal markings, and regular curvilinear capsule. No nodules or masses evident. Normal appearance of the hepatic and portal vasculature.



PATIENT

Peeve Abramowitz

SPECIES

Canine

BREED

Flat Coated Retriever

SEX

Intact male

AGE

10 years

WEIGHT

lbs

INTERPRETED BY

Remo Lobetti, BVSc,
MMedVet (Med),
PhD, Dipl. ECVIM

**IMAGING
PERFORMED BY**

Meghan Morse, LVT,
CVT

HOSPITAL NAME

Animal General
Hudson

REFERRING VET

Dr. DiGiuseppi

INVOICE

69294

DATE

12/15/25

Gallbladder

The gallbladder is full containing normal anechoic bile. Normal thickness and echogenic appearance of the wall. Normal size and appearance of the cystic and common bile duct.

Gastrointestinal

Normal appearance of the stomach, duodenum, small intestine, ileo-cecal junction, and colon with no loss of layering, 1:3 muscularis to mucosa ratio, normal wall thickness and peristaltic activity, and no distension of the lumen.

Pancreas

The visible sections of the pancreas are of normal size and echogenic appearance with a regular capsule. Normal echogenic appearance of the mesentery and fat surrounding the pancreas.

Free Abdomen

Normal mesenteric lymph nodes.

No ascites evident.

ULTRASONOGRAPHIC FINDINGS

- Prostatomegaly.

INTERPRETATION OF THE FINDINGS & FURTHER RECOMMENDATIONS

The most likely etiology for the prostatomegaly would be benign prostatic hyperplasia, in line with the patient's age and intact nature.

On this ultrasound there is no obvious evidence of metastatic melanoma.



PATIENT

Peeve Abramowitz

SPECIES

Canine

BREED

Flat Coated Retriever

SEX

Intact male

AGE

10 years

WEIGHT

lbs

INTERPRETED BY

Remo Lobetti, BVSc,
 MMedVet (Med),
 PhD, Dipl. ECVIM

IMAGING PERFORMED BY

Meghan Morse, LVT,
 CVT

HOSPITAL NAME

Animal General
 Hudson

REFERRING VET

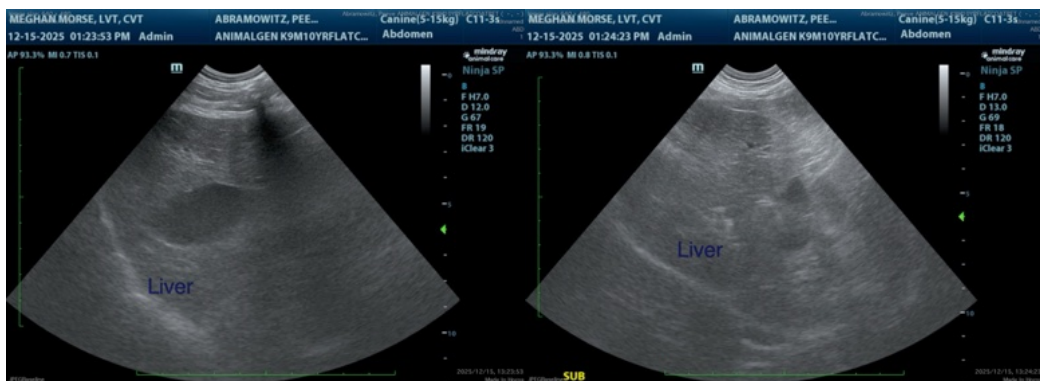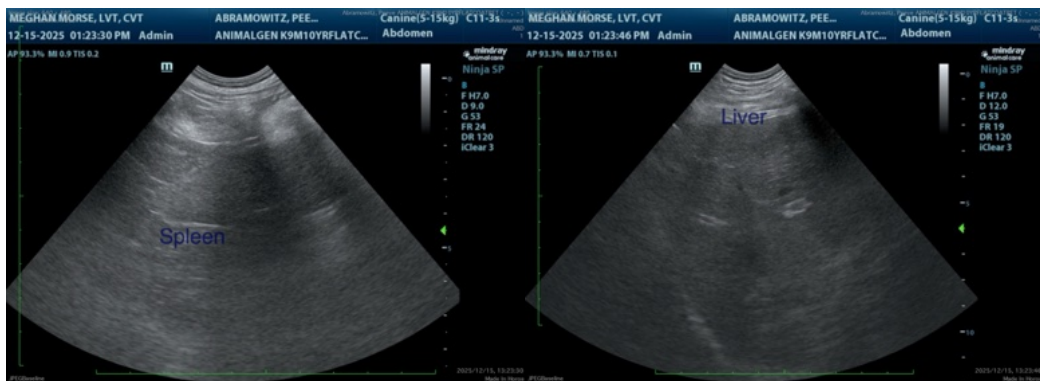
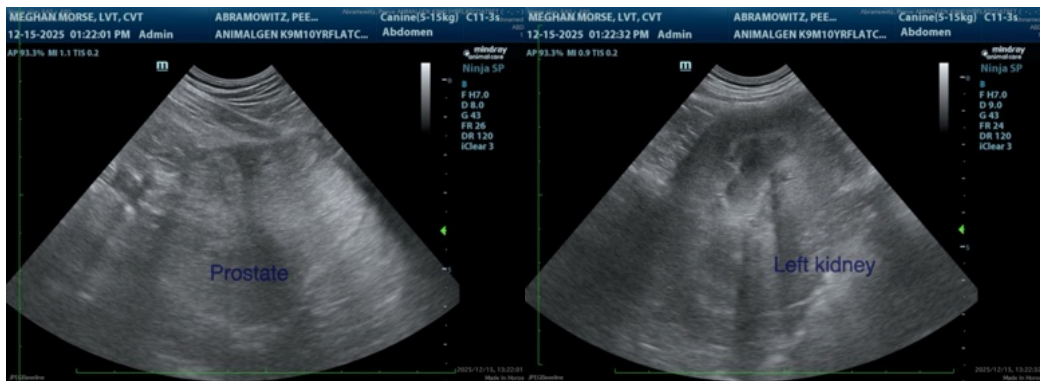
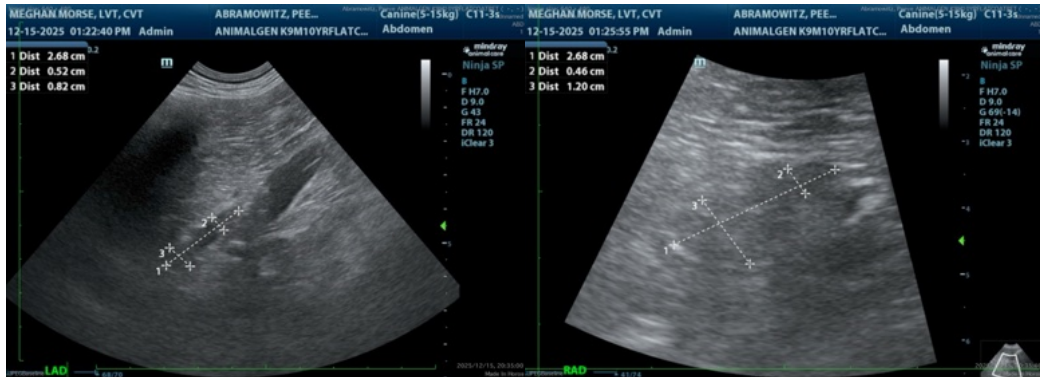
Dr. DiGiuseppi

INVOICE

69294

DATE

12/15/25





PATIENT

Peeve Abramowitz

SPECIES

Canine

BREED

Flat Coated Retriever

SEX

Intact male

AGE

10 years

WEIGHT

lbs

INTERPRETED BY

Remo Lobetti, BVSc,
MMedVet (Med),
PhD, Dipl. ECVIM

IMAGING PERFORMED BY

Meghan Morse, LVT,
CVT

HOSPITAL NAME

Animal General
Hudson

REFERRING VET

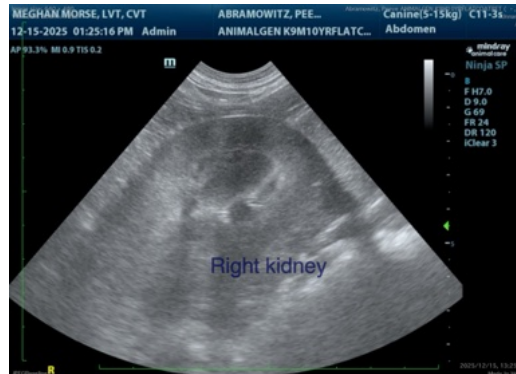Dr. DiGiuseppi

INVOICE

69294

DATE

12/15/25



The information and recommendations provided are based on the images presented by the referring veterinarian/sonographer. No evaluation can be communicated regarding pathology that was not visible in the image/video clips provided.

Thank you for this referral. If the clinical or image interpretation does not parallel your findings or if I can be of any further assistance please contact me.

Remo Lobetti, BVSc, MMedVet (Med), PhD, Dipl. ECVIM (Internal Medicine)

info@sonopath.com