



PATIENT

Cali Brecka

SPECIES

Feline

BREED

Domestic Shorthair

SEX

Spayed female

AGE

9 years

WEIGHT

8.9 lbs

INTERPRETED BY

Remo Lobetti, BVSc,
MMedVet (Med),
PhD, Dipl. ECVIM

IMAGING PERFORMED BY

Kerri Becker

HOSPITAL NAME

Roxbury AH

REFERRING VET

Dr. Elia

INVOICE

69579

DATE

12/11/25

PRESENTING CLINICAL SIGNS

History: Abdominal mass concern found on xray.

ULTRASONOGRAPHIC EXAMINATION OF THE ABDOMEN

Urinary System

The urinary bladder is full with a normal thickness and smooth appearance of the wall. Normal anechoic urine with no sediment or uroliths evident.

Normal appearance of the trigone area, proximal urethra, and iliac blood vessels.

Normal appearance and size of the iliac lymph nodes. Ureters not visualized, which can be considered a normal finding.

Normal renal size (left measured 3.7 cm, right measured 4.0 cm), architecture, echogenic appearance, cortico-medullary differentiation, which maintains a 1:3 cortex to medulla ratio, pelvis, and capsule. No infarcts, mineralization or renoliths evident.

Adrenal Glands

Normal shape, echogenic appearance, size, position, and appearance of the visible peri-adrenal vasculature. Left adrenal gland measured 0.31 cm in width. The right adrenal gland measured 0.4 cm in width.

Spleen

The spleen was enlarged and measured 1.2 cm in width with an irregular shape, scalloped appearance of the capsule and a hyperechogenic appearance of the parenchyma.

Liver

Normal size with a diffuse, increased echogenic and coarse appearance, normal portal markings, and regular curvilinear capsule. No nodules or masses evident. Normal appearance of the hepatic and portal vasculature.

Gallbladder

The gallbladder is small containing normal anechoic bile. Normal thickness and echogenic appearance of the wall. Normal size and appearance of the cystic and common bile duct.



PATIENT

Cali Brecka

SPECIES

Feline

BREED

Domestic Shorthair

SEX

Spayed female

AGE

9 years

WEIGHT

8.9 lbs

INTERPRETED BY

Remo Lobetti, BVSc,
MMedVet (Med),
PhD, Dipl. ECVIM

IMAGING PERFORMED BY

Kerri Becker

HOSPITAL NAME

Roxbury AH

REFERRING VET

Dr. Elia

INVOICE

69579

DATE

12/11/25

Gastrointestinal

Normal appearance of the stomach, duodenum, small intestine, ileo-cecal junction, and colon with no loss of layering, 1:3 muscularis to mucosa ratio, normal wall thickness and peristaltic activity, and no distension of the lumen. A small amount of fluid is present in the stomach.

Pancreas

The visible sections of the pancreas are of normal size and echogenic appearance with a regular capsule. Normal echogenic appearance of the mesentery and fat surrounding the pancreas.

Free Abdomen

Normal mesenteric lymph nodes.

No ascites evident.

Irregular, hypoechogenic mass in the midabdomen measuring 2.4 x 4.2 cm in size showing a vascular pattern, but with no obvious organ involvement.

ULTRASONOGRAPHIC FINDINGS

- Abdominal mass.
- Splenomegaly.
- Hepatopathy.

INTERPRETATION OF THE FINDINGS & FURTHER RECOMMENDATIONS

With the appearance of the spleen and the abdominal mass the most likely etiology would be neoplasia such as lymphoma. Granulomatous disease would be a less likely differential diagnosis. The most likely etiology for the hepatopathy would be reactive hyperplasia with infiltrative neoplasia and hepatitis a less likely differential diagnosis.

Further assessment would be FNA cytology of the mass and the spleen.

Specific therapy would be dependent on an etiological diagnosis.



PATIENT

Cali Brecka

SPECIES

Feline

BREED

Domestic Shorthair

SEX

Spayed female

AGE

9 years

WEIGHT

8.9 lbs

INTERPRETED BY

Remo Lobetti, BVSc,
 MMedVet (Med),
 PhD, Dipl. ECVIM

IMAGING PERFORMED BY

Kerri Becker

HOSPITAL NAME

Roxbury AH

REFERRING VET

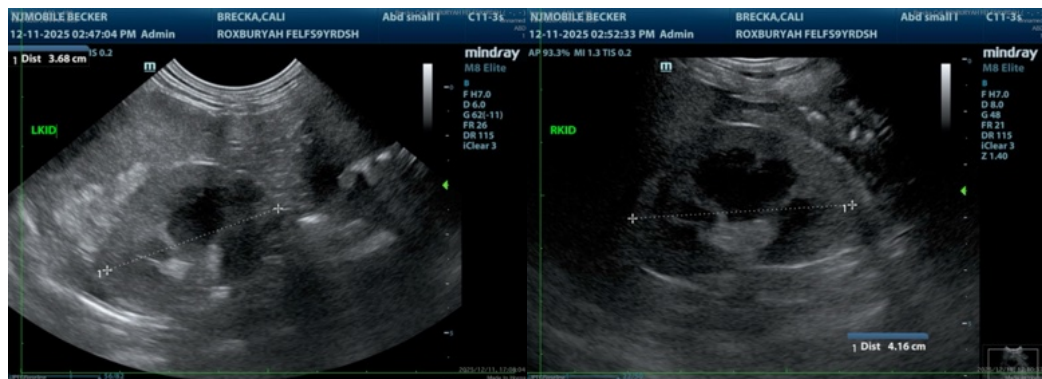
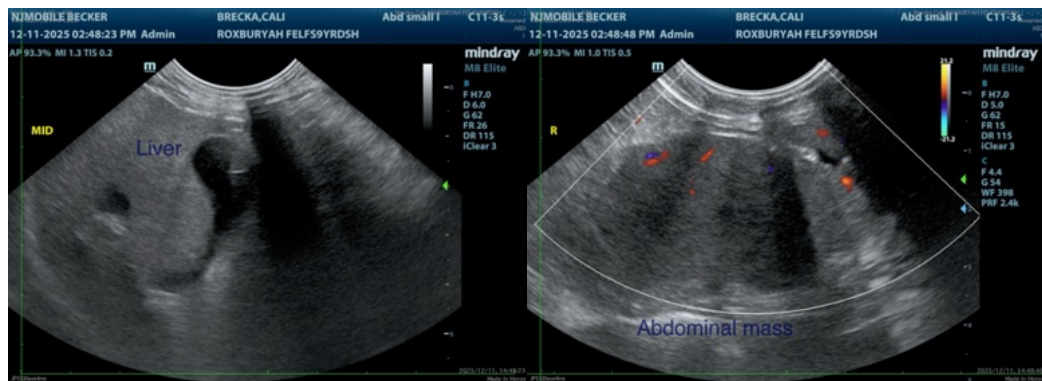
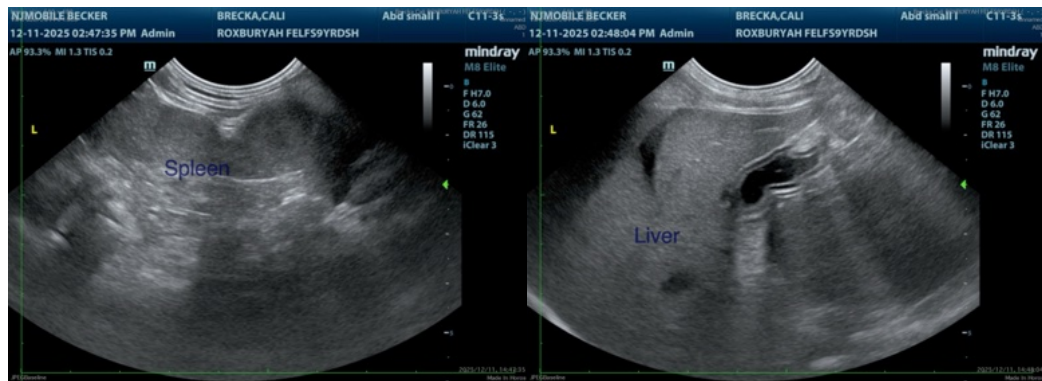
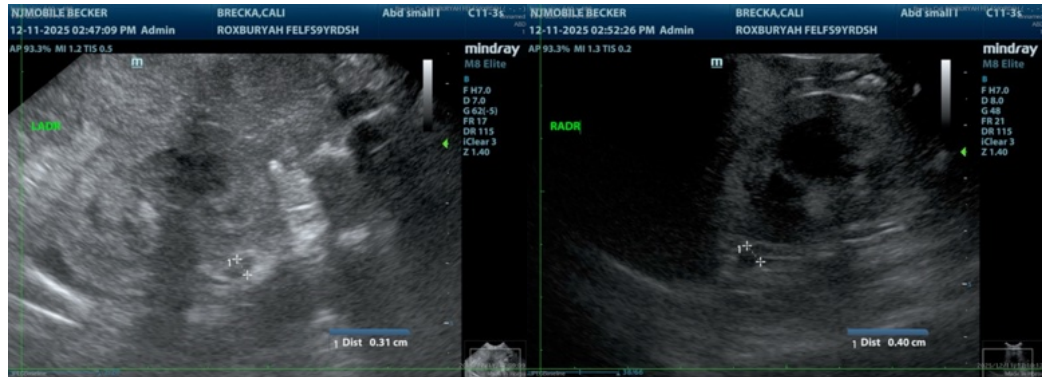
Dr. Elia

INVOICE

69579

DATE

12/11/25





PATIENT

Cali Brecka

The information and recommendations provided are based on the images presented by the referring veterinarian/sonographer. No evaluation can be communicated regarding pathology that was not visible in the image/video clips provided.

SPECIES

Feline

Thank you for this referral. If the clinical or image interpretation does not parallel your findings or if I can be of any further assistance please contact me.

Remo Lobetti, BVSc, MMedVet (Med), PhD, Dipl. ECVIM (Internal Medicine)

BREED

info@sonopath.com

Domestic Shorthair

SEX

Spayed female

AGE

9 years

WEIGHT

8.9 lbs

INTERPRETED BY

Remo Lobetti, BVSc,
MMedVet (Med),
PhD, Dipl. ECVIM

IMAGING PERFORMED BY

Kerri Becker

HOSPITAL NAME

Roxbury AH

REFERRING VET

Dr. Elia

INVOICE

69579

DATE

12/11/25