



PATIENT

Luna Rosado

SPECIES

Canine

BREED

Golden Retriever

SEX

Spayed female

AGE

8 years

WEIGHT

63.2 lbs

INTERPRETED BY

Remo Lobetti, BVSc,
MMedVet (Med), PhD,
Dipl. ECVIM (Internal
Medicine)

**IMAGING
PERFORMED BY**

Kerri Becker

HOSPITAL NAME

Animal Paradise
Hospital

REFERRING VET

Dr. Elshafie

INVOICE

69485

DATE

12/10/25

PRESENTING CLINICAL SIGNS

History: Assess spleen (follow up from last us) 9/24/25- appearance of spleen is similar to that of prev. US the most likely etiology for focal splenic changes would be splenitis, active inflammation, or neoplasia less likely ddx

ULTRASONOGRAPHIC EXAMINATION OF THE ABDOMEN

Urinary System

The urinary bladder is small with a normal thickness and smooth appearance of the wall. Normal anechoic urine with no sediment or uroliths evident.

Normal appearance of the trigone area, proximal urethra, and iliac blood vessels.

Normal appearance and size of the iliac lymph nodes. Ureters not visualized, which can be considered a normal finding.

Normal renal size (left measured 5.8 cm, right measured 6.9 cm), architecture, echogenic appearance, cortico-medullary differentiation, which maintains a 1:3 cortex to medulla ratio, pelvis, and capsule. No infarcts, mineralization or renoliths evident. Normal color flow pattern is evident in both kidneys.

Adrenal Glands

Normal shape, echogenic appearance, size, position, and appearance of the visible peri-adrenal vasculature. Left adrenal gland measured 2.23 cm in length x 0.44 cm and 0.38 cm in width. The right adrenal gland measured 2.45 cm in length x 0.71 cm in width.

Spleen

Normal size and echogenic appearance. Smooth homogenous parenchyma and regular curvilinear capsule. Normal volume of the splenic vasculature without any overt congestion or thrombosis evident. Incidental myelolipomas are present. No inflammatory, neoplastic, infarction, or infiltrative changes evident. The spleen measured 2.5 cm in width.

Liver

Normal size, echogenic appearance, portal markings, and regular curvilinear capsule. No nodules or masses evident. Normal appearance of the hepatic and portal vasculature.

Gallbladder

The gallbladder is full containing normal anechoic bile. Normal thickness and echogenic appearance of the wall. Normal size and appearance of the cystic and common bile duct.



PATIENT

Luna Rosado

SPECIES

Canine

BREED

Golden Retriever

SEX

Spayed female

AGE

8 years

WEIGHT

63.2 lbs

INTERPRETED BY

Remo Lobetti, BVSc,
MMedVet (Med), PhD,
Dipl. ECVIM (Internal
Medicine)

IMAGING PERFORMED BY

Kerri Becker

HOSPITAL NAME

Animal Paradise
Hospital

REFERRING VET

Dr. Elshafie

INVOICE

69485

DATE

12/10/25

Gastrointestinal

Normal appearance of the stomach, duodenum, small intestine, ileo-cecal junction, and colon with no loss of layering, 1:3 muscularis to mucosa ratio, normal wall thickness and peristaltic activity, and no distension of the lumen.

Pancreas

The visible sections of the pancreas are of normal size and echogenic appearance with a regular capsule. Normal echogenic appearance of the mesentery and fat surrounding the pancreas.

Free Abdomen

Normal mesenteric lymph nodes.

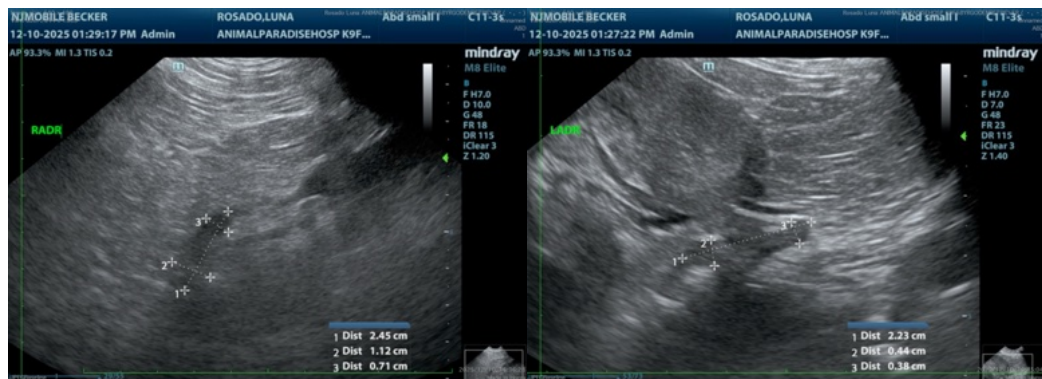
No ascites evident.

ULTRASONOGRAPHIC FINDINGS

- Normal ultrasound examination of the abdomen.

INTERPRETATION OF THE FINDINGS & FURTHER RECOMMENDATIONS

In comparison with the previous ultrasounds, the focal splenic pathology has now resolved.





PATIENT

Luna Rosado

SPECIES

Canine

BREED

Golden Retriever

SEX

Spayed female

AGE

8 years

WEIGHT

63.2 lbs

INTERPRETED BY

Remo Lobetti, BVSc, MMedVet (Med), PhD, Dipl. ECVIM (Internal Medicine)

IMAGING PERFORMED BY

Kerri Becker

HOSPITAL NAME

Animal Paradise Hospital

REFERRING VET

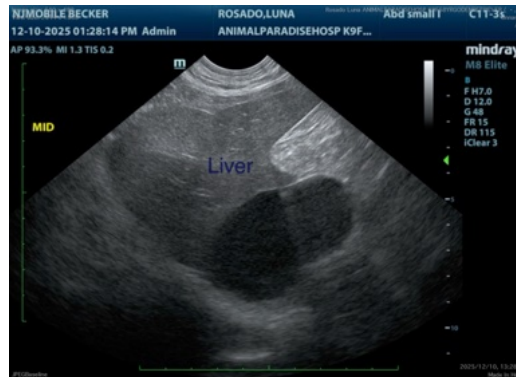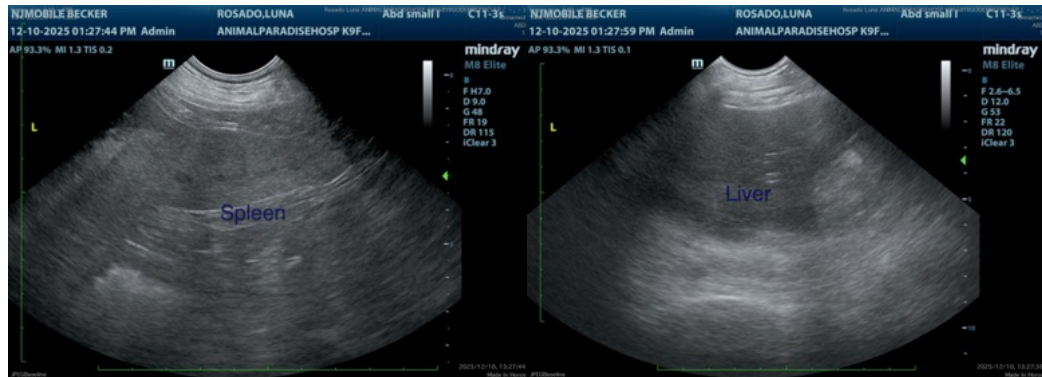
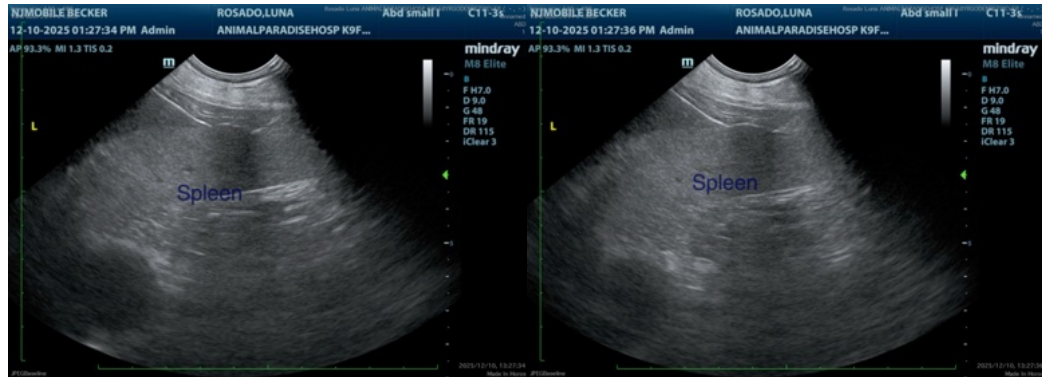
Dr. Elshafie

INVOICE

69485

DATE

12/10/25



The information and recommendations provided are based on the images presented by the referring veterinarian/sonographer. No evaluation can be communicated regarding pathology that was not visible in the image/video clips provided.

Thank you for this referral. If the clinical or image interpretation does not parallel your findings or if I can be of any further assistance please contact me.

Remo Lobetti, BVSc, MMedVet (Med), PhD, Dipl. ECVIM (Internal Medicine)

info@sonopath.com