



## PATIENT

Binx Brower

## SPECIES

Feline

## BREED

Domestic Shorthair

## SEX

Spayed female

## AGE

11 years

## WEIGHT

15.9 lbs

## INTERPRETED BY

Remo Lobetti, BVSc,  
MMedVet (Med),  
PhD, Dipl. ECVIM

## IMAGING PERFORMED BY

Shari Reffi, CVT

## HOSPITAL NAME

Farview Animal Clinic

## REFERRING VET

Dr. Mosaad

## INVOICE

69181

## DATE

12/1/25

## PRESENTING CLINICAL SIGNS

History: Vomiting, lethargic. Radiographs unremarkable. Current Medications: Mirataz; Cerenia 16mg (1 tab sid)

ALT 1887; Amyl 1114; TBil 1.2; Gluc 196; K+ 3.6; MCV 55+; MCH 183 +; MPV 15.6+; Lym 0.72-

## ULTRASONOGRAPHIC EXAMINATION OF THE ABDOMEN

### *Urinary System*

The urinary bladder is full with a normal thickness and smooth appearance of the wall. Normal anechoic urine with no sediment or uroliths evident.

Normal appearance of the trigone area, proximal urethra, and iliac blood vessels.

Normal appearance and size of the iliac lymph nodes. Ureters not visualized, which can be considered a normal finding.

Normal renal size (left measured 3.7 cm, right measured 4.0 cm), architecture, echogenic appearance, cortico-medullary differentiation, which maintains a 1:3 cortex to medulla ratio, pelvis, and capsule. No infarcts, mineralization or renoliths evident. Normal color flow pattern is evident in both kidneys.

### *Adrenal Glands*

Normal shape, echogenic appearance, size, position, and appearance of the visible peri-adrenal vasculature. Left adrenal gland measured 0.33 cm in width. The right adrenal gland measured 0.54 cm in width.

### *Spleen*

Normal size and echogenic appearance. Smooth homogenous parenchyma and regular curvilinear capsule. Normal volume of the splenic vasculature without any overt congestion or thrombosis evident. No inflammatory, neoplastic, infarction, or infiltrative changes evident. The spleen measured 0.8 cm in width.

### *Liver*

Normal size, echogenic appearance, portal markings, and regular curvilinear capsule. No nodules or masses evident. Normal appearance of the hepatic and portal vasculature.

### *Gallbladder*

The gallbladder is full containing normal anechoic bile. Normal thickness and echogenic appearance of the wall. Normal size and appearance of the cystic and common bile duct.



**PATIENT**

Binx Brower

**SPECIES**

Feline

**BREED**

Domestic Shorthair

**SEX**

Spayed female

**AGE**

11 years

**WEIGHT**

15.9 lbs

**INTERPRETED BY**

Remo Lobetti, BVSc,  
MMedVet (Med),  
PhD, Dipl. ECVIM

**IMAGING PERFORMED BY**

Shari Reffi, CVT

**HOSPITAL NAME**

Farview Animal Clinic

**REFERRING VET**

Dr. Mosaad

**INVOICE**

69181

**DATE**

12/1/25

**Gastrointestinal**

Normal appearance of the stomach, duodenum, small intestine, ileo-cecal junction, and colon with no loss of layering, 1:3 muscularis to mucosa ratio, normal wall thickness and peristaltic activity, and no distension of the lumen.

**Pancreas**

The pancreas is enlarged (right pancreas measured 1.4 cm in width) with a hypoechogenic appearance and irregular capsule. Hyperechogenic appearance of the mesentery and fat surrounding the pancreas.

**Free Abdomen**

Normal mesenteric lymph nodes.

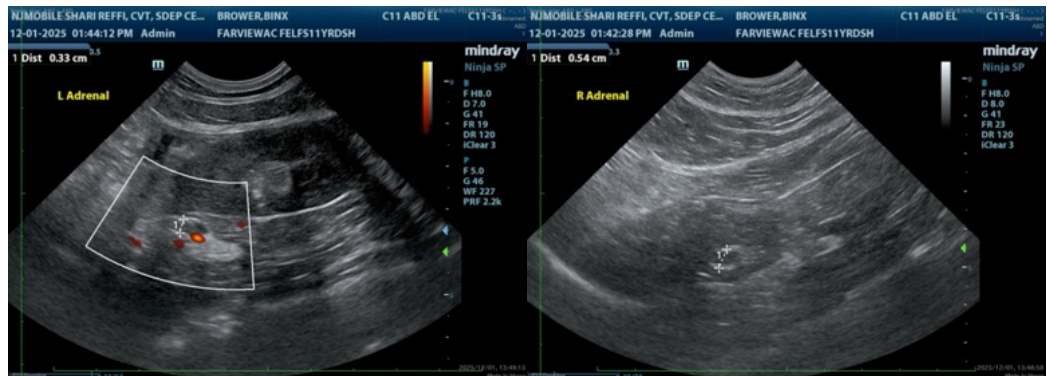
No ascites evident.

**ULTRASONOGRAPHIC FINDINGS**

- Pancreatitis.

**INTERPRETATION OF THE FINDINGS & FURTHER RECOMMENDATIONS**

Further assessment that can be considered would be FPL/PSL assay. Management of the pancreatitis would be fluid therapy, potassium supplementation, antiemetics, analgesics and feeding small frequent meals of a low-fat intestinal type diet.





**PATIENT**

Binx Brower

**SPECIES**

Feline

**BREED**

Domestic Shorthair

**SEX**

Spayed female

**AGE**

11 years

**WEIGHT**

15.9 lbs

**INTERPRETED BY**

Remo Lobetti, BVSc,  
MMedVet (Med),  
PhD, Dipl. ECVIM

**IMAGING  
PERFORMED BY**

Shari Reffi, CVT

**HOSPITAL NAME**

Farview Animal Clinic

**REFERRING VET**

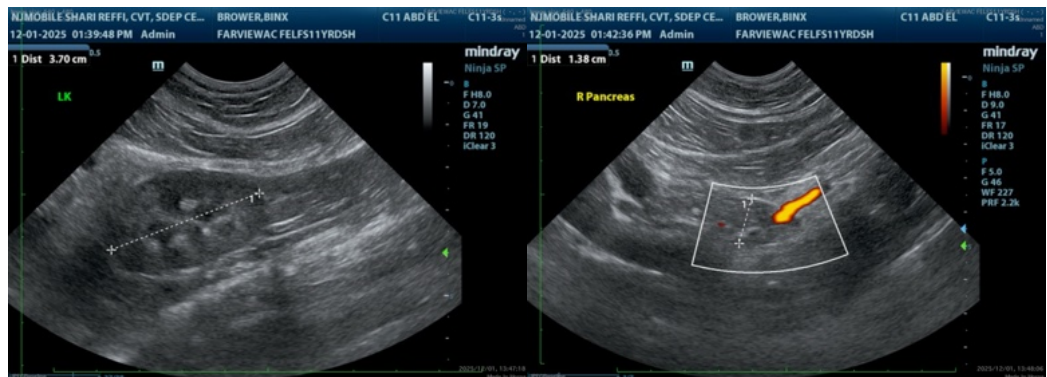
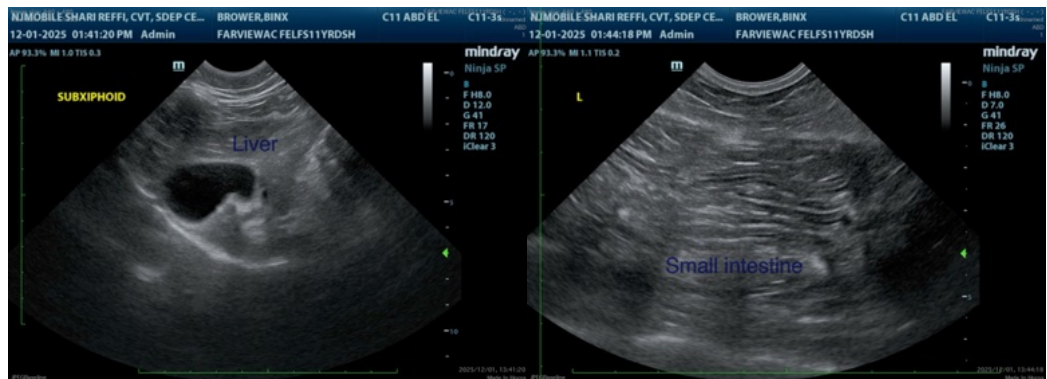
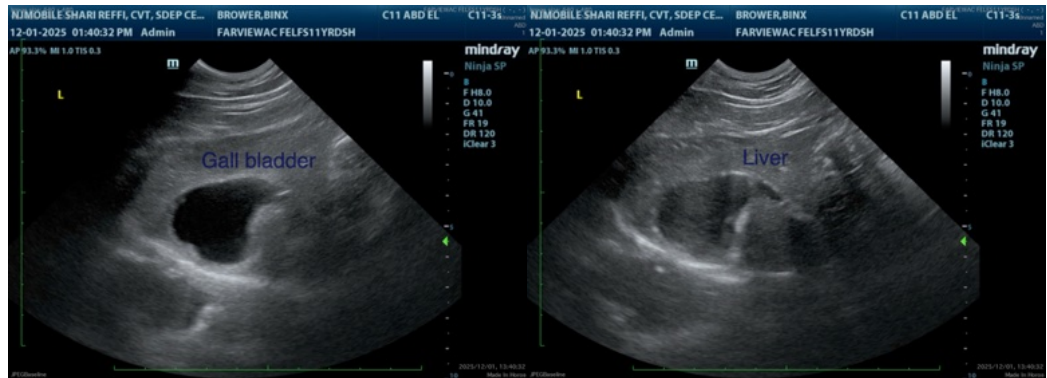
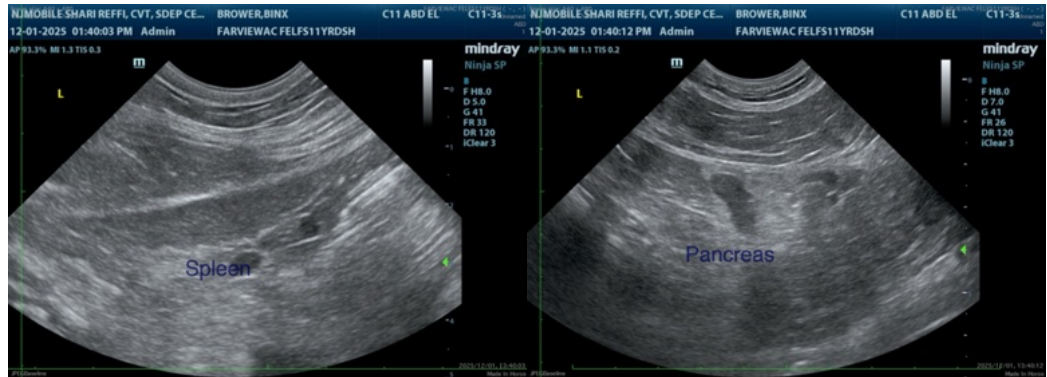
Dr. Mosaad

**INVOICE**

69181

**DATE**

12/1/25





## PATIENT

Binx Brower

## SPECIES

Feline

## BREED

Domestic Shorthair

## SEX

Spayed female

## AGE

11 years

## WEIGHT

15.9 lbs

## INTERPRETED BY

Remo Lobetti, BVSc,  
MMedVet (Med),  
PhD, Dipl. ECVIM

## IMAGING PERFORMED BY

Shari Reffi, CVT

## HOSPITAL NAME

Farview Animal Clinic

## REFERRING VET

Dr. Mosaad

## INVOICE

69181

## DATE

12/1/25

The information and recommendations provided are based on the images presented by the referring veterinarian/sonographer. No evaluation can be communicated regarding pathology that was not visible in the image/video clips provided.

Thank you for this referral. If the clinical or image interpretation does not parallel your findings or if I can be of any further assistance please contact me.

Remo Lobetti, BVSc, MMedVet (Med), PhD, Dipl. ECVIM (Internal Medicine)

[info@sonopath.com](mailto:info@sonopath.com)