

**PATIENT**

Rocky Pichardo

**SPECIES**

Canine

**BREED**

Yorkie Mix

**SEX**

Neutered male

**AGE**

9 years

**WEIGHT**

13.7 lbs

**INTERPRETED BY**

Remo Lobetti, BVSc,  
MMedVet (Med),  
PhD, Dipl. ECVIM

**IMAGING PERFORMED BY**

Kerri Becker

**HOSPITAL NAME**

Newbridge Vets

**REFERRING VET**

Dr. Glennon

**INVOICE**

68338

**DATE**

11/5/25

**PRESENTING CLINICAL SIGNS**

History: R/o Cushing dz etc. Pendulous abdomen, ravenous appetite, wt gain, see bloodwork- doing ACTH test today. Meds- thyroid tabs.  
Abnormal PE/Chem/CBC/UA Results: Retic-163 Neut-13376 EOS-46 Chlor-98 AG-35 TP-7.6 ALT-206 ALP-212 GGT-47 Chol-362

**ULTRASONOGRAPHIC EXAMINATION OF THE ABDOMEN**

**Urinary System**

The urinary bladder is small with a normal thickness and smooth appearance of the wall. A small amount of floating, hyperechogenic sediment.

Normal appearance of the trigone area, proximal urethra, and iliac blood vessels.

Normal appearance and size of the iliac lymph nodes. Ureters not visualized, which can be considered a normal finding.

Normal renal size (left measured 4.1 cm, right measured 4.4 cm), architecture, echogenic appearance, cortico-medullary differentiation, which maintains a 1:3 cortex to medulla ratio, pelvis, and capsule. No infarcts, mineralization or renoliths evident.

The prostate is small and hypoechogenic.

**Adrenal Glands**

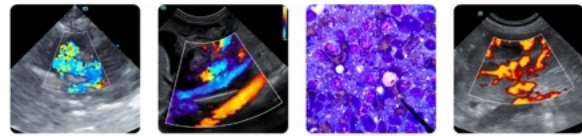
Normal shape, echogenic appearance, size, position, and appearance of the visible peri-adrenal vasculature. Left adrenal gland measured 1.46 cm in length x 0.47 cm and 0.48 cm in width. The right adrenal gland measured 1.56 cm in length x 0.5 cm and 0.27 cm in width.

**Spleen**

Normal size and echogenic appearance. Smooth homogenous parenchyma and regular curvilinear capsule. Normal volume of the splenic vasculature without any overt congestion or thrombosis evident. No inflammatory, neoplastic, infarction, or infiltrative changes evident. The spleen measured 1.0 cm in width.

**Liver**

Normal size with a diffuse increased echogenic and coarse appearance, normal portal markings, and regular curvilinear capsule. No nodules or masses evident. Normal appearance of the hepatic and portal vasculature.



**PATIENT**

Rocky Pichardo

**SPECIES**

Canine

**BREED**

Yorkie Mix

**SEX**

Neutered male

**AGE**

9 years

**WEIGHT**

13.7 lbs

**INTERPRETED BY**

Remo Lobetti, BVSc,  
MMedVet (Med),  
PhD, Dipl. ECVIM

**IMAGING PERFORMED BY**

Kerri Becker

**HOSPITAL NAME**

Newbridge Vets

**REFERRING VET**

Dr. Glennon

**INVOICE**

68338

**DATE**

11/5/25

***Gallbladder***

The gallbladder is full containing normal anechoic bile. Normal thickness and echogenic appearance of the wall. Normal size and appearance of the cystic and common bile duct.

***Gastrointestinal***

Normal appearance of the stomach, duodenum, small intestine, ileo-cecal junction, and colon with no loss of layering, 1:3 muscularis to mucosa ratio, normal wall thickness and peristaltic activity, and no distension of the lumen.

***Pancreas***

The visible sections of the pancreas are of normal size and echogenic appearance with a regular capsule. Normal echogenic appearance of the mesentery and fat surrounding the pancreas.

***Free Abdomen***

Normal mesenteric lymph nodes.

No ascites evident.

**ULTRASONOGRAPHIC FINDINGS**

- Hepatopathy.
- Urinary bladder sediment.

**INTERPRETATION OF THE FINDINGS & FURTHER RECOMMENDATIONS**

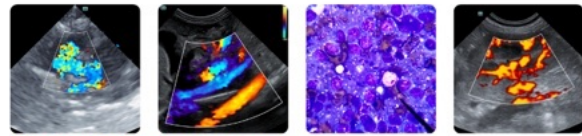
The likely etiologies for the hepatopathy would be reactive hyperplasia, early nodular hyperplasia, vacuolar and metabolic with hepatitis and infiltrative neoplasia a highly unlikely differential diagnosis.

The most likely etiology for the urinary bladder sediment would be incidental debris with crystalluria and bacterial cystitis a less likely differential diagnosis.

If the pending ACTH stimulation test comes back negative for Cushing's disease then further assessment of the hepatopathy would be FNA cytology. However, a tru cut or wedge biopsy may be required for a final etiological diagnosis.

Urinalysis and urine culture would also be considered.

Specific therapy would be dependent on an etiological diagnosis.



**PATIENT**

Rocky Pichardo

**SPECIES**

Canine

**BREED**

Yorkie Mix

**SEX**

Neutered male

**AGE**

9 years

**WEIGHT**

13.7 lbs

**INTERPRETED BY**

Remo Lobetti, BVSc,  
 MMedVet (Med),  
 PhD, Dipl. ECVIM

**IMAGING PERFORMED BY**

Kerri Becker

**HOSPITAL NAME**

Newbridge Vets

**REFERRING VET**

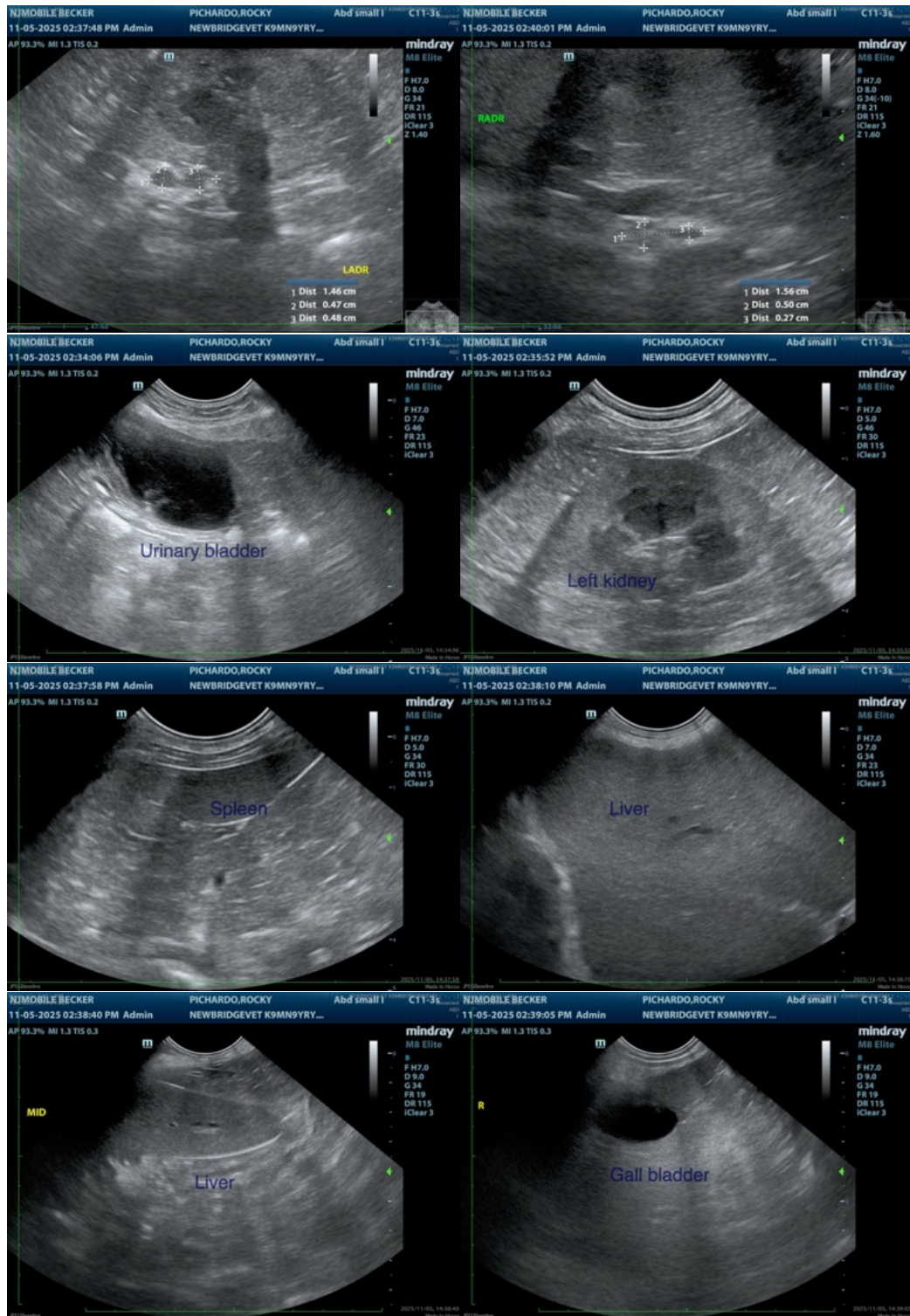
Dr. Glennon

**INVOICE**

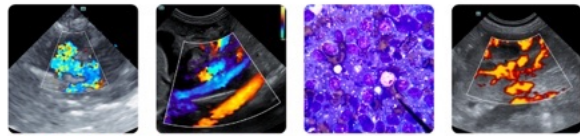
68338

**DATE**

11/5/25



The information and recommendations provided are based on the images presented by the referring veterinarian/sonographer. No evaluation can be communicated regarding pathology



**PATIENT**

Rocky Pichardo

**SPECIES**

Canine

**BREED**

Yorkie Mix

**SEX**

Neutered male

**AGE**

9 years

**WEIGHT**

13.7 lbs

**INTERPRETED BY**

Remo Lobetti, BVSc,  
MMedVet (Med),  
PhD, Dipl. ECVIM

**IMAGING  
PERFORMED BY**

Kerri Becker

**HOSPITAL NAME**

Newbridge Vets

**REFERRING VET**

Dr. Glennon

**INVOICE**

68338

**DATE**

11/5/25

**that was not visible in the image/video clips provided.**

Thank you for this referral. If the clinical or image interpretation does not parallel your findings or if I can be of any further assistance please contact me.

**Remo Lobetti, BVSc, MMedVet (Med), PhD, Dipl. ECVIM (Internal Medicine)**

[info@sonopath.com](mailto:info@sonopath.com)