



PATIENT

Rambo Todoric

SPECIES

Canine

BREED

German Shepherd

SEX

Neutered male

AGE

9 years

WEIGHT

77.3 lbs

INTERPRETED BY

Remo Lobetti, BVSc,
 MMedVet (Med),
 PhD, Dipl. ECVIM

IMAGING PERFORMED BY

Kerri Becker

HOSPITAL NAME

ACCNJ Riverdale

REFERRING VET

Dr. Andalaft

INVOICE

69013

DATE

11/25/25

PRESENTING CLINICAL SIGNS

History: Attempt to find source of anemia - mass expected. Chronic vomiting, wt loss, anemic
 Abnormal PE/Chem/CBC/UA Results: AST-13 BUNcreat-34 Amyl-1945 PSL-291 HGB-5 HCT-21
 MCV-41 MCH-9.9 MCHC-24 PC-735 Retic-4.6 ABSretic-230000

ULTRASONOGRAPHIC EXAMINATION OF THE ABDOMEN

Urinary System

The urinary bladder is full with a normal thickness and smooth appearance of the wall. A small amount of floating, hyperechogenic sediment.

Normal appearance of the trigone area, proximal urethra, and iliac blood vessels.

Normal appearance and size of the iliac lymph nodes. Ureters not visualized, which can be considered a normal finding.

Normal renal size (left measured 6.2 cm, right measured 7.2 cm), architecture, echogenic appearance, cortico-medullary differentiation, which maintains a 1:3 cortex to medulla ratio, pelvis, and capsule. No infarcts, mineralization or renoliths evident. Normal color flow pattern is evident in both kidneys.

The prostate was not visualized.

Adrenal Glands

The adrenal glands are not visualized.

Spleen

Normal size and echogenic appearance. Smooth homogenous parenchyma and regular curvilinear capsule. Normal volume of the splenic vasculature without any overt congestion or thrombosis evident. No inflammatory, neoplastic, infarction, or infiltrative changes evident. The spleen measured 1.6 cm in width.

Liver

Normal size, echogenic appearance, portal markings, and regular curvilinear capsule. No nodules or masses evident. Normal appearance of the hepatic and portal vasculature.

Gallbladder

The gallbladder is full containing normal anechoic bile. Normal thickness and echogenic appearance of the wall. Normal size and appearance of the cystic and common bile duct.



PATIENT

Rambo Todoric

SPECIES

Canine

BREED

German Shepherd

SEX

Neutered male

AGE

9 years

WEIGHT

77.3 lbs

INTERPRETED BY

Remo Lobetti, BVSc,
MMedVet (Med),
PhD, Dipl. ECVIM

IMAGING PERFORMED BY

Kerri Becker

HOSPITAL NAME

ACCNJ Riverdale

REFERRING VET

Dr. Andalaft

INVOICE

69013

DATE

11/25/25

Gastrointestinal

Normal appearance of the stomach, duodenum, small intestine, ileo-cecal junction, and colon with no loss of layering, 1:3 muscularis to mucosa ratio, normal wall thickness and peristaltic activity, and no distension of the lumen.

Pancreas

The visible sections of the pancreas are of normal size and echogenic appearance with a regular capsule. Normal echogenic appearance of the mesentery and fat surrounding the pancreas.

Free Abdomen

Normal mesenteric lymph nodes.

A large amount of cellular ascites evident.

Hyperechogenic appearance of the mesentery. Few, small, hypoechoic nodules within the mesentery measuring 1.0 cm in size.

ULTRASONOGRAPHIC FINDINGS

- Mesenteric inflammation.
- Ascites.
- Mesenteric nodules.
- Gallbladder sediment.

INTERPRETATION OF THE FINDINGS & FURTHER RECOMMENDATIONS

With the breed of animal anemia with cellular ascites and the mesenteric nodules, the most likely etiology would be hemangiosarcoma with granulomatous disease a less likely differential diagnosis.

Further assessment would be three view thoracic radiographs, echocardiography to evaluate the right atrium and right auricle, analysis of the ascitic fluid and if possible FNA cytology of the mesentery and the mesenteric nodules.

Laparotomy could be considered as it could be both diagnostic and therapeutic with further specific therapy dependent on an etiological diagnosis.



PATIENT

Rambo Todoric

SPECIES

Canine

BREED

German Shepherd

SEX

Neutered male

AGE

9 years

WEIGHT

77.3 lbs

INTERPRETED BY

Remo Lobetti, BVSc,
 MMedVet (Med),
 PhD, Dipl. ECVIM

IMAGING PERFORMED BY

Kerri Becker

HOSPITAL NAME

ACCNJ Riverdale

REFERRING VET

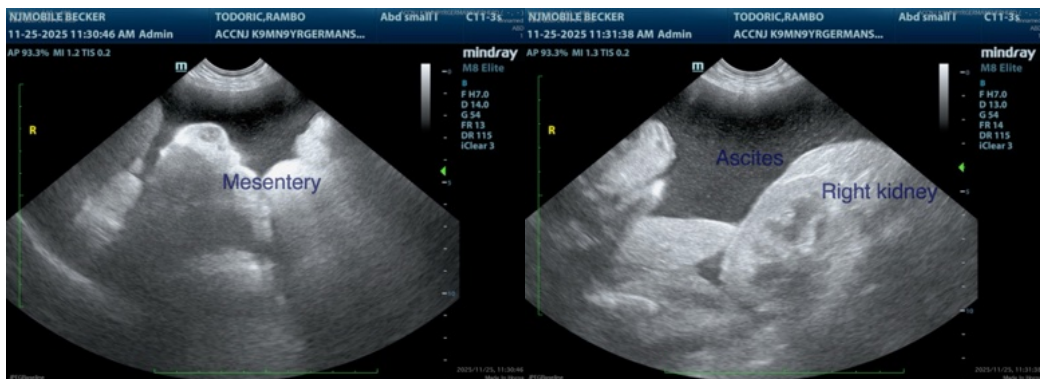
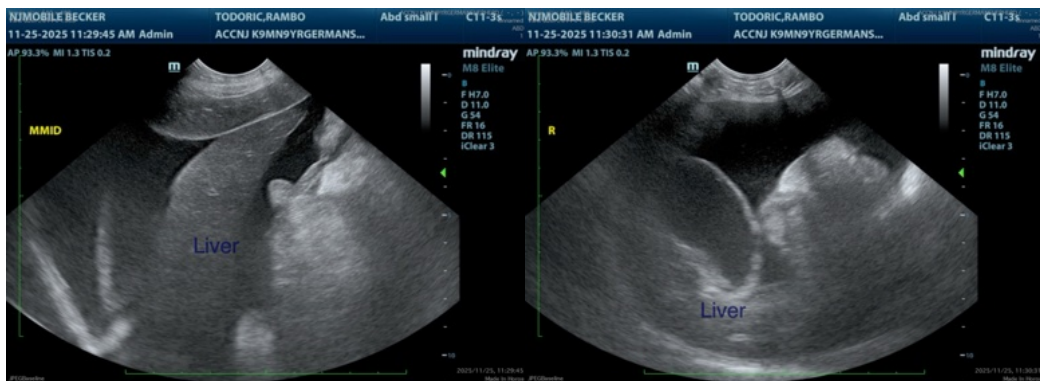
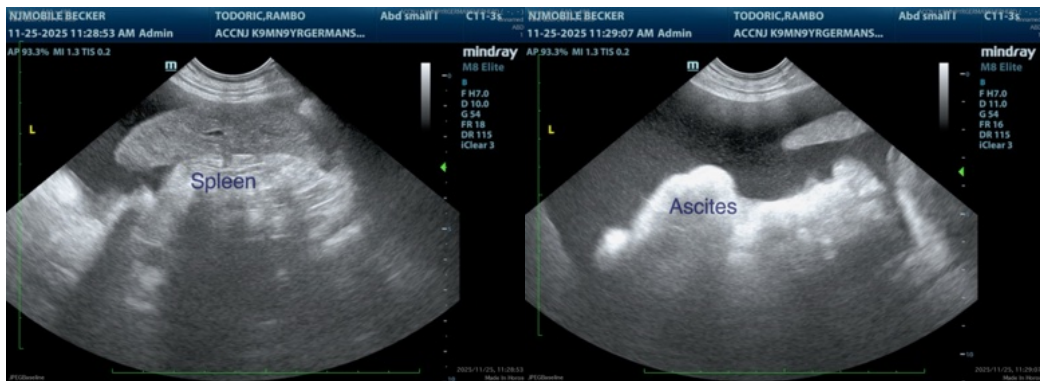
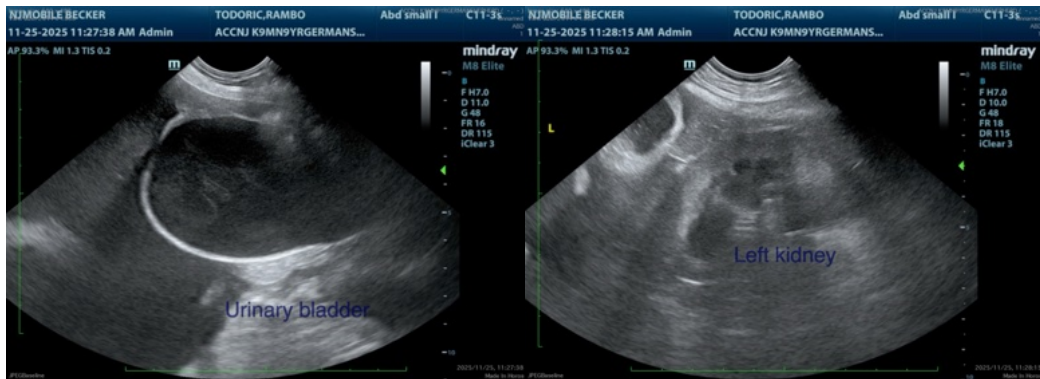
Dr. Andalaft

INVOICE

69013

DATE

11/25/25





PATIENT

Rambo Todoric

SPECIES

Canine

BREED

German Shepherd

SEX

Neutered male

AGE

9 years

WEIGHT

77.3 lbs

INTERPRETED BY

Remo Lobetti, BVSc,
MMedVet (Med),
PhD, Dipl. ECVIM

IMAGING PERFORMED BY

Kerri Becker

HOSPITAL NAME

ACCNJ Riverdale

REFERRING VET

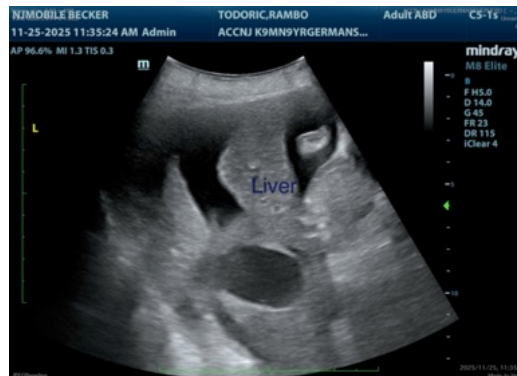Dr. Andalaft

INVOICE

69013

DATE

11/25/25



The information and recommendations provided are based on the images presented by the referring veterinarian/sonographer. No evaluation can be communicated regarding pathology that was not visible in the image/video clips provided.

Thank you for this referral. If the clinical or image interpretation does not parallel your findings or if I can be of any further assistance please contact me.

Remo Lobetti, BVSc, MMedVet (Med), PhD, Dipl. ECVIM (Internal Medicine)

info@sonopath.com