



**PATIENT**

Ducky Hahn

**SPECIES**

Canine

**BREED**

Mix

**SEX**

Neutered male

**AGE**

4 years

**WEIGHT**

40 lbs

**INTERPRETED BY**

Remo Lobetti, BVSc,  
MMedVet (Med),  
PhD, Dipl. ECVIM

**IMAGING  
PERFORMED BY**

Kerri Becker

**HOSPITAL NAME**

Companion VH of  
Wayne

**REFERRING VET**

Dr. Spitz

**INVOICE**

68933

**DATE**

11/24/25

**PRESENTING CLINICAL SIGNS**

History: Stranguria/ pollakiuria, asking to go out more, accidents.  
Abnormal PE/Chem/CBC/UA Results: BW Normal. Neg- UA culture

**ULTRASONOGRAPHIC EXAMINATION OF THE ABDOMEN**

**Urinary System**

The urinary bladder is small with a normal thickness and smooth appearance of the wall. A scant amount of floating, hyperechogenic sediment.

Normal appearance of the trigone area, proximal urethra, and iliac blood vessels.

Normal appearance and size of the iliac lymph nodes. Ureters not visualized, which can be considered a normal finding.

Normal renal size (left measured 5.6 cm, right measured 5.7 cm), architecture, echogenic appearance, cortico-medullary differentiation, which maintains a 1:3 cortex to medulla ratio, pelvis, and capsule. No infarcts, mineralization or renoliths evident. Normal color flow pattern is evident in both kidneys.

The prostate is small and hypoechogenic measuring 0.7 cm in width.

**Adrenal Glands**

Normal shape, echogenic appearance, size, position, and appearance of the visible peri-adrenal vasculature. Left adrenal gland measured 1.86 cm in length x 0.58 cm and 0.53 cm in width. The right adrenal gland measured 1.26 cm in length x 0.66 cm and 0.33 cm in width.

**Spleen**

Normal size and echogenic appearance. Smooth homogenous parenchyma and regular curvilinear capsule. Normal volume of the splenic vasculature without any overt congestion or thrombosis evident. No inflammatory, neoplastic, infarction, or infiltrative changes evident. The spleen measured 2.5 cm in width.

**Liver**

Normal size, echogenic appearance, portal markings, and regular curvilinear capsule. No nodules or masses evident. Normal appearance of the hepatic and portal vasculature.

**Gallbladder**

The gallbladder is full containing normal anechoic bile. Normal thickness and echogenic appearance of the wall. Normal size and appearance of the cystic and common bile duct.



**PATIENT**

Ducky Hahn

**SPECIES**

Canine

**BREED**

Mix

**SEX**

Neutered male

**AGE**

4 years

**WEIGHT**

40 lbs

**INTERPRETED BY**

Remo Lobetti, BVSc,  
MMedVet (Med),  
PhD, Dipl. ECVIM

**IMAGING PERFORMED BY**

Kerri Becker

**HOSPITAL NAME**

Companion VH of  
Wayne

**REFERRING VET**

Dr. Spitz

**INVOICE**

68933

**DATE**

11/24/25

**Gastrointestinal**

Normal appearance of the stomach, duodenum, small intestine, ileo-cecal junction, and colon with no loss of layering, 1:3 muscularis to mucosa ratio, normal wall thickness and peristaltic activity, and no distension of the lumen.

**Pancreas**

The visible sections of the pancreas are of normal size and echogenic appearance with a regular capsule. Normal echogenic appearance of the mesentery and fat surrounding the pancreas.

**Free Abdomen**

Normal mesenteric lymph nodes.

No ascites evident.

**ULTRASONOGRAPHIC FINDINGS**

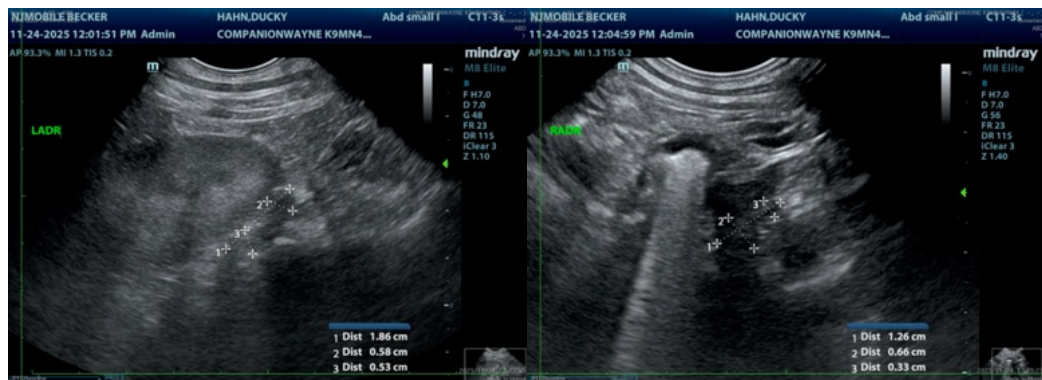
- Normal ultrasound examination of the abdomen.

**INTERPRETATION OF THE FINDINGS & FURTHER RECOMMENDATIONS**

On this ultrasound there was no obvious etiology for the presenting clinical signs.

With the presenting clinical signs urethral pathology should still be considered with further assessment being a contrast urethrogram.

Specific therapy would be dependent on an etiological diagnosis.





**PATIENT**

Ducky Hahn

**SPECIES**

Canine

**BREED**

Mix

**SEX**

Neutered male

**AGE**

4 years

**WEIGHT**

40 lbs

**INTERPRETED BY**

Remo Lobetti, BVSc,  
 MMedVet (Med),  
 PhD, Dipl. ECVIM

**IMAGING PERFORMED BY**

Kerri Becker

**HOSPITAL NAME**

Companion VH of  
 Wayne

**REFERRING VET**

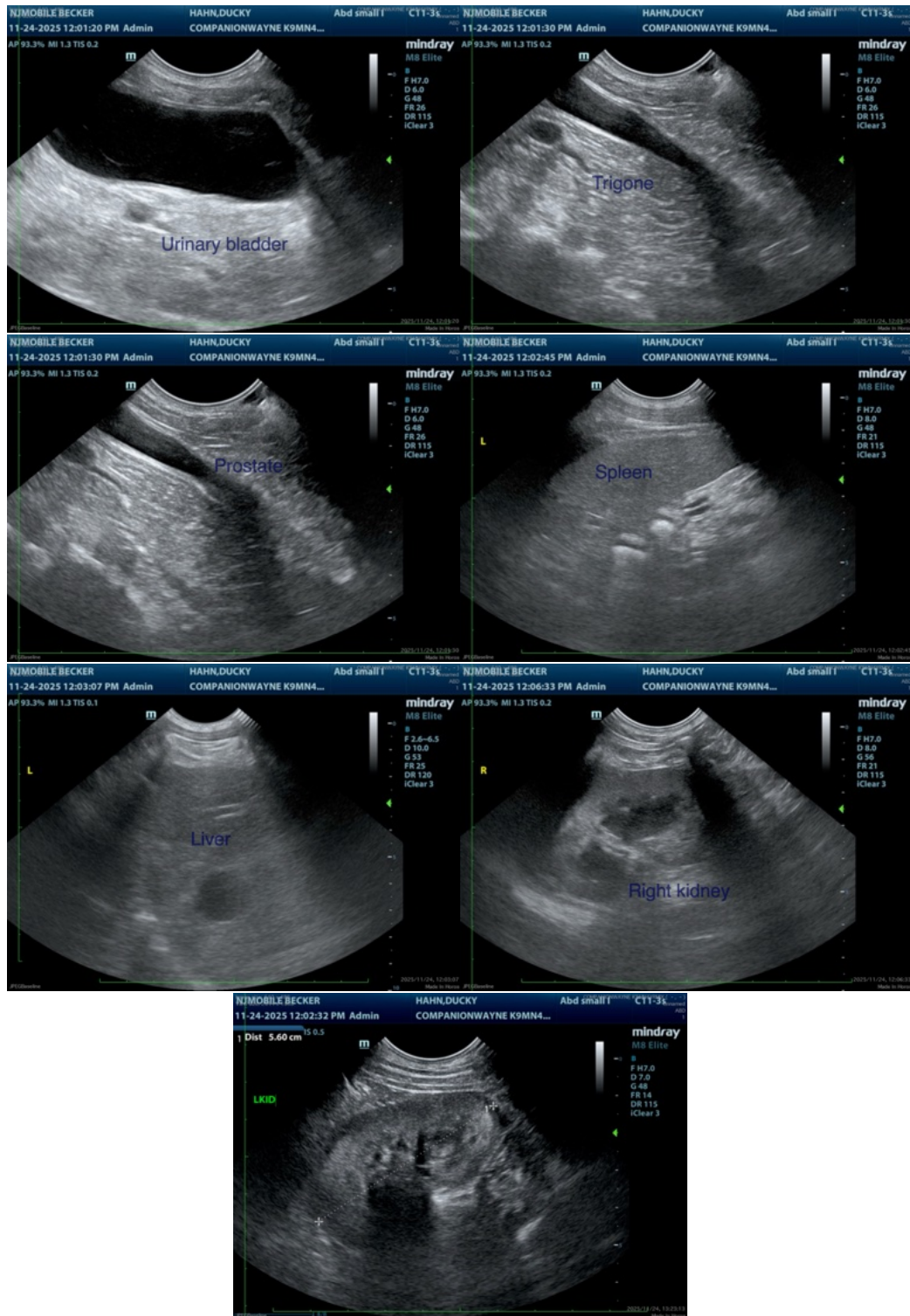
Dr. Spitz

**INVOICE**

68933

**DATE**

11/24/25





**PATIENT**

Ducky Hahn

**SPECIES**

Canine

**BREED**

Mix

**SEX**

Neutered male

**AGE**

4 years

**WEIGHT**

40 lbs

**INTERPRETED BY**

Remo Lobetti, BVSc,  
MMedVet (Med),  
PhD, Dipl. ECVIM

**IMAGING  
PERFORMED BY**

Kerri Becker

**HOSPITAL NAME**

Companion VH of  
Wayne

**REFERRING VET**

Dr. Spitz

**INVOICE**

68933

**DATE**

11/24/25

The information and recommendations provided are based on the images presented by the referring veterinarian/sonographer. No evaluation can be communicated regarding pathology that was not visible in the image/video clips provided.

Thank you for this referral. If the clinical or image interpretation does not parallel your findings or if I can be of any further assistance please contact me.

**Remo Lobetti, BVSc, MMedVet (Med), PhD, Dipl. ECVIM (Internal Medicine)**

[info@sonopath.com](mailto:info@sonopath.com)