



PATIENT

Diva Roman

SPECIES

Canine

BREED

Shih Tzu

SEX

Spayed female

AGE

10 ½ years

WEIGHT

12.5 lbs

INTERPRETED BY

Remo Lobetti, BVSc,
MMedVet (Med),
PhD, Dipl. ECVIM

IMAGING PERFORMED BY

Kerri Becker

HOSPITAL NAME

Whippany VH

REFERRING VET

Dr. Cordero

INVOICE

68886

DATE

11/20/25

PRESENTING CLINICAL SIGNS

History: Chronic on and off vomiting dx w/ibd full thickness biopsies 2017. On RC hydrolyzed protein dry. Meds- Pred 5 mg and pepcid.

Abnormal PE/Chem/CBC/UA Results: Oct. 2025 plt-448 fecal neg. UA PH-8 prot-1+ bili-1+ RBC-2-3 sg-1.039 struvite-4-10

ULTRASONOGRAPHIC EXAMINATION OF THE ABDOMEN

Urinary System

The urinary bladder is full with a normal thickness and smooth appearance of the wall. Normal anechoic urine with no sediment or uroliths evident.

Normal appearance of the trigone area, proximal urethra, and iliac blood vessels.

Normal appearance and size of the iliac lymph nodes. Ureters not visualized, which can be considered a normal finding.

Normal renal size (left measured 3.4 cm, right measured 3.1 cm), architecture, echogenic appearance, cortico-medullary differentiation, which maintains a 1:3 cortex to medulla ratio, pelvis, and capsule. No infarcts, mineralization or renoliths evident. Normal color flow pattern is evident in both kidneys.

Adrenal Glands

Normal shape, echogenic appearance, size, position, and appearance of the visible peri-adrenal vasculature. Left adrenal gland measured 1.26 cm in length x 0.45 cm and 0.46 cm in width. The right adrenal gland measured 1.72 cm in length x 0.46 cm and 0.39 cm in width.

Spleen

Normal size and echogenic appearance. Smooth homogenous parenchyma and regular curvilinear capsule. Normal volume of the splenic vasculature without any overt congestion or thrombosis evident. No inflammatory, neoplastic, infarction, or infiltrative changes evident. The spleen measured 1.6 cm in width.

Liver

Normal size, echogenic appearance, portal markings, and regular curvilinear capsule. No nodules or masses evident. Normal appearance of the hepatic and portal vasculature.

Gallbladder

The gallbladder is full containing normal anechoic bile. Normal thickness and echogenic appearance of the wall. Normal size and appearance of the cystic and common bile duct.



PATIENT

Gastrointestinal

Diva Roman

Normal appearance of the stomach, duodenum, small intestine, ileo-cecal junction, and colon with no loss of layering, 1:3 muscularis to mucosa ratio, normal wall thickness and peristaltic activity, and no distension of the lumen.

SPECIES

Canine

BREED

Shih Tzu

Pancreas

The visible sections of the pancreas are of normal size and echogenic appearance with a regular capsule. Normal echogenic appearance of the mesentery and fat surrounding the pancreas.

SEX

Spayed female

Free Abdomen

Normal mesenteric lymph nodes.

AGE

10 ½ years

No ascites evident.

WEIGHT

12.5 lbs

ULTRASONOGRAPHIC FINDINGS

- Normal ultrasound examination of the abdomen.

INTERPRETED BY

Remo Lobetti, BVSc,
MMedVet (Med),
PhD, Dipl. ECVIM

INTERPRETATION OF THE FINDINGS & FURTHER RECOMMENDATIONS

On this ultrasound there is no obvious etiology for the intermittent vomiting and thus is most likely associated with the previous diagnosis of inflammatory bowel disease.

IMAGING PERFORMED BY

Kerri Becker

Further assessment that can be considered (if not already done) would be cobalamin and folate assay.

HOSPITAL NAME

Whippany VH

Management would be to continue with the current therapy and to supplement cobalamin if needed.

REFERRING VET

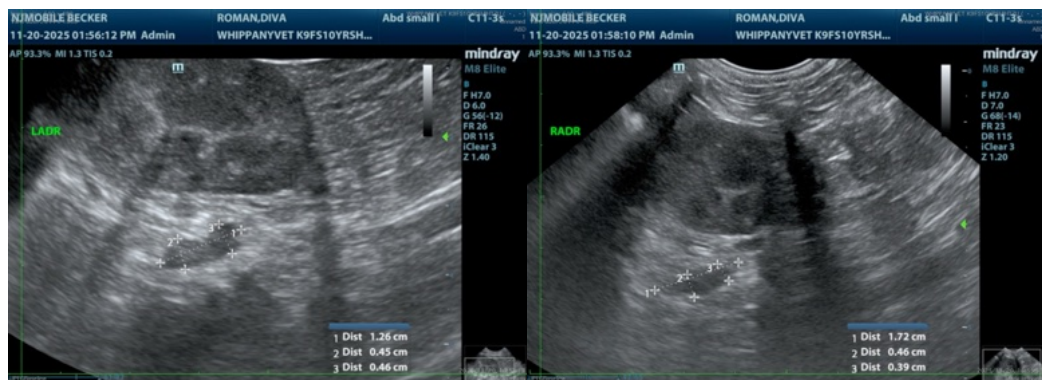
Dr. Cordero

INVOICE

68886

DATE

11/20/25





PATIENT

Diva Roman

SPECIES

Canine

BREED

Shih Tzu

SEX

Spayed female

AGE

10 ½ years

WEIGHT

12.5 lbs

INTERPRETED BY

Remo Lobetti, BVSc,
 MMedVet (Med),
 PhD, Dipl. ECVIM

IMAGING PERFORMED BY

Kerri Becker

HOSPITAL NAME

Whippany VH

REFERRING VET

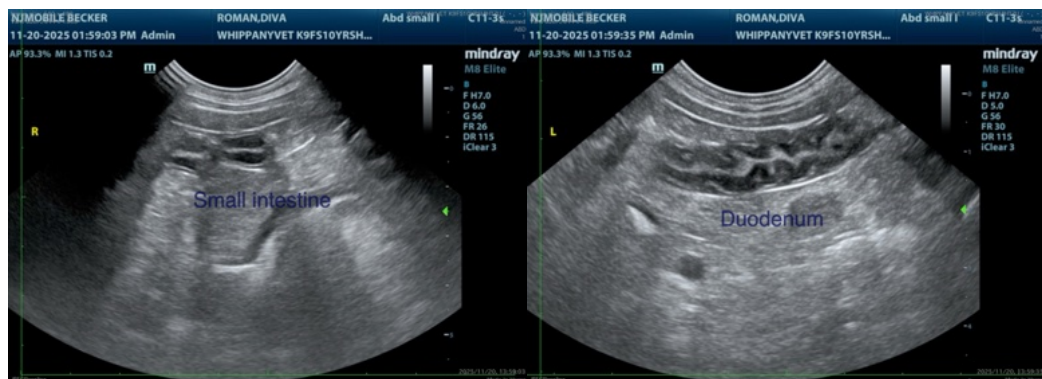
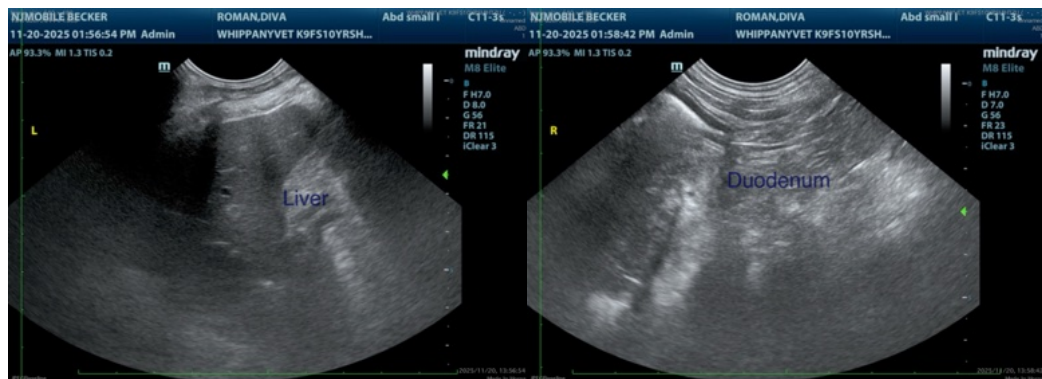
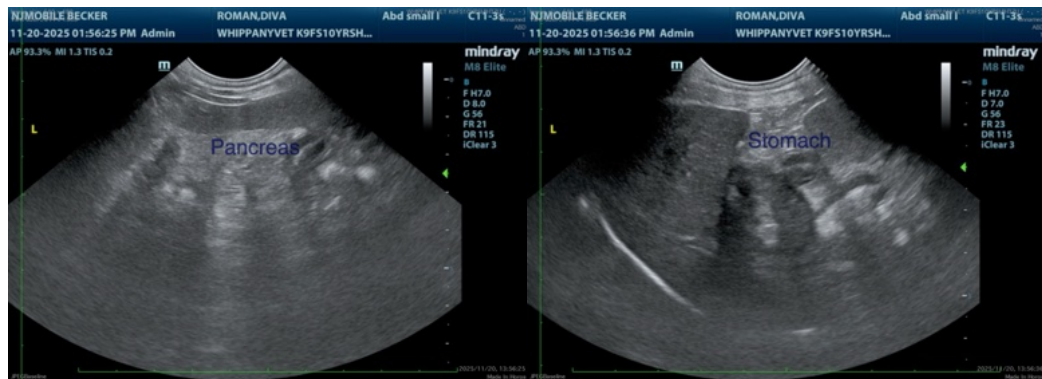
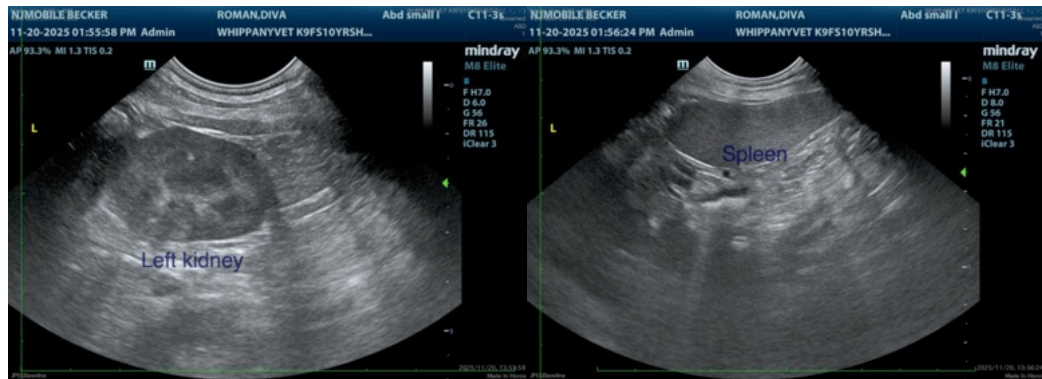
Dr. Cordero

INVOICE

68886

DATE

11/20/25





PATIENT

Diva Roman

SPECIES

Canine

BREED

Shih Tzu

SEX

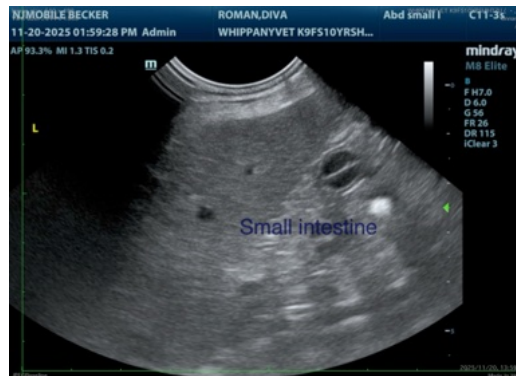
Spayed female

AGE

10 ½ years

WEIGHT

12.5 lbs



The information and recommendations provided are based on the images presented by the referring veterinarian/sonographer. No evaluation can be communicated regarding pathology that was not visible in the image/video clips provided.

Thank you for this referral. If the clinical or image interpretation does not parallel your findings or if I can be of any further assistance please contact me.

Remo Lobetti, BVSc, MMedVet (Med), PhD, Dipl. ECVIM (Internal Medicine)

info@sonopath.com

INTERPRETED BY

Remo Lobetti, BVSc,
MMedVet (Med),
PhD, Dipl. ECVIM

IMAGING PERFORMED BY

Kerri Becker

HOSPITAL NAME

Whippany VH

REFERRING VET

Dr. Cordero

INVOICE

68886

DATE

11/20/25