



PATIENT

Isabel Houck

SPECIES

Feline

BREED

Domestic Shorthair

SEX

Spayed female

AGE

14 years

WEIGHT

9.3 lbs

INTERPRETED BY

Remo Lobetti, BVSc,
MMedVet (Med),
PhD, Dipl. ECVIM

IMAGING PERFORMED BY

Shari Reffi, CVT

HOSPITAL NAME

Leck VH

REFERRING VET

Dr. Derr

INVOICE

68637

DATE

11/13/25

PRESENTING CLINICAL SIGNS

History: Partial anorexia, intermittent vomiting. Current Medications: Cerenia 16mg (1/2 tab eod), renal diet, Mirataz prn.

Abnormal PE/Chem/CBC/UA Results: Intermittent hypercalcemia-normal ionized panel to MSU, hx: creat 2.3 (recent 1.5), stress hyperglycemia & normal fructosamine. USG: 1.020

ULTRASONOGRAPHIC EXAMINATION OF THE ABDOMEN

Urinary System

The urinary bladder is full with a normal thickness and smooth appearance of the wall. Normal anechoic urine with no sediment or uroliths evident.

Normal appearance of the trigone area, proximal urethra, and iliac blood vessels.

Normal appearance and size of the iliac lymph nodes. Ureters not visualized, which can be considered a normal finding.

Normal renal size (left measured 3.0 cm, right measured 3.3 cm), architecture, echogenic appearance, cortico-medullary differentiation, which maintains a 1:3 cortex to medulla ratio, pelvis, and capsule. No infarcts, mineralization or renoliths evident. Normal color flow pattern is evident in both kidneys.

Adrenal Glands

Normal shape, echogenic appearance, size, position, and appearance of the visible peri-adrenal vasculature. Left adrenal gland measured 0.51 cm in width. The right adrenal gland measured 0.47 cm in width.

Spleen

Normal size and echogenic appearance. Smooth homogenous parenchyma and regular curvilinear capsule. Normal volume of the splenic vasculature without any overt congestion or thrombosis evident. No inflammatory, neoplastic, infarction, or infiltrative changes evident. The spleen measured 0.8 cm in width.

Liver

Normal size, echogenic appearance, portal markings, and regular curvilinear capsule. No nodules or masses evident. Normal appearance of the hepatic and portal vasculature.

Gallbladder

The gallbladder is small containing normal anechoic bile. Normal thickness and echogenic appearance of the wall. Normal size and appearance of the cystic and common bile duct.



PATIENT

Isabel Houck

SPECIES

Feline

BREED

Domestic Shorthair

SEX

Spayed female

AGE

14 years

WEIGHT

9.3 lbs

INTERPRETED BY

Remo Lobetti, BVSc,
MMedVet (Med),
PhD, Dipl. ECVIM

IMAGING PERFORMED BY

Shari Reffi, CVT

HOSPITAL NAME

Leck VH

REFERRING VET

Dr. Derr

INVOICE

68637

DATE

11/13/25

Gastrointestinal

Normal appearance of the stomach, duodenum, small intestine, ileo-cecal junction, and colon with no loss of layering, 1:3 muscularis to mucosa ratio, normal wall thickness and peristaltic activity, and no distension of the lumen.

Pancreas

Normal size (left pancreas measured 0.5 cm in width) with a mottled echogenic appearance and a mildly irregular capsule. Normal echogenic appearance of the mesentery and fat surrounding the pancreas.

Free Abdomen

Normal mesenteric lymph nodes.

No ascites evident.

ULTRASONOGRAPHIC FINDINGS

- Chronic pancreatitis versus pancreatic fibrosis.

INTERPRETATION OF THE FINDINGS & FURTHER RECOMMENDATIONS

Although the pancreatic changes could account for the presenting clinical signs an underlying enteropathy even though the GI tract appears ultrasonographically normal should still be considered with possible etiologies being parasitic enteritis, dietary hypersensitivity and inflammatory bowel disease.

Further assessment would be fecal analysis, cobalamin, folate and FPL/PSL assay and possibly endoscopy of the upper GI tract with biopsies.

Specific therapy would be dependent on an etiological diagnosis. Symptomatic management would be feeding small frequent meals of a novel protein/hypoallergenic diet, course of Fenbendazole, cobalamin supplementation and if there is still not a satisfactory improvement then a course of Prednisolone would then be indicated.



PATIENT

Isabel Houck

SPECIES

Feline

BREED

Domestic Shorthair

SEX

Spayed female

AGE

14 years

WEIGHT

9.3 lbs

INTERPRETED BY

Remo Lobetti, BVSc,
MMedVet (Med),
PhD, Dipl. ECVIM

IMAGING PERFORMED BY

Shari Reffi, CVT

HOSPITAL NAME

Leck VH

REFERRING VET

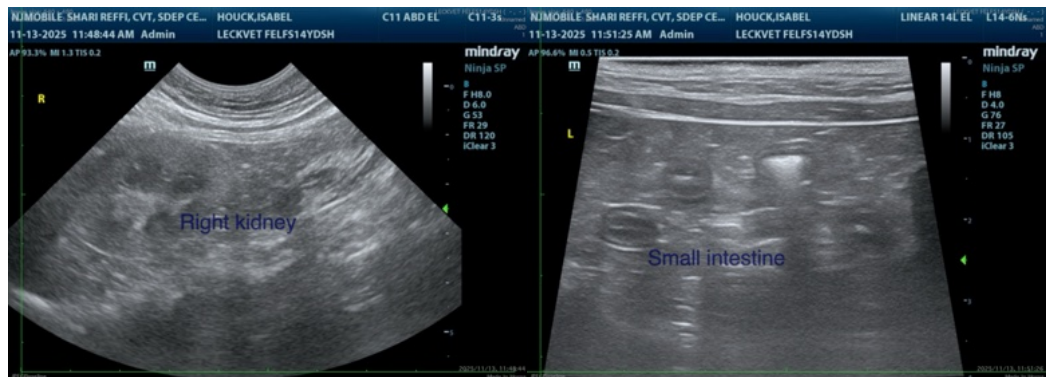
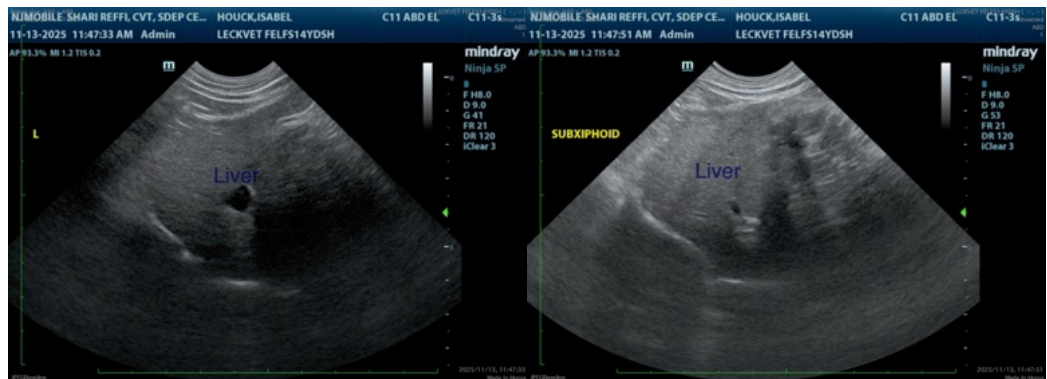
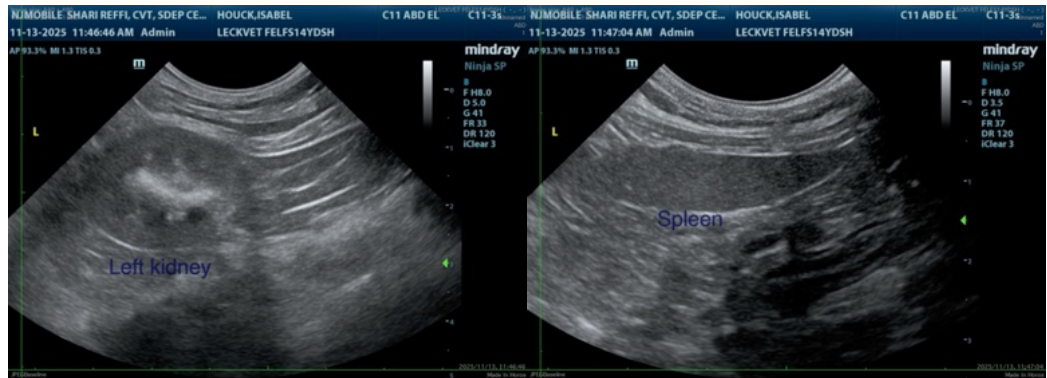
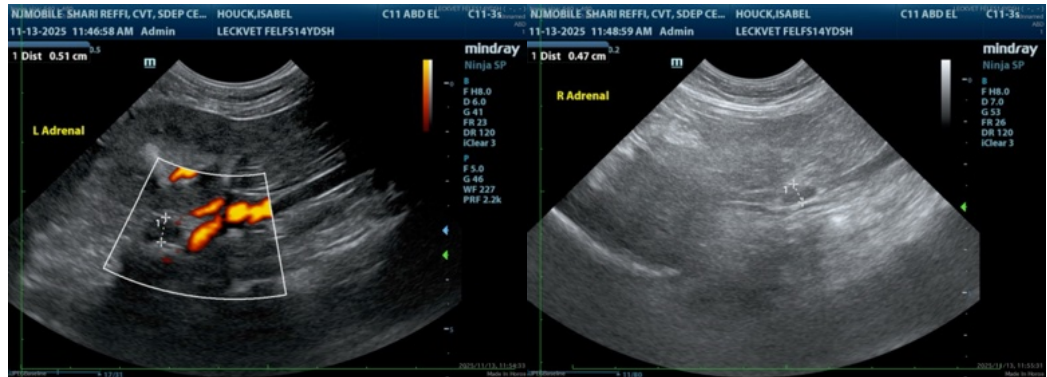
Dr. Derr

INVOICE

68637

DATE

11/13/25





PATIENT

Isabel Houck

SPECIES

Feline

BREED

Domestic Shorthair

SEX

Spayed female

AGE

14 years

WEIGHT

9.3 lbs

INTERPRETED BY

Remo Lobetti, BVSc,
MMedVet (Med),
PhD, Dipl. ECVIM

IMAGING PERFORMED BY

Shari Reffi, CVT

HOSPITAL NAME

Leck VH

REFERRING VET

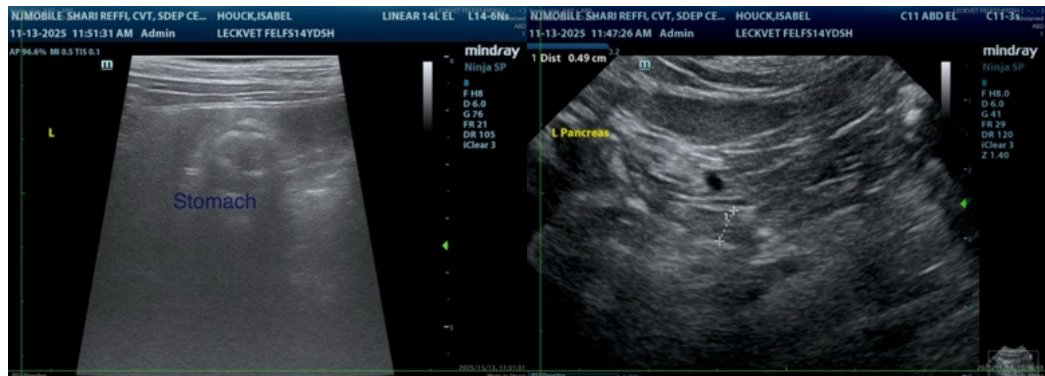
Dr. Derr

INVOICE

68637

DATE

11/13/25



The information and recommendations provided are based on the images presented by the referring veterinarian/sonographer. No evaluation can be communicated regarding pathology that was not visible in the image/video clips provided.

Thank you for this referral. If the clinical or image interpretation does not parallel your findings or if I can be of any further assistance please contact me.

Remo Lobetti, BVSc, MMedVet (Med), PhD, Dipl. ECVIM (Internal Medicine)

info@sonopath.com