



PATIENT

Lola Venezia

SPECIES

Canine

BREED

Siberian Husky

SEX

Spayed female

AGE

10 years

WEIGHT

57.6 lbs

INTERPRETED BY

Remo Lobetti, BVSc,
MMedVet (Med),
PhD, Dipl. ECVIM

IMAGING PERFORMED BY

Dr. Ken Leal

HOSPITAL NAME

VCA Blirstown AH

REFERRING VET

Dr. Summers

INVOICE

68598

DATE

11/12/25

PRESENTING CLINICAL SIGNS

History: Elevated AlkPhos LDDST confirms HAC but cannot determine if PDH or adrenal. Had 2 urinary accidents. No PU/PD until 5 days ago. Medications: None
Abnormal PE/Chem/CBC/UA Results: AlkPhos = 1447 (in 2023 was 4,000)

ULTRASONOGRAPHIC EXAMINATION OF THE ABDOMEN

Urinary System

The urinary bladder is full with a normal thickness and smooth appearance of the wall. Normal anechoic urine with no sediment or uroliths evident.

Normal appearance of the trigone area, proximal urethra, and iliac blood vessels.

Normal appearance and size of the iliac lymph nodes. Ureters not visualized, which can be considered a normal finding.

Normal renal size (left measured 5.7 cm, right measured 6.1 cm), architecture, echogenic appearance, cortico-medullary differentiation, which maintains a 1:3 cortex to medulla ratio, pelvis, and capsule. No infarcts, mineralization or renoliths evident.

Adrenal Glands

Normal shape, echogenic appearance, size, position, and appearance of the visible peri-adrenal vasculature. Left adrenal gland measured 2.41 cm in length x 0.57 cm and 0.46 cm in width. The right adrenal gland measured 2.87 cm in length 0.6 cm in width.

Spleen

Normal size and echogenic appearance. Smooth homogenous parenchyma and regular curvilinear capsule. Normal volume of the splenic vasculature without any overt congestion or thrombosis evident. No inflammatory, neoplastic, infarction, or infiltrative changes evident. The spleen measured 1.8 cm in width.

Liver

Normal size, echogenic appearance, portal markings, and regular curvilinear capsule. No nodules or masses evident. Normal appearance of the hepatic and portal vasculature.

Gallbladder

The gallbladder is full containing normal anechoic bile. Normal thickness and echogenic appearance of the wall. Normal size and appearance of the cystic and common bile duct.



PATIENT

Lola Venezia

SPECIES

Canine

BREED

Siberian Husky

SEX

Spayed female

AGE

10 years

WEIGHT

57.6 lbs

INTERPRETED BY

Remo Lobetti, BVSc,
MMedVet (Med),
PhD, Dipl. ECVIM

IMAGING PERFORMED BY

Dr. Ken Leal

HOSPITAL NAME

VCA Blirstown AH

REFERRING VET

Dr. Summers

INVOICE

68598

DATE

11/12/25

Gastrointestinal

Normal appearance of the stomach, duodenum, small intestine, ileo-cecal junction, and colon with no loss of layering, 1:3 muscularis to mucosa ratio, normal wall thickness and peristaltic activity, and no distension of the lumen.

Pancreas

The visible sections of the pancreas are of normal size and echogenic appearance with a regular capsule. Normal echogenic appearance of the mesentery and fat surrounding the pancreas.

Free Abdomen

Normal mesenteric lymph nodes.

No ascites evident.

ULTRASONOGRAPHIC FINDINGS

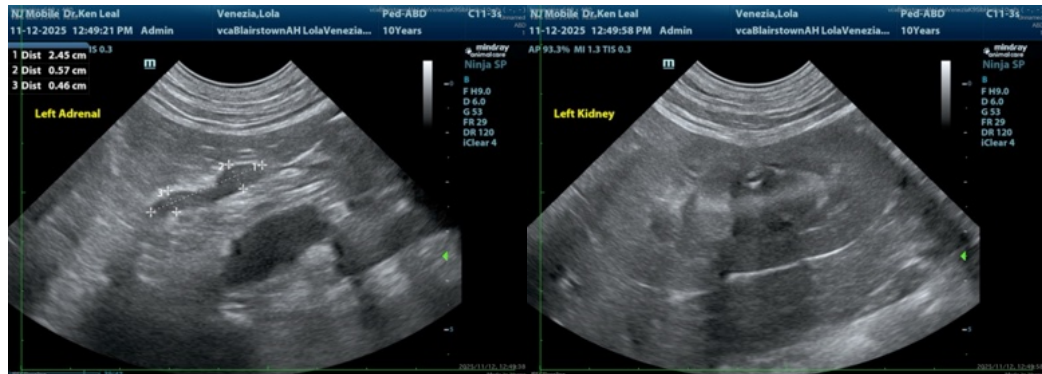
- Normal ultrasound examination of the abdomen.

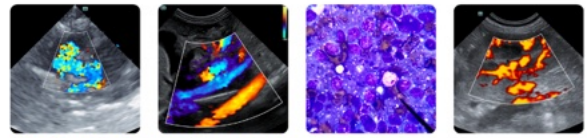
INTERPRETATION OF THE FINDINGS & FURTHER RECOMMENDATIONS

On this ultrasound, there is no obvious evidence of Cushing's disease (adrenomegaly, hepatopathy).

Dogs with Cushing's disease may have adrenal glands of normal size and shape on ultrasound, particularly in pituitary-dependent hyperadrenocorticism. This highlights the importance of functional testing over anatomical imaging alone in diagnosing Cushing's disease.

Treatment is not indicated if Cushing's is picked up as an incidental finding or there are minimal clinical signs. Generally, Cushing's is treated when the clinical signs affect or reduce quality of life. Important signs are PuPd, possibly polyphagia, polynea, muscle weakness and lethargy and especially if the signs are progressive. Treatment should be started if there are associated complications such as hypertension, concurrent diabetes mellitus, thrombo-embolic disease, or recurrent infections.





PATIENT

Lola Venezia

SPECIES

Canine

BREED

Siberian Husky

SEX

Spayed female

AGE

10 years

WEIGHT

57.6 lbs

INTERPRETED BY

Remo Lobetti, BVSc,
MMedVet (Med),
PhD, Dipl. ECVIM

IMAGING PERFORMED BY

Dr. Ken Leal

HOSPITAL NAME

VCA Blirstown AH

REFERRING VET

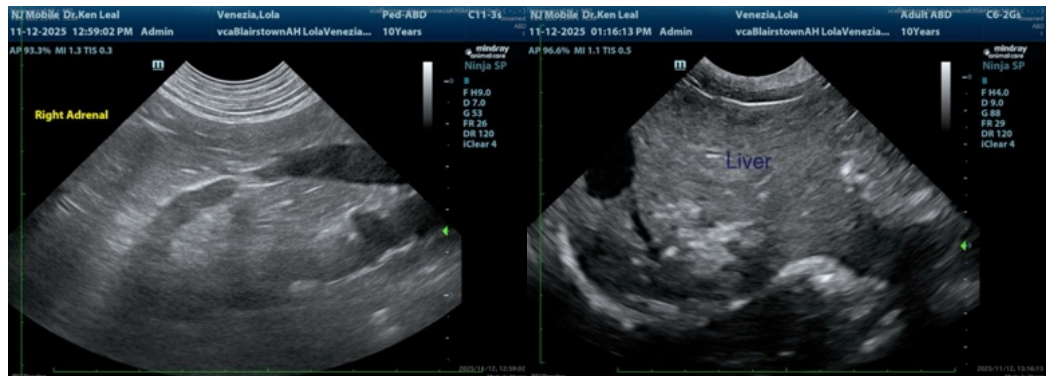
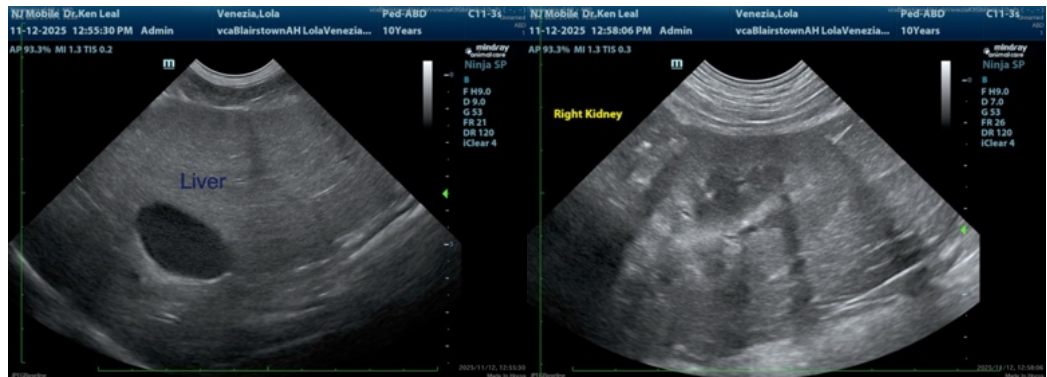
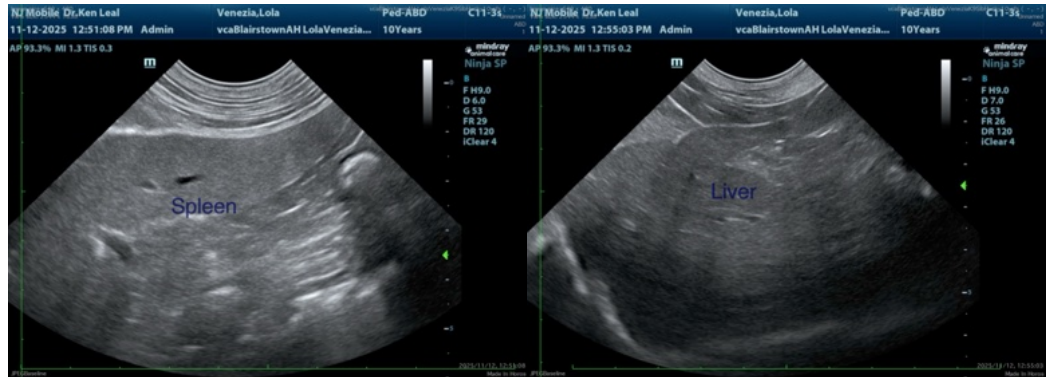
Dr. Summers

INVOICE

68598

DATE

11/12/25





PATIENT

Lola Venezia

SPECIES

Canine

BREED

Siberian Husky

SEX

Spayed female

AGE

10 years

WEIGHT

57.6 lbs

INTERPRETED BY

Remo Lobetti, BVSc,
MMedVet (Med),
PhD, Dipl. ECVIM

IMAGING PERFORMED BY

Dr. Ken Leal

HOSPITAL NAME

VCA Blirstown AH

REFERRING VET

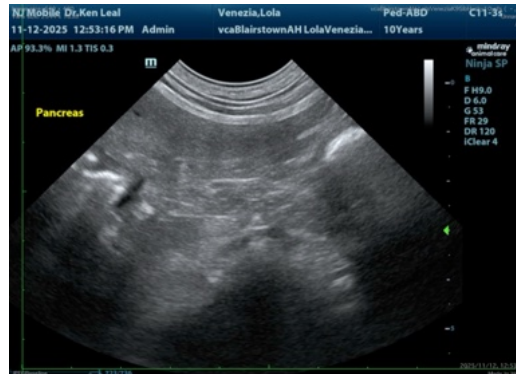Dr. Summers

INVOICE

68598

DATE

11/12/25



The information and recommendations provided are based on the images presented by the referring veterinarian/sonographer. No evaluation can be communicated regarding pathology that was not visible in the image/video clips provided.

Thank you for this referral. If the clinical or image interpretation does not parallel your findings or if I can be of any further assistance please contact me.

Remo Lobetti, BVSc, MMedVet (Med), PhD, Dipl. ECVIM (Internal Medicine)
info@sonopath.com