



PATIENT

Betty White Palladino

SPECIES

Canine

BREED

Pomeranian Mix

SEX

Spayed female

AGE

13 years

WEIGHT

-

INTERPRETED BY

Remo Lobetti, BVSc,
MMedVet (Med),
PhD, Dipl. ECVIM

IMAGING PERFORMED BY

Kerri Becker

HOSPITAL NAME

Animal General on
Hudson

REFERRING VET

Dr. DiGiuseppi

INVOICE

68500

DATE

11/10/25

PRESENTING CLINICAL SIGNS

History: Elevated ALP-149 HX of pancreatitis and hypo T4
Abnormal PE/Chem/CBC/UA Results: ALP-149 BUN-32

ULTRASONOGRAPHIC EXAMINATION OF THE ABDOMEN

Urinary System

The urinary bladder is small with a normal thickness and smooth appearance of the wall. A scant amount of floating, hyperechogenic sediment.

Normal appearance of the trigone area, proximal urethra, and iliac blood vessels.

Normal appearance and size of the iliac lymph nodes. Ureters not visualized, which can be considered a normal finding.

Normal renal size (left measured 4.1 cm, right measured 4.1 cm), architecture, echogenic appearance, cortico-medullary differentiation, which maintains a 1:3 cortex to medulla ratio, pelvis, and capsule. No infarcts, mineralization or renoliths evident. The kidneys had a normal color flow pattern.

Adrenal Glands

Normal shape, echogenic appearance, size, position, and appearance of the visible peri-adrenal vasculature. Left adrenal gland measured 2.09 cm in length x 0.59 cm and 0.57 cm in width. The right adrenal gland measured 1.93 cm in length x 0.59 cm in width.

Spleen

Normal size and echogenic appearance. Smooth homogenous parenchyma and regular curvilinear capsule. Normal volume of the splenic vasculature without any overt congestion or thrombosis evident. No inflammatory, neoplastic, infarction, or infiltrative changes evident. The spleen measured 1.4 cm in width.

Liver

Normal size, echogenic appearance, portal markings, and regular curvilinear capsule. No nodules or masses evident. Normal appearance of the hepatic and portal vasculature.

Gallbladder

The gallbladder is full containing normal anechoic bile. Normal thickness and echogenic appearance of the wall. Normal size and appearance of the cystic and common bile duct.



PATIENT

Betty White Palladino

SPECIES

Canine

BREED

Pomeranian Mix

SEX

Spayed female

AGE

13 years

WEIGHT

-

INTERPRETED BY

Remo Lobetti, BVSc,
MMedVet (Med),
PhD, Dipl. ECVIM

IMAGING PERFORMED BY

Kerri Becker

HOSPITAL NAME

Animal General on
Hudson

REFERRING VET

Dr. DiGiuseppi

INVOICE

68500

DATE

11/10/25

Gastrointestinal

Normal appearance of the stomach, duodenum, small intestine, ileo-cecal junction, and colon with no loss of layering, 1:3 muscularis to mucosa ratio, normal wall thickness and peristaltic activity, and no distension of the lumen.

Pancreas

Normal size and echogenic appearance with a regular capsule. Normal echogenic appearance of the mesentery and fat surrounding the pancreas.

Free Abdomen

Normal mesenteric lymph nodes.

No ascites evident.

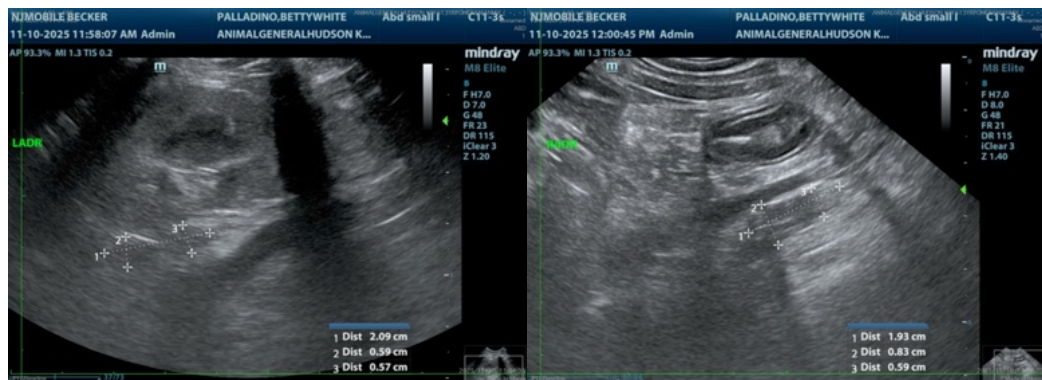
ULTRASONOGRAPHIC FINDINGS

- Normal ultrasound examination of the abdomen.

INTERPRETATION OF THE FINDINGS & FURTHER RECOMMENDATIONS

The most likely etiology for the elevated ALP activity would be age related reactive hyperplasia with vacuolar, metabolic, hepatitis and infiltrative neoplasia an unlikely differential diagnosis.

Further assessment that can be considered especially if there is progressive elevation of ALP activity would be FNA cytology of the liver.





PATIENT

Betty White Palladino

SPECIES

Canine

BREED

Pomeranian Mix

SEX

Spayed female

AGE

13 years

WEIGHT

-

INTERPRETED BY

Remo Lobetti, BVSc,
 MMedVet (Med),
 PhD, Dipl. ECVIM

IMAGING PERFORMED BY

Kerri Becker

HOSPITAL NAME

Animal General on
 Hudson

REFERRING VET

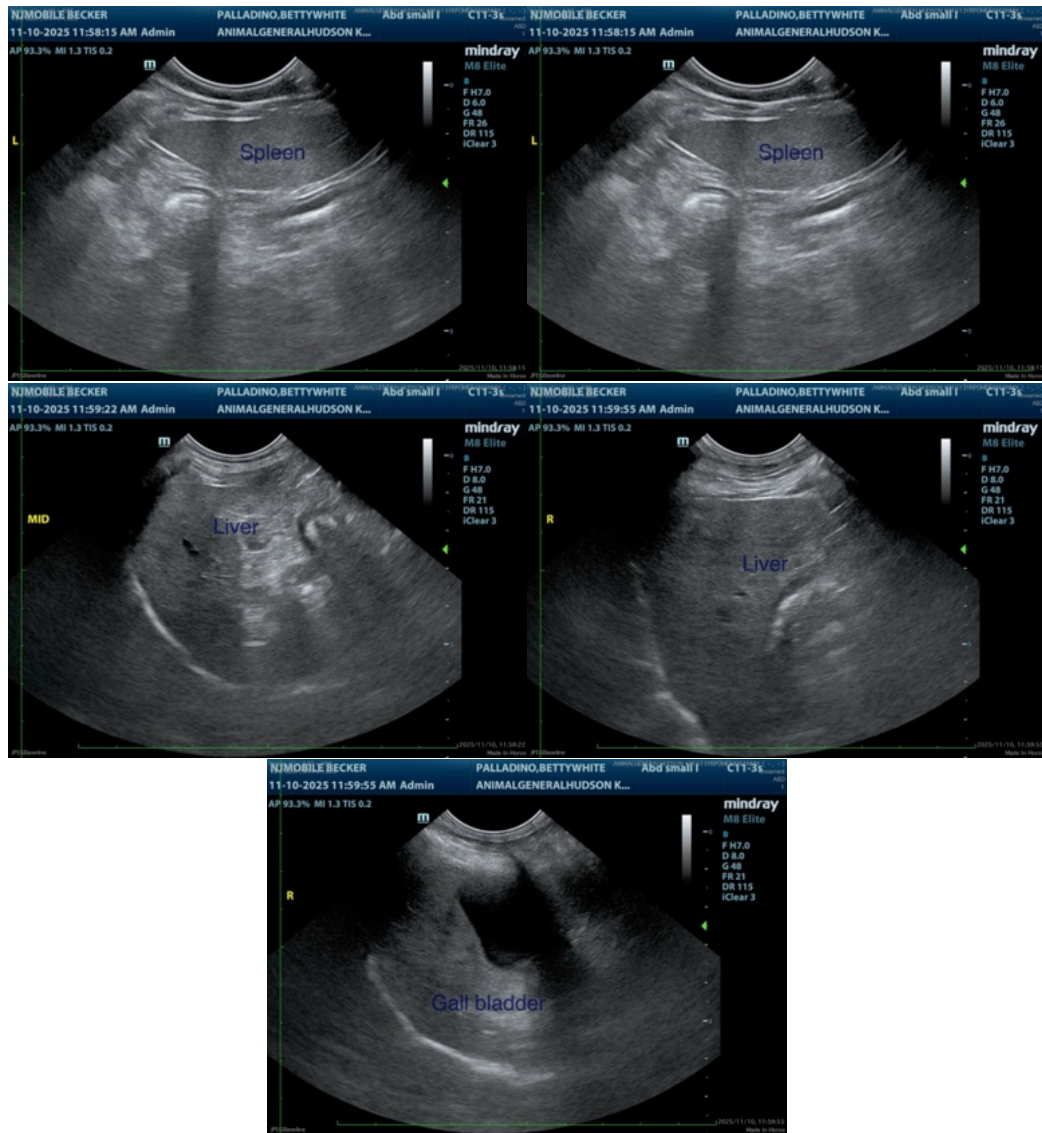
Dr. DiGiuseppi

INVOICE

68500

DATE

11/10/25



The information and recommendations provided are based on the images presented by the referring veterinarian/sonographer. No evaluation can be communicated regarding pathology that was not visible in the image/video clips provided.

Thank you for this referral. If the clinical or image interpretation does not parallel your findings or if I can be of any further assistance please contact me.

Remo Lobetti, BVSc, MMedVet (Med), PhD, Dipl. ECVIM (Internal Medicine)
info@sonopath.com