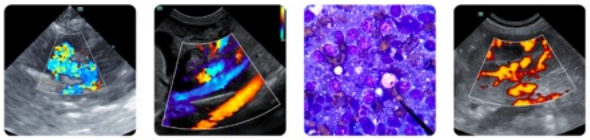



**PATIENT**
Cooper Bush

**SPECIES**
Canine

**BREED**
Maltese Mix

**SEX**
Neutered male

**AGE**
13 years

**WEIGHT**
19.6 lbs

**INTERPRETED BY**
Remo Lobetti, BVSc, MMedVet (Med), PhD, Dipl. ECVIM

**IMAGING PERFORMED BY**
Shari Reffi, CVT

**HOSPITAL NAME**
Newton VH

**REFERRING VET**
Dr. Wyman

**INVOICE**
69941

**DATE**
1/9/26

## PRESENTING CLINICAL SIGNS

History: Elevated LE's, asymptomatic. Current Meds: vetoryl 20mg sid
ALT 165; Alkp 763; Ca 13.1

## ULTRASONOGRAPHIC EXAMINATION OF THE ABDOMEN

### *Urinary System*

The urinary bladder is small with a normal thickness and smooth appearance of the wall. Normal anechoic urine with no sediment or uroliths evident.

Normal appearance of the trigone area, proximal urethra, and iliac blood vessels.

Normal appearance and size of the iliac lymph nodes. Ureters not visualized, which can be considered a normal finding.

Normal renal size (left measured 4.8 cm, right measured 5.1 cm), architecture, echogenic appearance, cortico-medullary differentiation, which maintains a 1:3 cortex to medulla ratio, pelvis, and capsule. No infarcts, mineralization or renoliths evident. Normal color flow pattern is evident in both kidneys.

The prostate is small and hypoechogenic measuring 0.8 cm in width.

### *Adrenal Glands*

The adrenal glands were mildly enlarged, but maintained normal shape, echogenic appearance, position and appearance of the visible peri-adrenal vasculature. Left adrenal gland measured 0.84 cm and 0.63 cm in width. The right adrenal gland measured 1.0 cm and 1.14 cm in width.

### *Spleen*

Normal size and echogenic appearance. Smooth homogenous parenchyma and regular curvilinear capsule. Normal volume of the splenic vasculature without any overt congestion or thrombosis evident. No inflammatory, neoplastic, infarction, or infiltrative changes evident. The spleen measured 1.3 cm in width.

### *Liver*

Normal size, echogenic appearance, portal markings, and regular curvilinear capsule. Incidental myelolipomas were present. No nodules or masses evident. Normal appearance of the hepatic and portal vasculature.

### *Gallbladder*

The gallbladder is small containing normal anechoic bile. Normal thickness and echogenic appearance of the wall. Normal size and appearance of the cystic and common bile duct.

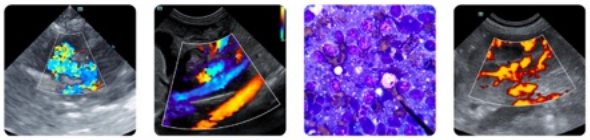



**PATIENT**
Cooper Bush

**SPECIES**
Canine

**BREED**
Maltese Mix

**SEX**
Neutered male

**AGE**
13 years

**WEIGHT**
19.6 lbs

**INTERPRETED BY**
Remo Lobetti, BVSc, MMedVet (Med), PhD, Dipl. ECVIM

**IMAGING PERFORMED BY**
Shari Reffi, CVT

**HOSPITAL NAME**
Newton VH

**REFERRING VET**
Dr. Wyman

**INVOICE**
69941

**DATE**
1/9/26

### *Gastrointestinal*

Normal appearance of the stomach, duodenum, small intestine, ileo-cecal junction, and colon with no loss of layering, 1:3 muscularis to mucosa ratio, normal wall thickness and peristaltic activity, and no distension of the lumen.

### *Pancreas*

The visible sections of the pancreas are of normal size and echogenic appearance with a regular capsule. Normal echogenic appearance of the mesentery and fat surrounding the pancreas.

### *Free Abdomen*

Normal mesenteric lymph nodes.

No ascites evident.

## ULTRASONOGRAPHIC FINDINGS

- Hepatopathy.
- Adrenomegaly.

## INTERPRETATION OF THE FINDINGS & FURTHER RECOMMENDATIONS

Etiologies for the hepatopathy would be reactive hyperplasia, early nodular hyperplasia, vacuolar and metabolic with infiltrative neoplasia and hepatitis an unlikely differential diagnosis.

Etiologies for the adrenomegaly would be age related reactive hyperplasia, disease stress and possibly emerging pituitary dependent Cushing's disease.

On this ultrasound there is no obvious etiology for the hypercalcemia.

Mild hypercalcemia (total calcium) have been reported in dogs with Cushing's disease.

Further assessment would be urine specific gravity and urine cortisol to creatinine ratio, if abnormal then adrenal function testing (ACTH stimulation/LDDST) would then be indicated.

If Cushing's disease has been excluded then further assessment of the hepatopathy would be FNA cytology. However, a tru cut or wedge biopsy may be required for a final etiological diagnosis.

Further assessment of hypercalcemia would be ionized calcium and if abnormal then PTH or PTHrP protein assay.

Specific therapy would be dependent on an etiological diagnosis.

# SonoPath

FOSTERING THE ART OF VETERINARY MEDICINE™

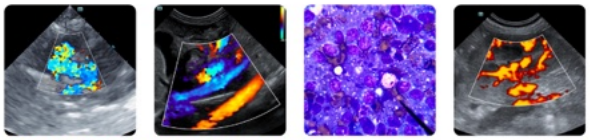

*Clinical Sonography & Telecytology*

*Educational Teleconsultation Services™*

SonoPath.com info@sonopath.com 1.800.838.4268

**PATIENT**

Cooper Bush

**SPECIES**

Canine

**BREED**

Maltese Mix

**SEX**

Neutered male

**AGE**

13 years

**WEIGHT**

19.6 lbs

**INTERPRETED BY**

Remo Lobetti, BVSc, MMedVet (Med), PhD, Dipl. ECVIM

**IMAGING PERFORMED BY**

Shari Reffi, CVT

**HOSPITAL NAME**

Newton VH

**REFERRING VET**

Dr. Wyman

**INVOICE**

69941

**DATE**

1/9/26

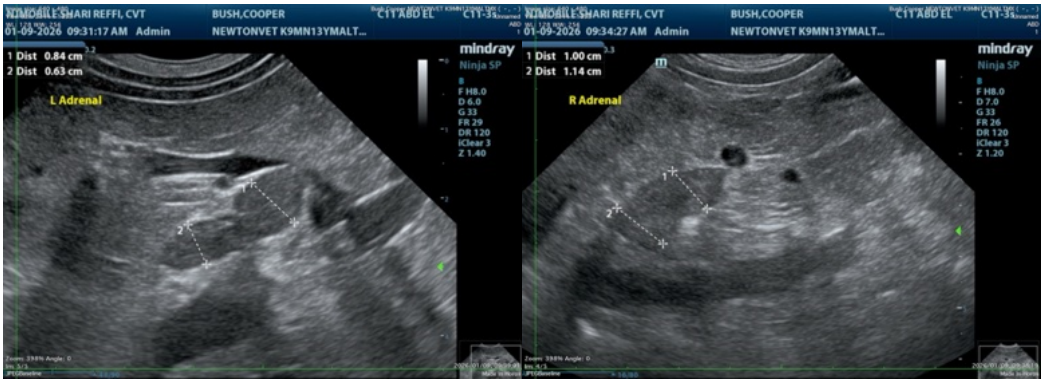


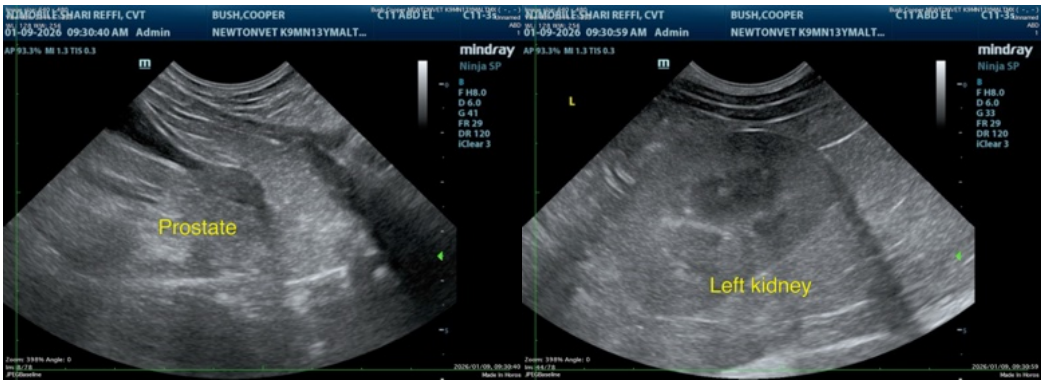


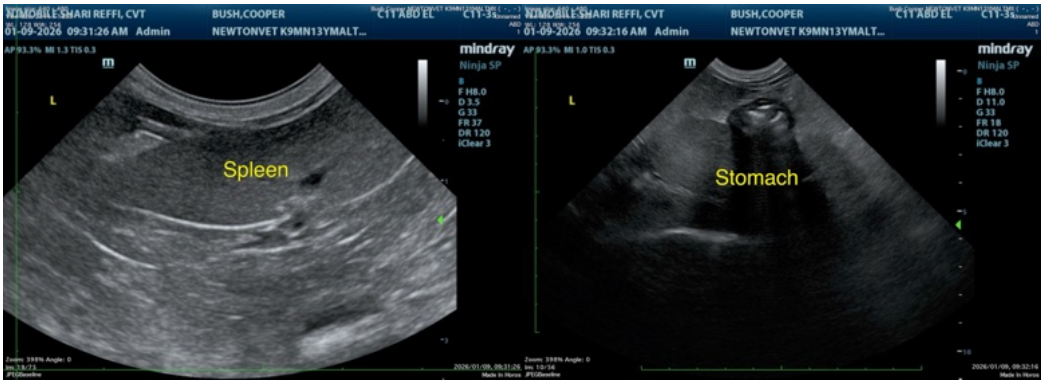


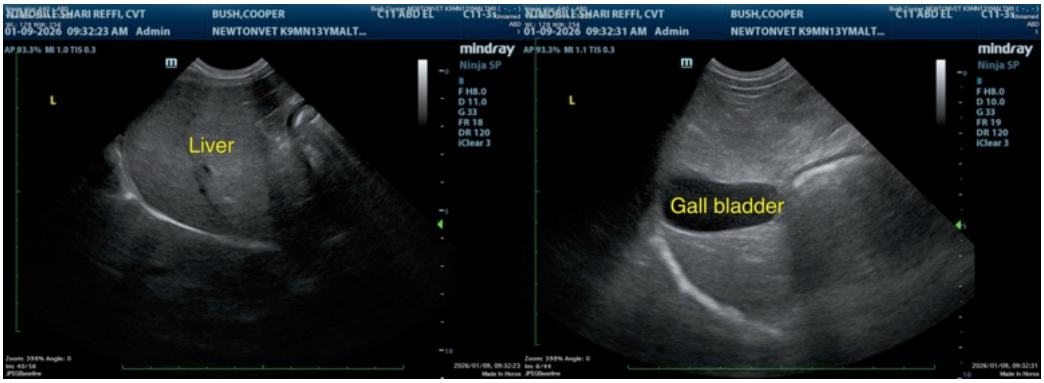

# SonoPath

FOSTERING THE ART OF VETERINARY MEDICINE™

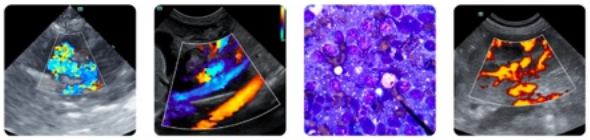

*Clinical Sonography & Telecytology*

*Educational Teleconsultation Services™*

SonoPath.com info@sonopath.com 1.800.838.4268

**PATIENT**

Cooper Bush

**SPECIES**

Canine

**BREED**

Maltese Mix

**SEX**

Neutered male

**AGE**

13 years

**WEIGHT**

19.6 lbs

**INTERPRETED BY**

Remo Lobetti, BVSc, MMedVet (Med), PhD, Dipl. ECVIM

**IMAGING PERFORMED BY**

Shari Reffi, CVT

**HOSPITAL NAME**

Newton VH

**REFERRING VET**

Dr. Wyman

**INVOICE**

69941

**DATE**

1/9/26

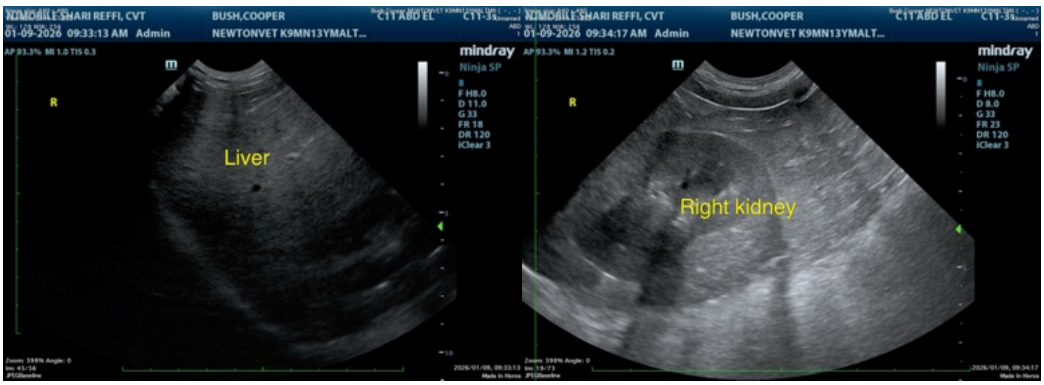


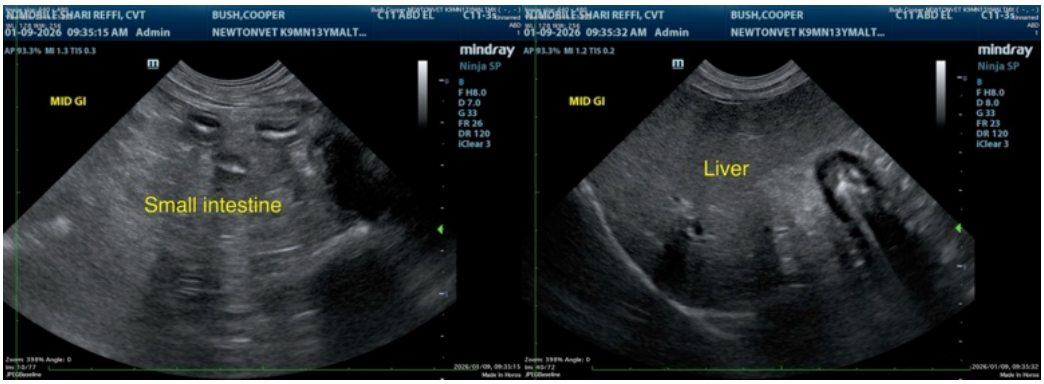


**The information and recommendations provided are based on the images presented by the referring veterinarian/sonographer. No evaluation can be communicated regarding pathology that was not visible in the image/video clips provided.**

Thank you for this referral. If the clinical or image interpretation does not parallel your findings or if I can be of any further assistance please contact me.

**Remo Lobetti**, BVSc, MMedVet (Med), PhD, Dipl. ECVIM (Internal Medicine)

info@sonopath.com