



PATIENT

Jax Tavares

SPECIES

Canine

BREED

Cockapoo

SEX

Neutered male

AGE

10 years

WEIGHT

11.3 lbs

INTERPRETED BY

Remo Lobetti, BVSc,
MMedVet (Med),
PhD, Dipl. ECVIM

IMAGING PERFORMED BY

Kerri Becker

HOSPITAL NAME

Kenilworth AH

REFERRING VET

Dr. Mansour

INVOICE

69961

DATE

1/8/26

PRESENTING CLINICAL SIGNS

History: Severe anemia and to R/O neoplasia

ULTRASONOGRAPHIC EXAMINATION OF THE ABDOMEN

Urinary System

The urinary bladder is full with a normal thickness and smooth appearance of the wall. Normal anechoic urine with no sediment or uroliths evident.

Normal appearance of the trigone area, proximal urethra, and iliac blood vessels.

Normal appearance and size of the iliac lymph nodes. Ureters not visualized, which can be considered a normal finding.

Normal renal size (left measured 3.5 cm, right measured 3.5 cm), architecture, echogenic appearance, cortico-medullary differentiation, which maintains a 1:3 cortex to medulla ratio, pelvis, and capsule. No infarcts, mineralization or renoliths evident. A normal color flow pattern was noted in the kidneys.

The prostate is small and hypoechogenic.

Adrenal Glands

Normal shape, echogenic appearance, size, position, and appearance of the visible peri-adrenal vasculature. Left adrenal gland measured 2.29 cm in length x 0.55 cm and 0.61 cm in width. The right adrenal gland measured 1.68 cm in length x 0.56 cm in width.

Spleen

Normal size and echogenic appearance. Smooth homogenous parenchyma and regular curvilinear capsule. Normal volume of the splenic vasculature without any overt congestion or thrombosis evident. No inflammatory, neoplastic, infarction, or infiltrative changes evident. The spleen measured 1.8 cm in width.

Liver

Normal size, echogenic appearance, portal markings, and regular curvilinear capsule. No nodules or masses evident. Normal appearance of the hepatic and portal vasculature.

Gallbladder

The gallbladder is small containing normal anechoic bile. Normal thickness and echogenic appearance of the wall. Normal size and appearance of the cystic and common bile duct.



PATIENT

Gastrointestinal

Jax Tavares

Normal appearance of the stomach, duodenum, small intestine, ileo-cecal junction, and colon with no loss of layering, 1:3 muscularis to mucosa ratio, normal wall thickness and peristaltic activity, and no distension of the lumen.

SPECIES

Canine

BREED

Cockapoo

Pancreas

The visible sections of the pancreas are of normal size and echogenic appearance with a regular capsule. Normal echogenic appearance of the mesentery and fat surrounding the pancreas.

SEX

Neutered male

Free Abdomen

Normal mesenteric lymph nodes.

AGE

10 years

No ascites evident.

WEIGHT

11.3 lbs

ULTRASONOGRAPHIC FINDINGS

- Normal ultrasound examination of the abdomen.

INTERPRETED BY

Remo Lobetti, BVSc,
MMedVet (Med),
PhD, Dipl. ECVIM

INTERPRETATION OF THE FINDINGS & FURTHER RECOMMENDATIONS

On this ultrasound there is no obvious etiology for the anemia.

Further assessment would be based on the classification of the anemia, but could include Coomb's/NSAID agglutination test, fecal, occult blood determination, screening for vector borne disease and possibly bone marrow aspirate/cytology.

IMAGING PERFORMED BY

Kerri Becker

Specific therapy would be dependent on an etiological diagnosis.

HOSPITAL NAME

Kenilworth AH

REFERRING VET

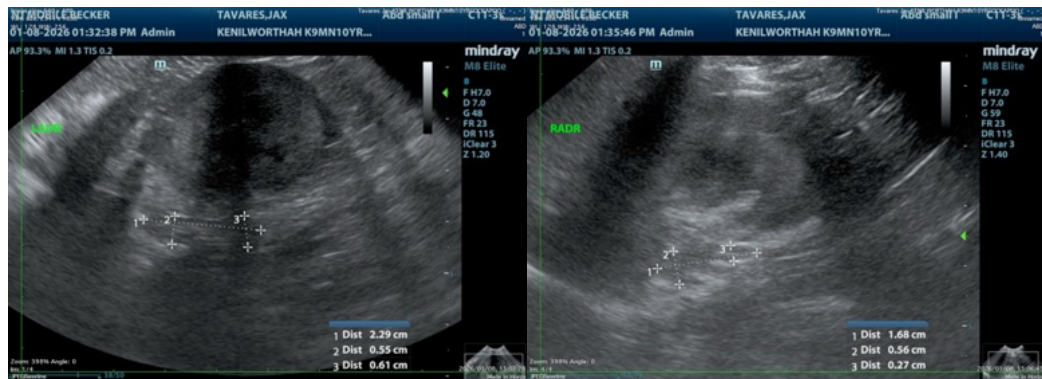
Dr. Mansour

INVOICE

69961

DATE

1/8/26





PATIENT

Jax Tavares

SPECIES

Canine

BREED

Cockapoo

SEX

Neutered male

AGE

10 years

WEIGHT

11.3 lbs

INTERPRETED BY

Remo Lobetti, BVSc,
 MMedVet (Med),
 PhD, Dipl. ECVIM

IMAGING PERFORMED BY

Kerri Becker

HOSPITAL NAME

Kenilworth AH

REFERRING VET

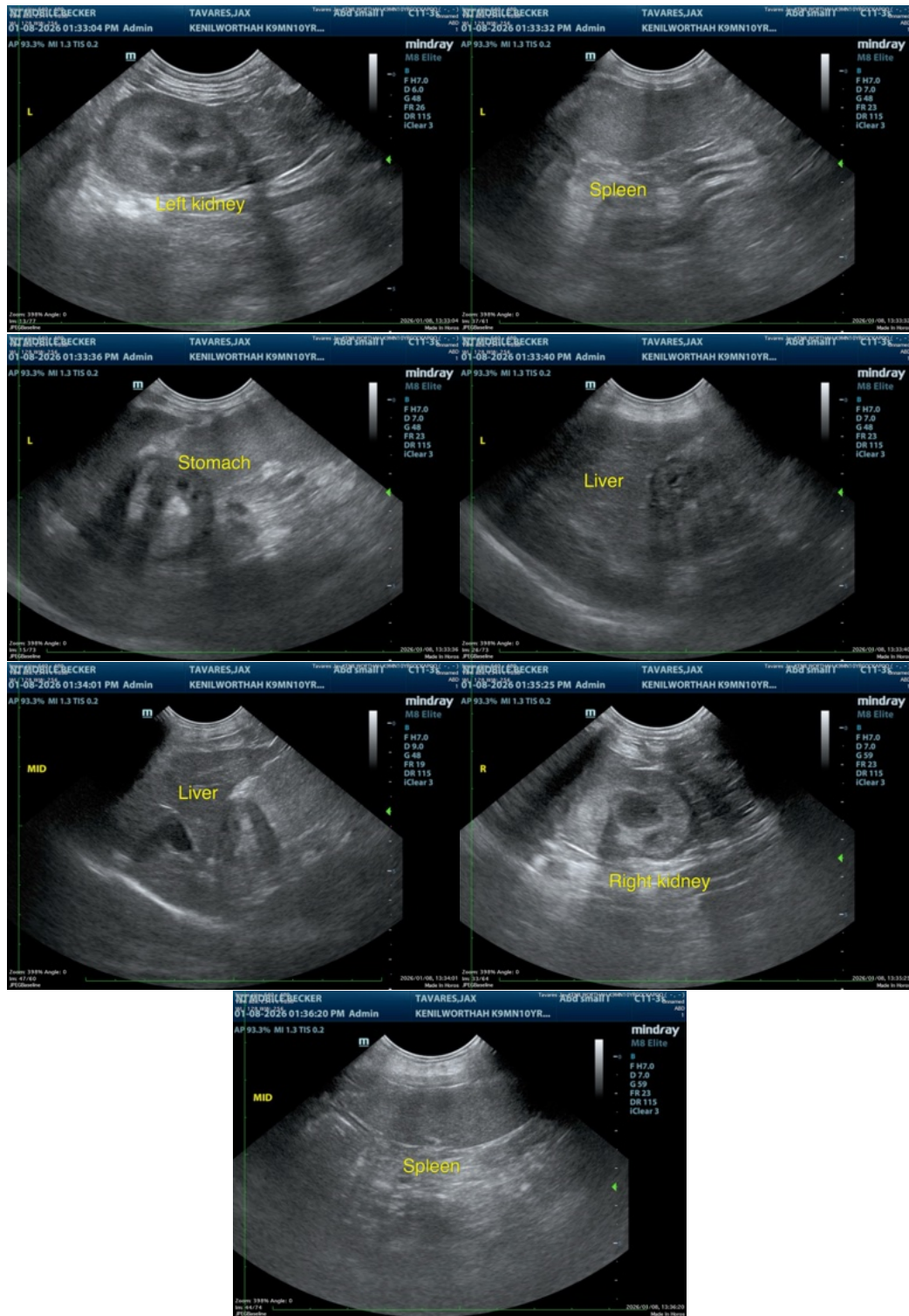
Dr. Mansour

INVOICE

69961

DATE

1/8/26



The information and recommendations provided are based on the images presented by the referring veterinarian/sonographer. No evaluation can be communicated regarding pathology



PATIENT

Jax Tavares

that was not visible in the image/video clips provided.

Thank you for this referral. If the clinical or image interpretation does not parallel your findings or if I can be of any further assistance please contact me.

SPECIES

Canine

Remo Lobetti, BVSc, MMedVet (Med), PhD, Dipl. ECVIM (Internal Medicine)

info@sonopath.com

BREED

Cockapoo

SEX

Neutered male

AGE

10 years

WEIGHT

11.3 lbs

INTERPRETED BY

Remo Lobetti, BVSc,
MMedVet (Med),
PhD, Dipl. ECVIM

IMAGING PERFORMED BY

Kerri Becker

HOSPITAL NAME

Kenilworth AH

REFERRING VET

Dr. Mansour

INVOICE

69961

DATE

1/8/26