



**PATIENT**

Jellyroll Real Dog  
Rescue

**SPECIES**

Canine

**BREED**

American Bully

**SEX**

Male

**AGE**

2 years

**WEIGHT**

46 lbs

**INTERPRETED BY**

Remo Lobetti, BVSc,  
MMedVet (Med),  
PhD, Dipl. ECVIM

**IMAGING  
PERFORMED BY**

Kerri Becker

**HOSPITAL NAME**

Bergen County VC

**REFERRING VET**

Dr. Moore

**INVOICE**

69910

**DATE**

1/7/26

**PRESENTING CLINICAL SIGNS**

History: 2-3/6 left sided HM- regurgitation.  
Abnormal PE/Chem/CBC/UA Results: None

**ULTRASONOGRAPHIC EXAMINATION OF THE ABDOMEN**

**Urinary System**

The urinary bladder is small with a normal thickness and smooth appearance of the wall. Normal anechoic urine with no sediment or uroliths evident.

Normal appearance of the trigone area, proximal urethra, and iliac blood vessels.

Normal appearance and size of the iliac lymph nodes. Ureters not visualized, which can be considered a normal finding.

Normal renal size (left measured 5.1 cm, right measured 6.4 cm), architecture, echogenic appearance, cortico-medullary differentiation, which maintains a 1:3 cortex to medulla ratio, pelvis, and capsule. No infarcts, mineralization or renoliths evident. Normal color flow pattern is evident in both kidneys.

Normal size and appearance of the prostate measuring 1.8 x 2.8 cm in size. Normal size and appearance of both testicles. The left testicle measured 2.6 cm in length and the right testicle measured 2.9 cm in length.

**Adrenal Glands**

Normal shape, echogenic appearance, size, position, and appearance of the visible peri-adrenal vasculature. Left adrenal gland measured 2.02 cm in length x 0.55 cm and 0.54 cm in width. The right adrenal gland measured 1.97 cm in length x 0.52 cm and 0.58 cm in width.

**Spleen**

Normal size and echogenic appearance. Smooth homogenous parenchyma and regular curvilinear capsule. Normal volume of the splenic vasculature without any overt congestion or thrombosis evident. No inflammatory, neoplastic, infarction, or infiltrative changes evident. The spleen measured 2.5 cm, in width.

**Liver**

Normal size, echogenic appearance, portal markings, and regular curvilinear capsule. No nodules or masses evident. Normal appearance of the hepatic and portal vasculature.



**PATIENT**

Jellyroll Real Dog  
Rescue

**SPECIES**

Canine

**BREED**

American Bully

**SEX**

Male

**AGE**

2 years

**WEIGHT**

46 lbs

**INTERPRETED BY**

Remo Lobetti, BVSc,  
MMedVet (Med),  
PhD, Dipl. ECVIM

**IMAGING  
PERFORMED BY**

Kerri Becker

**HOSPITAL NAME**

Bergen County VC

**REFERRING VET**

Dr. Moore

**INVOICE**

69910

**DATE**

1/7/26

***Gallbladder***

The gallbladder is full containing normal anechoic bile. Normal thickness and echogenic appearance of the wall. Normal size and appearance of the cystic and common bile duct.

***Gastrointestinal***

Normal appearance of the stomach, duodenum, small intestine, ileo-cecal junction, and colon with no loss of layering, 1:3 muscularis to mucosa ratio, normal wall thickness and peristaltic activity, and no distension of the lumen.

***Pancreas***

The visible sections of the pancreas are of normal size and echogenic appearance with a regular capsule. Normal echogenic appearance of the mesentery and fat surrounding the pancreas.

***Free Abdomen***

Normal mesenteric lymph nodes.

No ascites evident.

**ULTRASONOGRAPHIC FINDINGS**

- Normal ultrasound examination of the abdomen.

**INTERPRETATION OF THE FINDINGS & FURTHER RECOMMENDATIONS**

On this ultrasound there is no obvious etiology for the regurgitation. With the breed and the patient's age etiologies to consider for the regurgitation would be a sliding hiatal hernia and reflux esophagitis.

Further assessment that can be considered would be endoscopy of the upper GI tract.

Specific therapy would be dependent on an etiological diagnosis.

Symptomatic management would be gastric protectants (Sucralfate, Omeprazole), Metoclopramide and feeding small frequent meals.



**PATIENT**

Jellyroll Real Dog Rescue

**SPECIES**

Canine

**BREED**

American Bully

**SEX**

Male

**AGE**

2 years

**WEIGHT**

46 lbs

**INTERPRETED BY**

Remo Lobetti, BVSc,  
 MMedVet (Med),  
 PhD, Dipl. ECVIM

**IMAGING PERFORMED BY**

Kerri Becker

**HOSPITAL NAME**

Bergen County VC

**REFERRING VET**

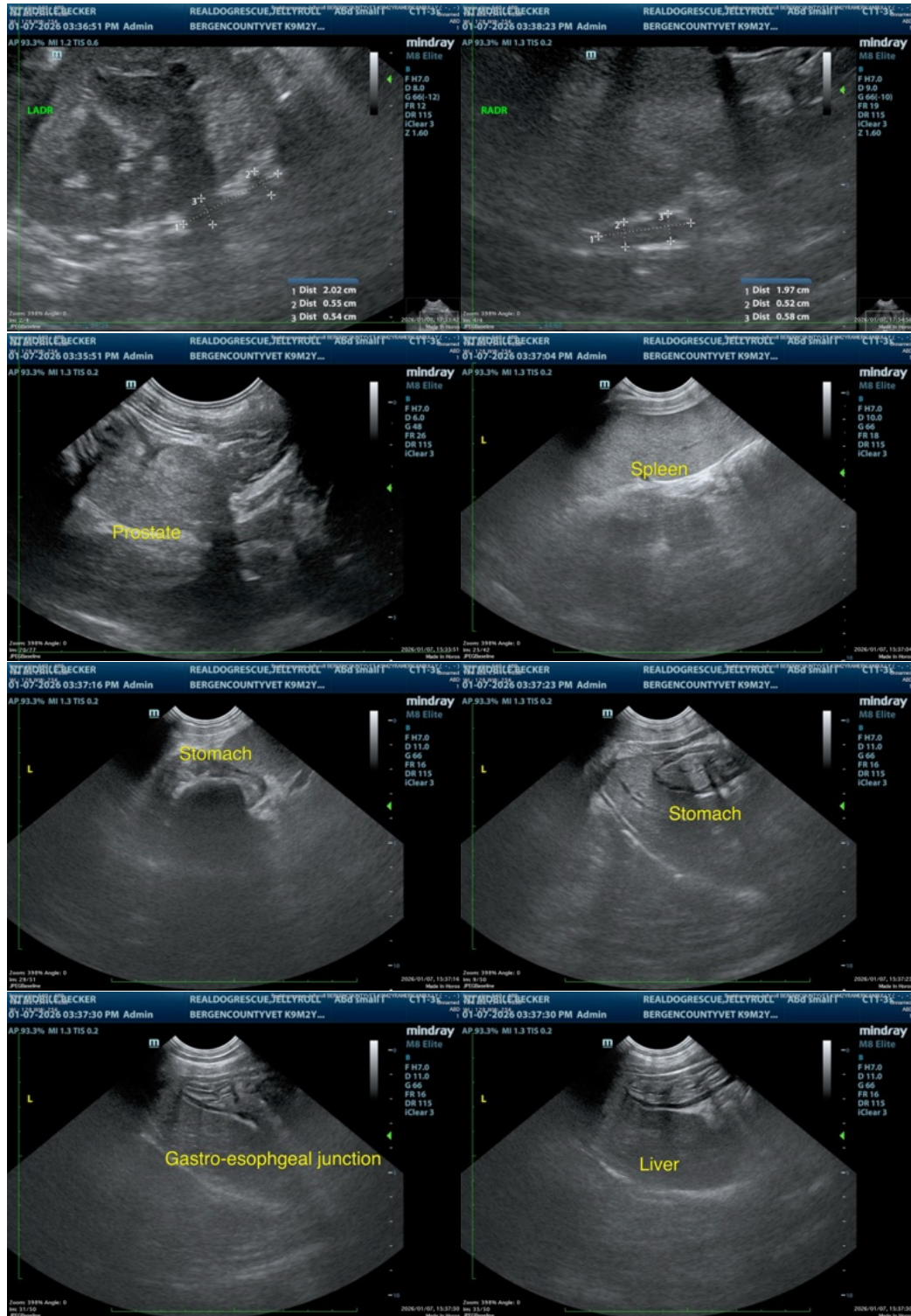
Dr. Moore

**INVOICE**

69910

**DATE**

1/7/26





**PATIENT**

Jellyroll Real Dog  
Rescue

**SPECIES**

Canine

**BREED**

American Bully

**SEX**

Male

**AGE**

2 years

**WEIGHT**

46 lbs

**INTERPRETED BY**

Remo Lobetti, BVSc,  
MMedVet (Med),  
PhD, Dipl. ECVIM

**IMAGING  
PERFORMED BY**

Kerri Becker

**HOSPITAL NAME**

Bergen County VC

**REFERRING VET**

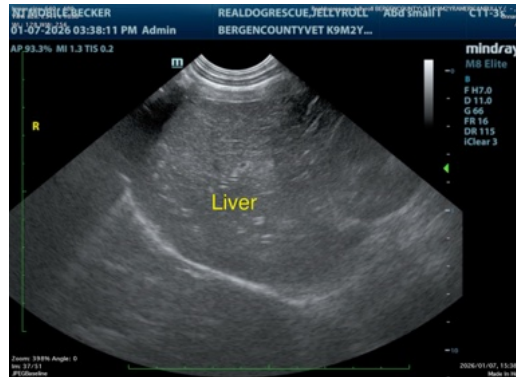Dr. Moore

**INVOICE**

69910

**DATE**

1/7/26



The information and recommendations provided are based on the images presented by the referring veterinarian/sonographer. No evaluation can be communicated regarding pathology that was not visible in the image/video clips provided.

Thank you for this referral. If the clinical or image interpretation does not parallel your findings or if I can be of any further assistance please contact me.

Remo Lobetti, BVSc, MMedVet (Med), PhD, Dipl. ECVIM (Internal Medicine)

[info@sonopath.com](mailto:info@sonopath.com)