



**PATIENT**

Champ Richman

**SPECIES**

Canine

**BREED**

Mix

**SEX**

Neutered male

**AGE**

5 ½ years

**WEIGHT**

57 lbs

**INTERPRETED BY**

Remo Lobetti, BVSc,  
MMedVet (Med),  
PhD, Dipl. ECVIM

**IMAGING PERFORMED BY**

Kerri Becker

**HOSPITAL NAME**

Newbridge VH

**REFERRING VET**

Dr. Glennon

**INVOICE**

69919

**DATE**

1/7/26

**PRESENTING CLINICAL SIGNS**

History: Pancreatitis, vomiting blood IVF, unasyn, cerenia, panoquell  
Abnormal PE/Chem/CBC/UA Results: Lipase 3600

**ULTRASONOGRAPHIC EXAMINATION OF THE ABDOMEN**

**Urinary System**

The urinary bladder is small with a normal thickness and smooth appearance of the wall. Normal anechoic urine with no sediment or uroliths evident.

Normal appearance of the trigone area, proximal urethra, and iliac blood vessels.

Normal appearance and size of the iliac lymph nodes. Ureters not visualized, which can be considered a normal finding.

Normal renal size (left measured 5.6 cm, right measured 5.8 cm), architecture, echogenic appearance, cortico-medullary differentiation, which maintains a 1:3 cortex to medulla ratio, pelvis, and capsule. No infarcts, mineralization or renoliths evident.

The prostate is small and hypoechogenic.

**Adrenal Glands**

Normal shape, echogenic appearance, size, position, and appearance of the visible peri-adrenal vasculature. Left adrenal gland measured 2.2 cm in length x 0.46 cm and 0.51 cm in width. The right adrenal gland measured 2.89 cm in length x 0.64 cm in width.

**Spleen**

Normal size and echogenic appearance. Smooth homogenous parenchyma and regular curvilinear capsule. Normal volume of the splenic vasculature without any overt congestion or thrombosis evident. No inflammatory, neoplastic, infarction, or infiltrative changes evident. The spleen measured 2.2 cm in width.

**Liver**

Normal size, echogenic appearance, portal markings, and regular curvilinear capsule. No nodules or masses evident. Normal appearance of the hepatic and portal vasculature.

**Gallbladder**

The gallbladder is small containing normal anechoic bile. Normal thickness and echogenic appearance of the wall. Normal size and appearance of the cystic and common bile duct.



**PATIENT**

Champ Richman

**SPECIES**

Canine

**BREED**

Mix

**SEX**

Neutered male

**AGE**

5 ½ years

**WEIGHT**

57 lbs

**INTERPRETED BY**

Remo Lobetti, BVSc,  
MMedVet (Med),  
PhD, Dipl. ECVIM

**IMAGING PERFORMED BY**

Kerri Becker

**HOSPITAL NAME**

Newbridge VH

**REFERRING VET**

Dr. Glennon

**INVOICE**

69919

**DATE**

1/7/26

**Gastrointestinal**

Normal appearance of the stomach, duodenum, small intestine, ileo-cecal junction, and colon with no loss of layering, 1:3 muscularis to mucosa ratio, normal wall thickness and peristaltic activity, and no distension of the lumen. A small amount of ingesta is present in the stomach.

**Pancreas**

Normal size (left pancreas measured 1.6 cm in width) with a mottled echogenic appearance and an irregular capsule. Mild increased echogenic appearance of the mesentery and fat surrounding the pancreas.

**Free Abdomen**

Normal mesenteric lymph nodes.

No ascites evident.

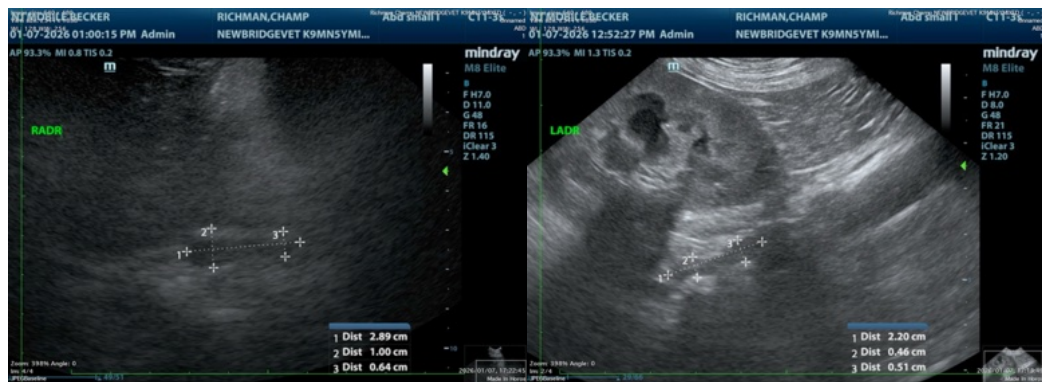
**ULTRASONOGRAPHIC FINDINGS**

- Pancreatitis.

**INTERPRETATION OF THE FINDINGS & FURTHER RECOMMENDATIONS**

Further assessment that can be considered would be CPL/PSL assay.

Management of the pancreatitis would be to continue with the current therapy adding opioid analgesics and feeding small frequent meals of a low fat intestinal type diet.





**PATIENT**

Champ Richman

**SPECIES**

Canine

**BREED**

Mix

**SEX**

Neutered male

**AGE**

5 ½ years

**WEIGHT**

57 lbs

**INTERPRETED BY**

Remo Lobetti, BVSc,  
 MMedVet (Med),  
 PhD, Dipl. ECVIM

**IMAGING PERFORMED BY**

Kerri Becker

**HOSPITAL NAME**

Newbridge VH

**REFERRING VET**

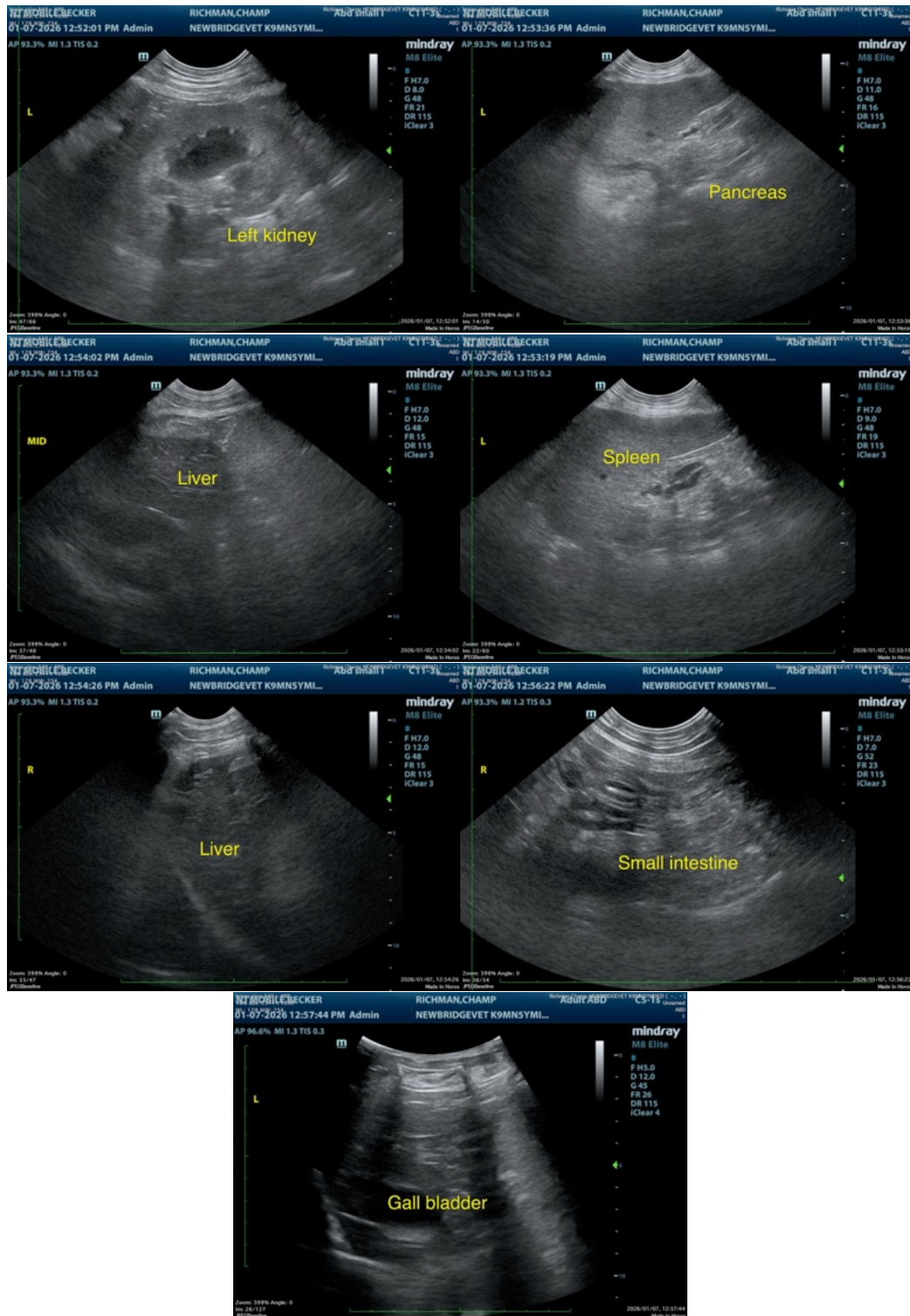
Dr. Glennon

**INVOICE**

69919

**DATE**

1/7/26



The information and recommendations provided are based on the images presented by the referring veterinarian/sonographer. No evaluation can be communicated regarding pathology



**PATIENT**

Champ Richman

**SPECIES**

Canine

**BREED**

Mix

**SEX**

Neutered male

**AGE**

5 ½ years

**WEIGHT**

57 lbs

**INTERPRETED BY**

Remo Lobetti, BVSc,  
MMedVet (Med),  
PhD, Dipl. ECVIM

**IMAGING PERFORMED BY**

Kerri Becker

**HOSPITAL NAME**

Newbridge VH

**REFERRING VET**

Dr. Glennon

**INVOICE**

69919

**DATE**

1/7/26

**that was not visible in the image/video clips provided.**

Thank you for this referral. If the clinical or image interpretation does not parallel your findings or if I can be of any further assistance please contact me.

**Remo Lobetti, BVSc, MMedVet (Med), PhD, Dipl. ECVIM (Internal Medicine)**

[info@sonopath.com](mailto:info@sonopath.com)