



PATIENT

Trixie Lynn

SPECIES

Feline

BREED

Domestic Shorthair

SEX

Spayed female

AGE

11 years

WEIGHT

6.7 lbs

INTERPRETED BY

Remo Lobetti, BVSc,
MMedVet (Med),
PhD, Dipl. ECVIM

IMAGING PERFORMED BY

Shari Reffi, CVT

HOSPITAL NAME

VCA Northside AH

REFERRING VET

Dr. Russell

INVOICE

69849

DATE

1/6/26

PRESENTING CLINICAL SIGNS

History: BCS 3/9, chronic vomiting (increase in frequency), underweight. Current medications: Sedation for scan Gabapentin, Torb/Dexdomitor.

Abnormal PE/Chem/CBC/UA Results: AST 212; ALT 590; ALKP 192; Total Bili 3; UA cysto pending.

ULTRASONOGRAPHIC EXAMINATION OF THE ABDOMEN

Urinary System

The urinary bladder is full with a normal thickness and smooth appearance of the wall. A scant amount of floating, hyperechogenic sediment is noted.

Normal appearance of the trigone area, proximal urethra, and iliac blood vessels.

Normal appearance and size of the iliac lymph nodes. Ureters not visualized, which can be considered a normal finding.

Normal renal size (left measured 3.4 cm, right measured 3.9 cm), architecture, echogenic appearance, cortico-medullary differentiation, which maintains a 1:3 cortex to medulla ratio, pelvis, and capsule. No infarcts, mineralization or renoliths evident. Normal color flow pattern is evident in both kidneys.

Adrenal Glands

Normal shape, echogenic appearance, size, position, and appearance of the visible peri-adrenal vasculature. Left adrenal gland measured 0.31 cm in width. The right adrenal gland measured 0.27 cm in width.

Spleen

Normal size and echogenic appearance. Smooth homogenous parenchyma and regular curvilinear capsule. Normal volume of the splenic vasculature without any overt congestion or thrombosis evident. No inflammatory, neoplastic, infarction, or infiltrative changes evident. The spleen measured 0.9 cm in width.

Liver

Normal size with a diffuse, increased echogenic and coarse appearance, normal portal markings, and regular curvilinear capsule. No nodules or masses evident. Normal appearance of the hepatic and portal vasculature.

Gallbladder

The gallbladder is full containing normal anechoic bile. Normal thickness and echogenic appearance of the wall. Normal size and appearance of the cystic and common bile duct.



PATIENT

Trixie Lynn

SPECIES

Feline

BREED

Domestic Shorthair

SEX

Spayed female

AGE

11 years

WEIGHT

6.7 lbs

INTERPRETED BY

Remo Lobetti, BVSc,
MMedVet (Med),
PhD, Dipl. ECVIM

IMAGING PERFORMED BY

Shari Reffi, CVT

HOSPITAL NAME

VCA Northside AH

REFERRING VET

Dr. Russell

INVOICE

69849

DATE

1/6/26

Gastrointestinal

Normal appearance of the stomach, duodenum, ileo-cecal junction, and colon with no loss of layering, 1:3 muscularis to mucosa ratio, normal wall thickness and peristaltic activity, and no distension of the lumen. Normal thickness of the small intestine with no loss of layering, but with a segmental increase in the muscularis to mucosa ratio, normal peristaltic activity and no distension of the lumen.

Pancreas

The visible sections of the pancreas are of normal size and echogenic appearance with a regular capsule. Normal echogenic appearance of the mesentery and fat surrounding the pancreas. The left pancreas measures 0.5 cm in width.

Free Abdomen

Normal mesenteric lymph nodes measuring up to 0.2 x 0.7 cm in size.

No ascites evident.

ULTRASONOGRAPHIC FINDINGS

- Hepatopathy.
- Enteropathy.

INTERPRETATION OF THE FINDINGS & FURTHER RECOMMENDATIONS

Etiologies for the hepatopathy would be reactive hyperplasia, vacuolar and metabolic with hepatitis and infiltrative neoplasia unlikely differential diagnosis.

Etiologies for the enteropathy would be parasitic enteritis, dietary hypersensitivity and inflammatory bowel disease with emerging lymphoma a less likely differential diagnosis.

Further assessment would be fecal analysis, cobalamin, and folate assay, T4 assay (if not already done), FNA cytology of the liver and endoscopy of the upper GI tract with biopsies.

Specific therapy would be dependent on an etiological diagnosis.

Symptomatic management would be feeding a novel protein/hypoallergenic diet, course of Fenbendazole, cobalamin supplementation and if there is still not a satisfactory improvement then a course of Prednisolone would then be indicated.



PATIENT

Trixie Lynn

SPECIES

Feline

BREED

Domestic Shorthair

SEX

Spayed female

AGE

11 years

WEIGHT

6.7 lbs

INTERPRETED BY

Remo Lobetti, BVSc,
MMedVet (Med),
PhD, Dipl. ECVIM

IMAGING PERFORMED BY

Shari Reffi, CVT

HOSPITAL NAME

VCA Northside AH

REFERRING VET

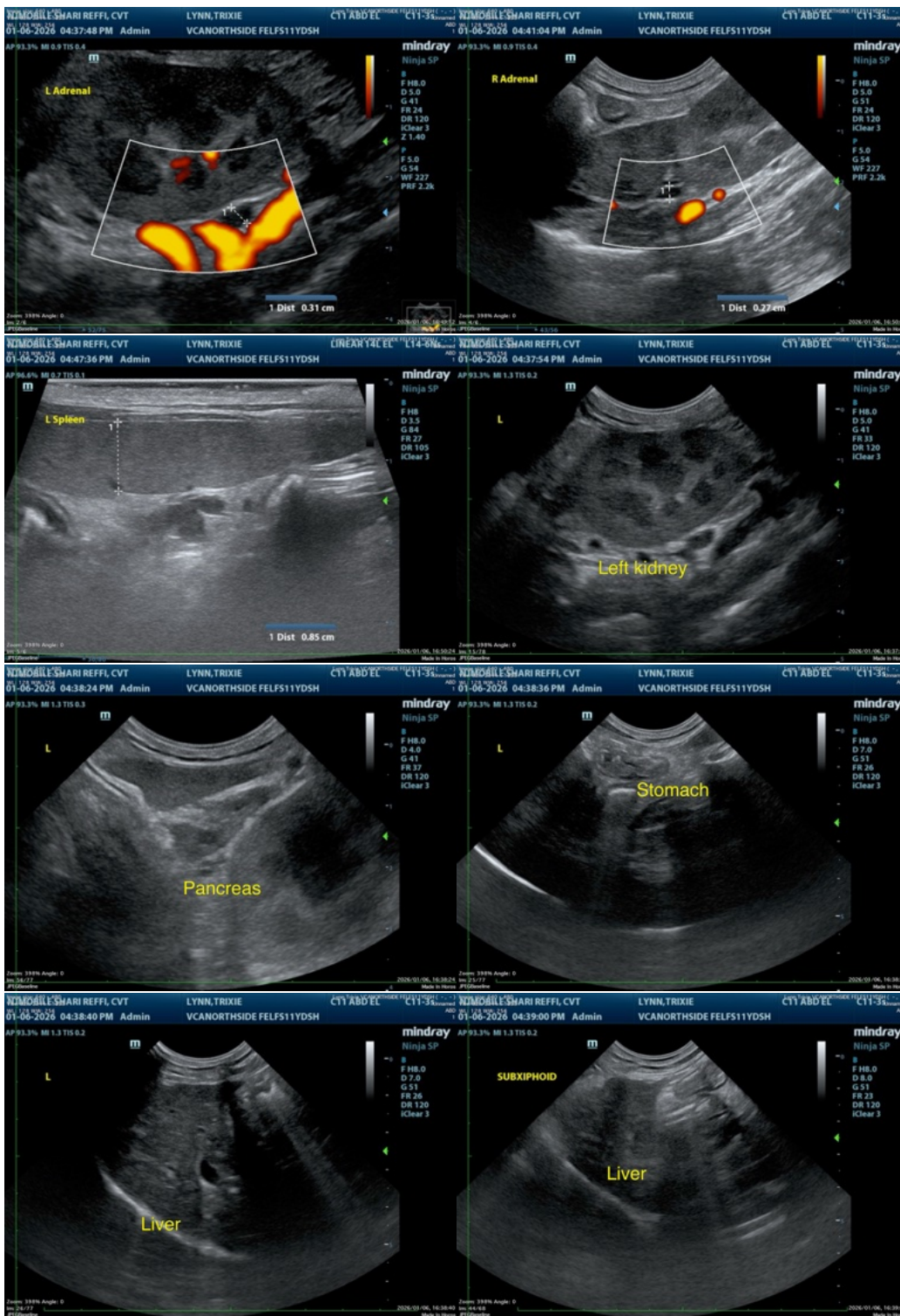
Dr. Russell

INVOICE

69849

DATE

1/6/26





PATIENT

Trixie Lynn

SPECIES

Feline

BREED

Domestic Shorthair

SEX

Spayed female

AGE

11 years

WEIGHT

6.7 lbs

INTERPRETED BY

Remo Lobetti, BVSc,
MMedVet (Med),
PhD, Dipl. ECVIM

IMAGING PERFORMED BY

Shari Reffi, CVT

HOSPITAL NAME

VCA Northside AH

REFERRING VET

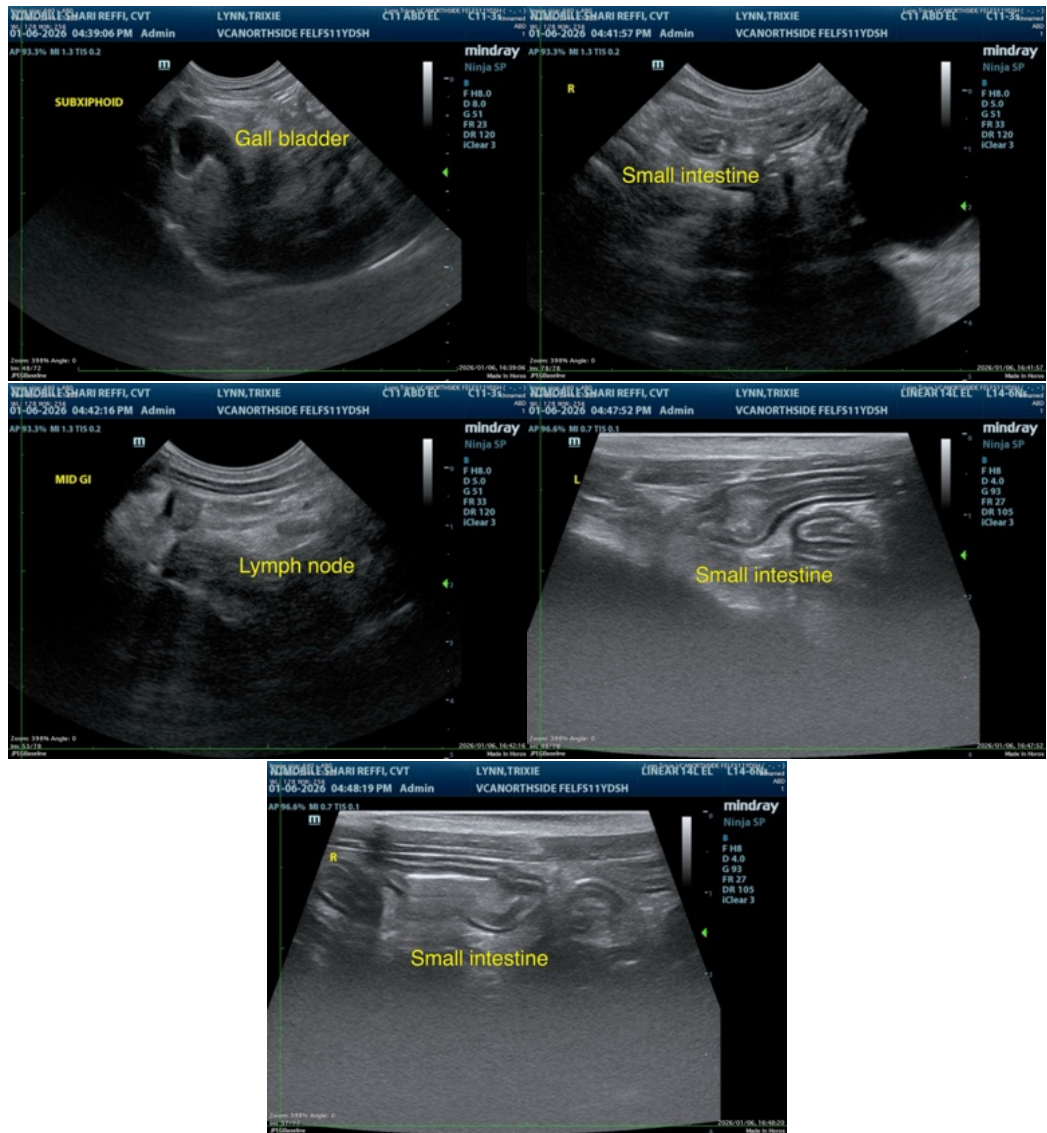
Dr. Russell

INVOICE

69849

DATE

1/6/26



The information and recommendations provided are based on the images presented by the referring veterinarian/sonographer. No evaluation can be communicated regarding pathology that was not visible in the image/video clips provided.

Thank you for this referral. If the clinical or image interpretation does not parallel your findings or if I can be of any further assistance please contact me.

Remo Lobetti, BVSc, MMedVet (Med), PhD, Dipl. ECVIM (Internal Medicine)

info@sonopath.com