



PATIENT

Sasha Chernysheva

SPECIES

Canine

BREED

Japanese Chin

SEX

Spayed female

AGE

12 years

WEIGHT

7.4 lbs

INTERPRETED BY

Remo Lobetti, BVSc,
MMedVet (Med),
PhD, Dipl. ECVIM

IMAGING PERFORMED BY

Dr. Ken Leal

HOSPITAL NAME

Whippany VH

REFERRING VET

Dr. Cordero

INVOICE

69848

DATE

1/6/26

PRESENTING CLINICAL SIGNS

History: Left adrenal gland removed previously. No c/s 6 month followup Medications: K+ citrate, Renal chews.

ULTRASONOGRAPHIC EXAMINATION OF THE ABDOMEN

Urinary System

The urinary bladder is full with a normal thickness and smooth appearance of the wall. Normal anechoic urine with no sediment or uroliths evident.

Normal appearance of the trigone area, proximal urethra, and iliac blood vessels.

Normal appearance and size of the iliac lymph nodes. Ureters not visualized, which can be considered a normal finding.

Normal renal size (left measured 3.2 cm, right measured 3.0 cm,), increased echogenic appearance, some loss of cortico-medullary differentiation, and normal pelvis and capsule. No infarcts evident. Bilateral pinpoint mineralization is present. A few, small, bilateral, non-obstructive renoliths evident.

Adrenal Glands

The left adrenal gland is absent (previous adrenalectomy). Normal appearance of the anatomical area of the left adrenal gland.

The right adrenal gland is normal in shape, echogenic appearance, size, position, and appearance of the visible peri-adrenal vasculature. The right adrenal gland measured 1.93 cm in length x 0.57 cm and 0.63 cm in width.

Spleen

Normal size and echogenic appearance. Smooth homogenous parenchyma and regular curvilinear capsule. Normal volume of the splenic vasculature without any overt congestion or thrombosis evident. No inflammatory, neoplastic, infarction, or infiltrative changes evident. The spleen measured 0.9 cm in width.

Liver

Normal size, echogenic appearance, portal markings, and regular curvilinear capsule. No nodules or masses evident. Normal appearance of the hepatic and portal vasculature.

Gallbladder

The gallbladder is full containing normal anechoic bile. Normal thickness and echogenic appearance of the wall. Normal size and appearance of the cystic and common bile duct.



PATIENT

Sasha Chernysheva

SPECIES

Canine

BREED

Japanese Chin

SEX

Spayed female

AGE

12 years

WEIGHT

7.4 lbs

INTERPRETED BY

Remo Lobetti, BVSc,
MMedVet (Med),
PhD, Dipl. ECVIM

IMAGING PERFORMED BY

Dr. Ken Leal

HOSPITAL NAME

Whippany VH

REFERRING VET

Dr. Cordero

INVOICE

69848

DATE

1/6/26

Gastrointestinal

Normal appearance of the stomach, duodenum, small intestine, ileo-cecal junction, and colon with no loss of layering, 1:3 muscularis to mucosa ratio, normal wall thickness and peristaltic activity, and no distension of the lumen.

Pancreas

The visible sections of the pancreas are of normal size and echogenic appearance with a regular capsule. Normal echogenic appearance of the mesentery and fat surrounding the pancreas.

Free Abdomen

Normal mesenteric lymph nodes.

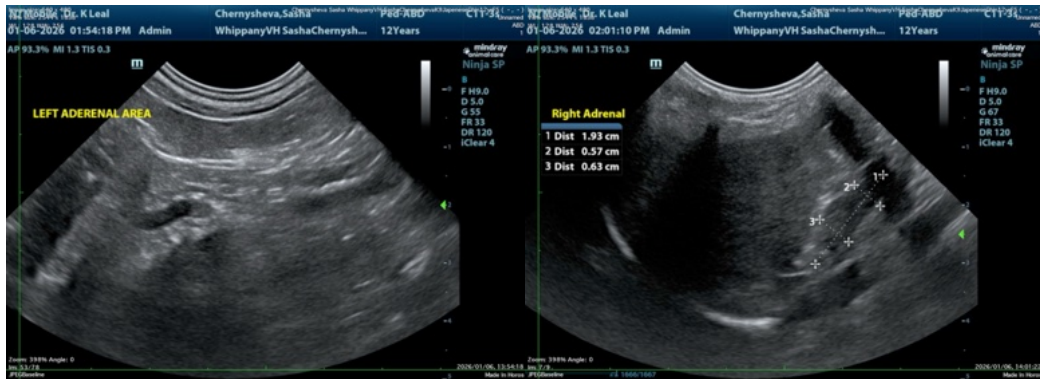
No ascites evident.

ULTRASONOGRAPHIC FINDINGS

- Age related renal changes versus early chronic kidney disease.

INTERPRETATION OF THE FINDINGS & FURTHER RECOMMENDATIONS

On this ultrasound there is no obvious evidence of neoplastic disease.





PATIENT

Sasha Chernysheva

SPECIES

Canine

BREED

Japanese Chin

SEX

Spayed female

AGE

12 years

WEIGHT

7.4 lbs

INTERPRETED BY

Remo Lobetti, BVSc,
 MMedVet (Med),
 PhD, Dipl. ECVIM

IMAGING PERFORMED BY

Dr. Ken Leal

HOSPITAL NAME

Whippany VH

REFERRING VET

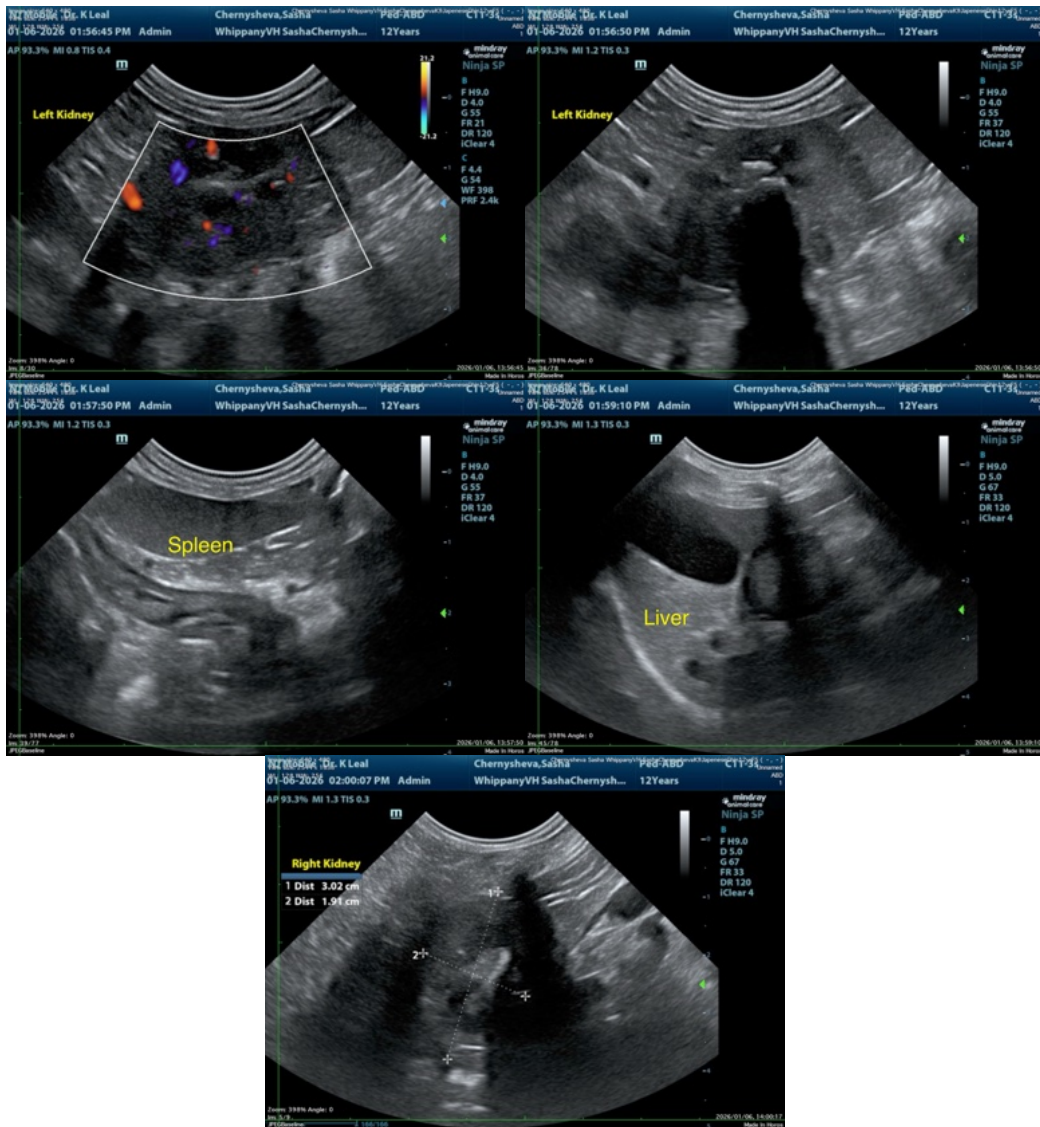
Dr. Cordero

INVOICE

69848

DATE

1/6/26



The information and recommendations provided are based on the images presented by the referring veterinarian/sonographer. No evaluation can be communicated regarding pathology that was not visible in the image/video clips provided.

Thank you for this referral. If the clinical or image interpretation does not parallel your findings or if I can be of any further assistance please contact me.

Remo Lobetti, BVSc, MMedVet (Med), PhD, Dipl. ECVIM (Internal Medicine)

info@sonopath.com