



PATIENT

Buddy Coccia

SPECIES

Feline

BREED

Russian Blue Mix

SEX

Neutered male

AGE

16 years

WEIGHT

7.7 lbs

INTERPRETED BY

Remo Lobetti, BVSc,
MMedVet (Med),
PhD, Dipl. ECVIM

IMAGING PERFORMED BY

Dr. Ken Leal

HOSPITAL NAME

Whippany VH

REFERRING VET

Dr. Enoch

INVOICE

69856

DATE

1/6/26

PRESENTING CLINICAL SIGNS

History: Met check Patient has round cell neoplasia in Right tarsus. Right tarsal and Right popliteal swelling noted. Weight loss. BCS = 3/9 Medication: Solensia injections monthly
Abnormal PE/Chem/CBC/UA Results: 12/0/25: PCV = 30%, neutro 9525, mono 762, BUN 43, SDMA 27.8

ULTRASONOGRAPHIC EXAMINATION OF THE ABDOMEN

Urinary System

The urinary bladder is full with a normal thickness and smooth appearance of the wall. Normal anechoic urine with no sediment or uroliths evident.

Normal appearance of the trigone area, proximal urethra, and iliac blood vessels.

Enlarged iliac lymph nodes measuring 1.0 x 2.2 cm in size with a rounded shape and hypoechoic appearance. Ureters not visualized, which can be considered a normal finding.

Normal renal size (left measured 3.7 cm, right measured 4.3 cm), with increased echogenic appearance, loss of cortico-medullary differentiation, bilateral pyelectasia and a regular curvilinear capsule. No infarcts, mineralization or renoliths evident. Normal color flow pattern is evident in both kidneys.

Adrenal Glands

Normal shape, echogenic appearance, size, position, and appearance of the visible peri-adrenal vasculature. Left adrenal gland measured 0.41 cm in width. The right adrenal gland measured 0.5 cm in width.

Spleen

Normal size and echogenic appearance. Smooth homogenous parenchyma and regular curvilinear capsule. Normal volume of the splenic vasculature without any overt congestion or thrombosis evident. No inflammatory, neoplastic, infarction, or infiltrative changes evident. The spleen measured 0.7 cm in width.

Liver

Normal size, echogenic appearance, portal markings, and regular curvilinear capsule. No nodules or masses evident. Normal appearance of the hepatic and portal vasculature.

Gallbladder

The gallbladder is full containing normal anechoic bile. Normal thickness and echogenic appearance of the wall. Normal size and appearance of the cystic and common bile duct.



PATIENT

Buddy Coccia

SPECIES

Feline

BREED

Russian Blue Mix

SEX

Neutered male

AGE

16 years

WEIGHT

7.7 lbs

INTERPRETED BY

Remo Lobetti, BVSc,
MMedVet (Med),
PhD, Dipl. ECVIM

IMAGING PERFORMED BY

Dr. Ken Leal

HOSPITAL NAME

Whippany VH

REFERRING VET

Dr. Enoch

INVOICE

69856

DATE

1/6/26

Gastrointestinal

Normal appearance of the stomach, duodenum, small intestine, ileo-cecal junction, and colon with no loss of layering, 1:3 muscularis to mucosa ratio, normal wall thickness and peristaltic activity, and no distension of the lumen.

Pancreas

The visible sections of the pancreas are of normal size and echogenic appearance with a regular capsule. Normal echogenic appearance of the mesentery and fat surrounding the pancreas.

Free Abdomen

Enlarged mesenteric lymph nodes measuring up to 0.5 x 1.4 cm in size maintaining a normal shape, but with a hypoechogenic appearance.

No ascites evident.

ULTRASONOGRAPHIC FINDINGS

- Mesenteric and iliac lymphadenomegaly.
- Renal disease.

INTERPRETATION OF THE FINDINGS & FURTHER RECOMMENDATIONS

The appearance of the lymph node would be consistent with round cell neoplasia.

The appearance of the kidneys is consistent with chronic kidney disease although the pyelectasia is most likely associated with the chronic kidney changes. Underlying low grade pyelonephritis should still be considered.

Further assessment would be urinalysis, urine culture and FNA cytology of the lymph nodes.

Further specific therapy would be dependent on an etiological diagnosis.



PATIENT

Buddy Coccia

SPECIES

Feline

BREED

Russian Blue Mix

SEX

Neutered male

AGE

16 years

WEIGHT

7.7 lbs

INTERPRETED BY

Remo Lobetti, BVSc,
MMedVet (Med),
PhD, Dipl. ECVIM

IMAGING PERFORMED BY

Dr. Ken Leal

HOSPITAL NAME

Whippany VH

REFERRING VET

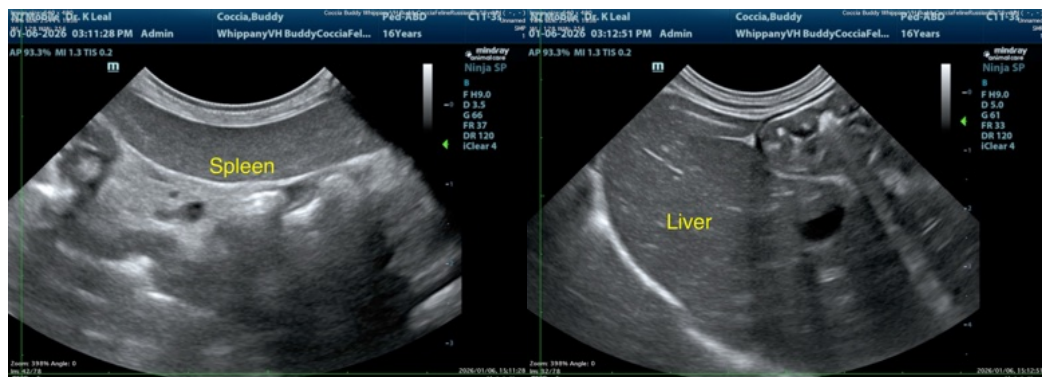
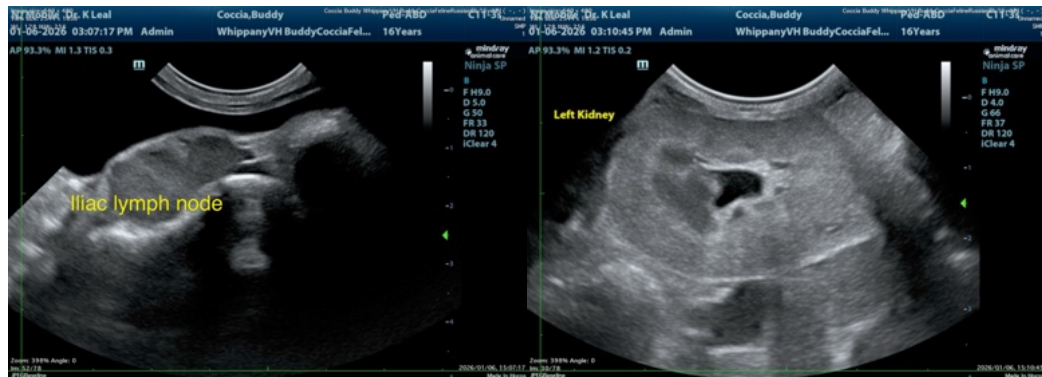
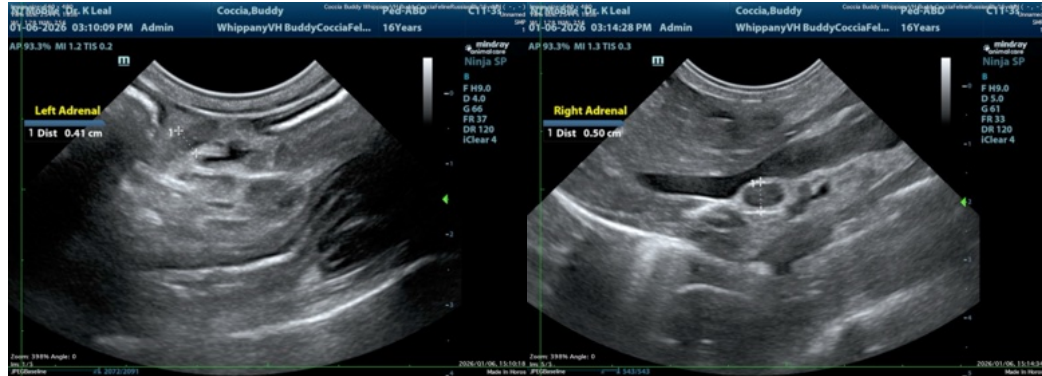
Dr. Enoch

INVOICE

69856

DATE

1/6/26





PATIENT

Buddy Coccia

SPECIES

Feline

BREED

Russian Blue Mix

SEX

Neutered male

AGE

16 years

WEIGHT

7.7 lbs

INTERPRETED BY

Remo Lobetti, BVSc,
MMedVet (Med),
PhD, Dipl. ECVIM

IMAGING PERFORMED BY

Dr. Ken Leal

HOSPITAL NAME

Whippany VH

REFERRING VET

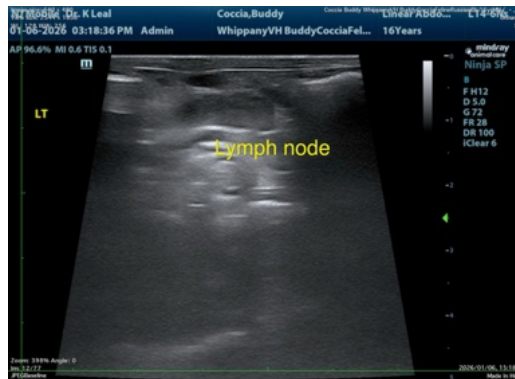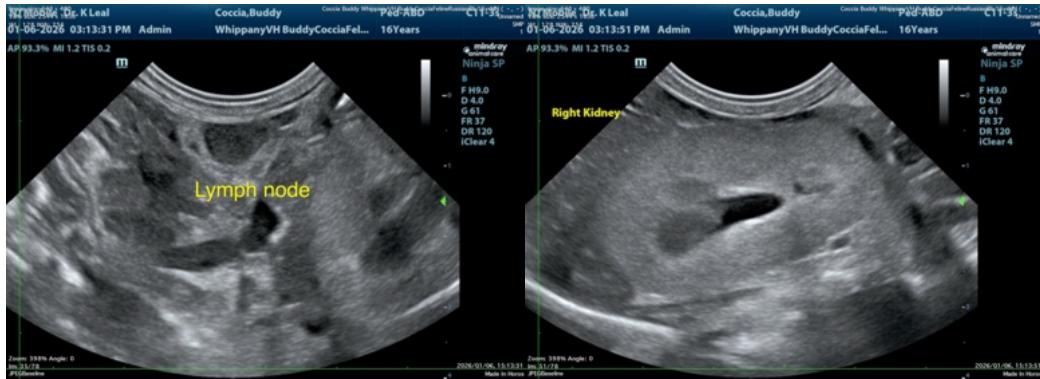
Dr. Enoch

INVOICE

69856

DATE

1/6/26



The information and recommendations provided are based on the images presented by the referring veterinarian/sonographer. No evaluation can be communicated regarding pathology that was not visible in the image/video clips provided.

Thank you for this referral. If the clinical or image interpretation does not parallel your findings or if I can be of any further assistance please contact me.

Remo Lobetti, BVSc, MMedVet (Med), PhD, Dipl. ECVIM (Internal Medicine)

info@sonopath.com