



## PATIENT

Oscar Cunniffe

## SPECIES

Canine Pitbull Mix

## BREED

Pit Mix

## SEX

Neutered male

## AGE

5 ½ years

## WEIGHT

65 lbs

## INTERPRETED BY

Remo Lobetti, BVSc,  
MMedVet (Med),  
PhD, Dipl. ECVIM

## IMAGING PERFORMED BY

Dr. Ken Leal

## HOSPITAL NAME

Blairstown AH

## REFERRING VET

Dr. Summers

## INVOICE

69784

## DATE

1/5/26

## PRESENTING CLINICAL SIGNS

History: Anemia (referred from another vet) No blood work.  
Abnormal PE/Chem/CBC/UA Results: Not available

## ULTRASONOGRAPHIC EXAMINATION OF THE ABDOMEN

### *Urinary System*

The urinary bladder is full with a normal thickness and smooth appearance of the wall. Normal anechoic urine with no sediment or uroliths evident.

Normal appearance of the trigone area, proximal urethra, and iliac blood vessels.

Normal appearance and size of the iliac lymph nodes (0.54 cm in width). Ureters not visualized, which can be considered a normal finding.

Normal renal size (left measured 6.0 cm, right measured 7.2 cm), architecture, echogenic appearance, cortico-medullary differentiation, which maintains a 1:3 cortex to medulla ratio, pelvis, and capsule. No infarcts, mineralization or renoliths evident. Normal color flow pattern was noted in both kidneys.

The prostate is small and hypoechogenic measuring 1.0 cm in width.

### *Adrenal Glands*

Normal shape, echogenic appearance, size, position, and appearance of the visible peri-adrenal vasculature. Left adrenal gland measured 3.06 cm in length x 0.66 cm and 0.51 cm in width. The right adrenal gland measured 3.32 cm in length x 0.71 cm in width.

### *Spleen*

Normal size and echogenic appearance. Smooth homogenous parenchyma and regular curvilinear capsule. Normal volume of the splenic vasculature without any overt congestion or thrombosis evident. No inflammatory, neoplastic, infarction, or infiltrative changes evident. The spleen measured 1.8 cm in width.

### *Liver*

Normal size, echogenic appearance, portal markings, and regular curvilinear capsule. No nodules or masses evident. Normal appearance of the hepatic and portal vasculature.



**PATIENT**

Oscar Cunniffe

**SPECIES**

Canine Pitbull Mix

**BREED**

Pit Mix

**SEX**

Neutered male

**AGE**

5 ½ years

**WEIGHT**

65 lbs

**INTERPRETED BY**

Remo Lobetti, BVSc,  
MMedVet (Med),  
PhD, Dipl. ECVIM

**IMAGING PERFORMED BY**

Dr. Ken Leal

**HOSPITAL NAME**

Blairstown AH

**REFERRING VET**

Dr. Summers

**INVOICE**

69784

**DATE**

1/5/26

***Gallbladder***

The gallbladder is full containing a small amount of non-adhered, hyperechogenic sediment. Normal thickness and echogenic appearance of the wall. Normal size and appearance of the cystic and common bile duct.

***Gastrointestinal***

Normal appearance of the stomach, duodenum, small intestine, ileo-cecal junction, and colon with no loss of layering, 1:3 muscularis to mucosa ratio, normal wall thickness and peristaltic activity, and no distension of the lumen. Fecal material was present in the colon.

***Pancreas***

The visible sections of the pancreas are of normal size and echogenic appearance with a regular capsule. Normal echogenic appearance of the mesentery and fat surrounding the pancreas.

***Free Abdomen***

Normal mesenteric lymph nodes.

No ascites evident.

**ULTRASONOGRAPHIC FINDINGS**

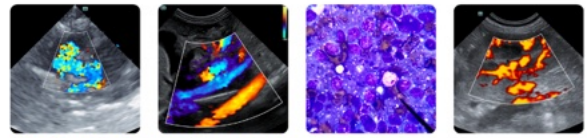
- Gallbladder sediment.

**INTERPRETATION OF THE FINDINGS & FURTHER RECOMMENDATIONS**

In essence a normal ultrasound examination of the abdomen as the gallbladder sediment can be considered an incidental finding.

On this ultrasound there is no obvious etiology for the anemia.

Further assessment would be based on the presenting clinical signs, clinical examination and blood work findings.



**PATIENT**

Oscar Cunniffe

**SPECIES**

Canine Pitbull Mix

**BREED**

Pit Mix

**SEX**

Neutered male

**AGE**

5 ½ years

**WEIGHT**

65 lbs

**INTERPRETED BY**

Remo Lobetti, BVSc,  
 MMedVet (Med),  
 PhD, Dipl. ECVIM

**IMAGING PERFORMED BY**

Dr. Ken Leal

**HOSPITAL NAME**

Blairstown AH

**REFERRING VET**

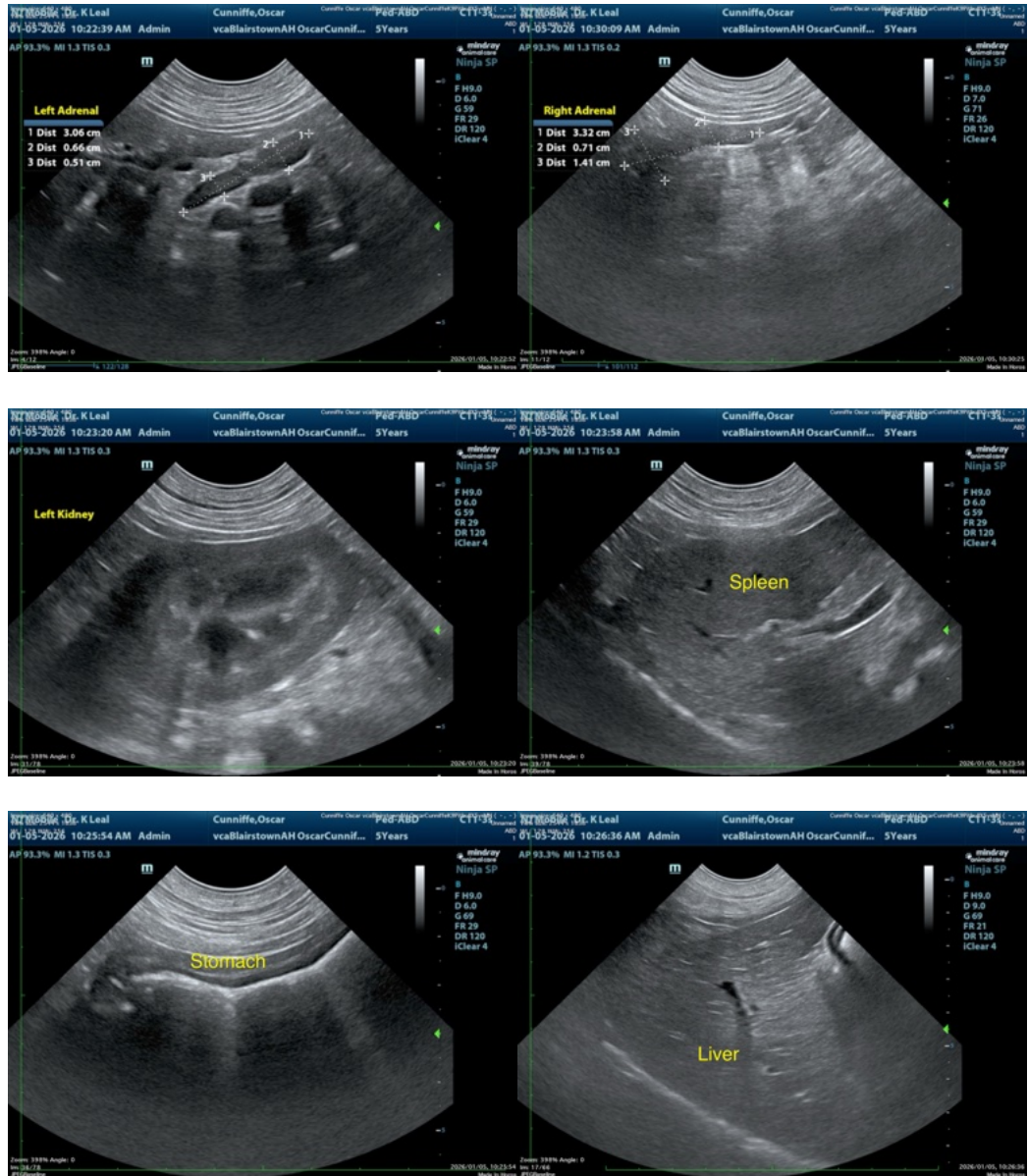
Dr. Summers

**INVOICE**

69784

**DATE**

1/5/26





**PATIENT**

Oscar Cunniffe

**SPECIES**

Canine Pitbull Mix

**BREED**

Pit Mix

**SEX**

Neutered male

**AGE**

5 ½ years

**WEIGHT**

65 lbs

**INTERPRETED BY**

Remo Lobetti, BVSc,  
 MMedVet (Med),  
 PhD, Dipl. ECVIM

**IMAGING PERFORMED BY**

Dr. Ken Leal

**HOSPITAL NAME**

Blairstown AH

**REFERRING VET**

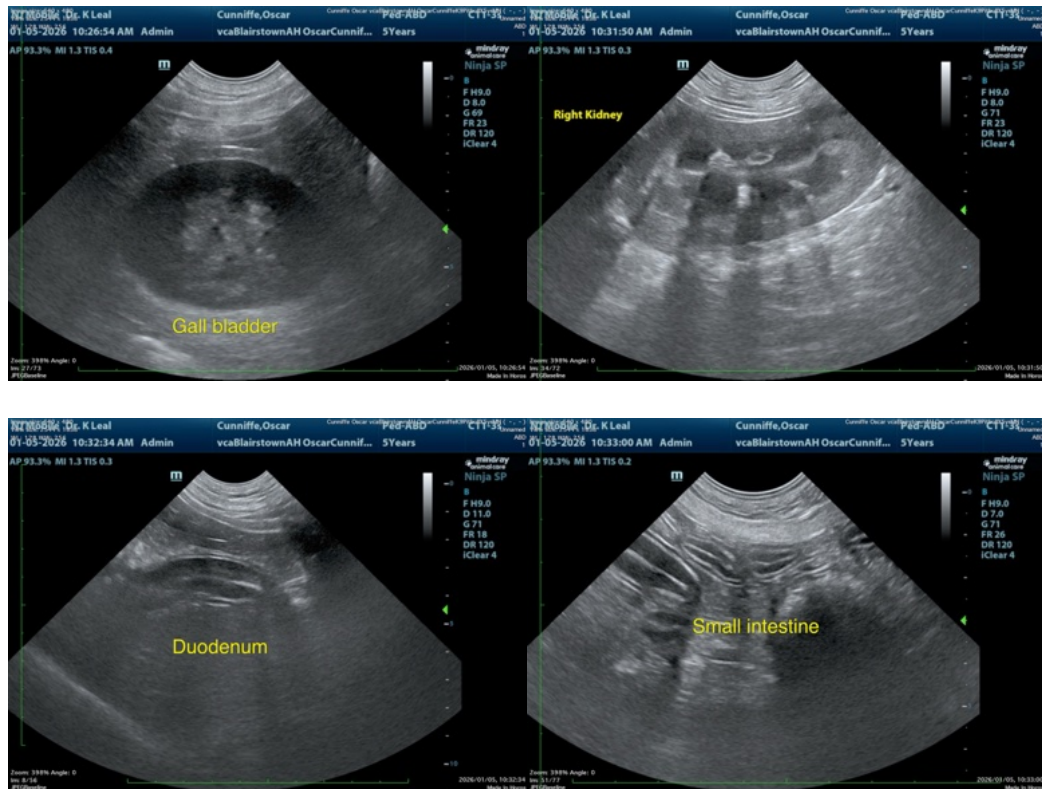
Dr. Summers

**INVOICE**

69784

**DATE**

1/5/26



The information and recommendations provided are based on the images presented by the referring veterinarian/sonographer. No evaluation can be communicated regarding pathology that was not visible in the image/video clips provided.

Thank you for this referral. If the clinical or image interpretation does not parallel your findings or if I can be of any further assistance please contact me.

**Remo Lobetti, BVSc, MMedVet (Med), PhD, Dipl. ECVIM (Internal Medicine)**

[info@sonopath.com](mailto:info@sonopath.com)