



PATIENT

Riley Freelund

SPECIES

Canine

BREED

Golden

SEX

Spayed female

AGE

12 years

WEIGHT

34 lbs

INTERPRETED BY

Remo Lobetti, BVSc,
MMedVet (Med), PhD,
Dipl. ECVIM (Internal
Medicine)

IMAGING PERFORMED BY

Vincent Ravancho,
CVT

HOSPITAL NAME

Millburn VH

REFERRING VET

Dr. Turowsky

INVOICE

71019

DATE

1/28/26

PRESENTING CLINICAL SIGNS

- Progressively elevated liver enzymes
- Recent bout of kennel cough, resolving.
- Hx of bladder stones dissolved with diet
- ALT 123 ALP 1270

ULTRASONOGRAPHIC EXAMINATION OF THE ABDOMEN

Urinary System

The urinary bladder is full with a normal thickness and smooth appearance of the wall. Normal anechoic urine with no sediment or uroliths evident.

Normal appearance of the trigone area, proximal urethra, and iliac blood vessels.

Normal appearance and size of the iliac lymph nodes. Ureters not visualized, which can be considered a normal finding.

Normal renal size (left measured 5.0 cm, right measured 5.8 cm), architecture, echogenic appearance, cortico-medullary differentiation, which maintains a 1:3 cortex to medulla ratio, pelvis, and capsule. No infarcts, mineralization or renoliths evident. Normal color flow pattern is evident in both kidneys.

Adrenal Glands

Normal shape, echogenic appearance, size, position, and appearance of the visible peri-adrenal vasculature. Left adrenal gland measured 2.12 cm in length x 0.71 cm and 0.51 cm in width. The right adrenal gland measured 2.28 cm in length x 0.88 cm and 0.45 cm in width.

Spleen

Normal size and echogenic appearance. Smooth homogenous parenchyma and regular curvilinear capsule. Normal volume of the splenic vasculature without any overt congestion or thrombosis evident. No inflammatory, neoplastic, infarction, or infiltrative changes evident. The spleen measured 1.0 cm in width.

Liver

Normal size with a diffuse, increased echogenic and coarse appearance, prominent portal markings, and regular curvilinear capsule. No nodules or masses evident. Normal appearance of the hepatic and portal vasculature.



PATIENT

Riley Freelund

SPECIES

Canine

BREED

Golden

SEX

Spayed female

AGE

12 years

WEIGHT

34 lbs

INTERPRETED BY

Remo Lobetti, BVSc,
MMedVet (Med), PhD,
Dipl. ECVIM (Internal
Medicine)

**IMAGING
PERFORMED BY**

Vincent Ravancho,
CVT

HOSPITAL NAME

Millburn VH

REFERRING VET

Dr. Turowsky

INVOICE

71019

DATE

1/28/26

Gallbladder

The gallbladder is full containing normal anechoic bile. Normal thickness and echogenic appearance of the wall. Normal size and appearance of the cystic and common bile duct.

Gastrointestinal

Normal appearance of the stomach, duodenum, small intestine, ileo-cecal junction, and colon with no loss of layering, 1:3 muscularis to mucosa ratio, normal wall thickness and peristaltic activity, and no distension of the lumen.

Pancreas

The visible sections of the pancreas are of normal size and echogenic appearance with a regular capsule. Normal echogenic appearance of the mesentery and fat surrounding the pancreas.

Free Abdomen

Normal mesenteric lymph nodes.

No ascites evident.

ULTRASONOGRAPHIC FINDINGS

- Hepatopathy.

INTERPRETATION OF THE FINDINGS & FURTHER RECOMMENDATIONS

The likely etiologies for the hepatopathy would be reactive hyperplasia, early nodular hyperplasia, vacuolar, metabolic and breed specific hepatopathy with hepatitis and infiltrative neoplasia an unlikely differential diagnosis.

Further assessment would be FNA cytology of the liver. However, a tru cut or wedge biopsy may be required for a final etiological diagnosis.

Specific therapy would be dependent on an etiological diagnosis.

Symptomatic management that can be considered would be the use of Ursodiol with regular monitoring of liver enzyme activity.



PATIENT

Riley Freelund

SPECIES

Canine

BREED

Golden

SEX

Spayed female

AGE

12 years

WEIGHT

34 lbs

INTERPRETED BY

Remo Lobetti, BVSc,
 MMedVet (Med), PhD,
 Dipl. ECVIM (Internal
 Medicine)

**IMAGING
 PERFORMED BY**

Vincent Ravancho,
 CVT

HOSPITAL NAME

Millburn VH

REFERRING VET

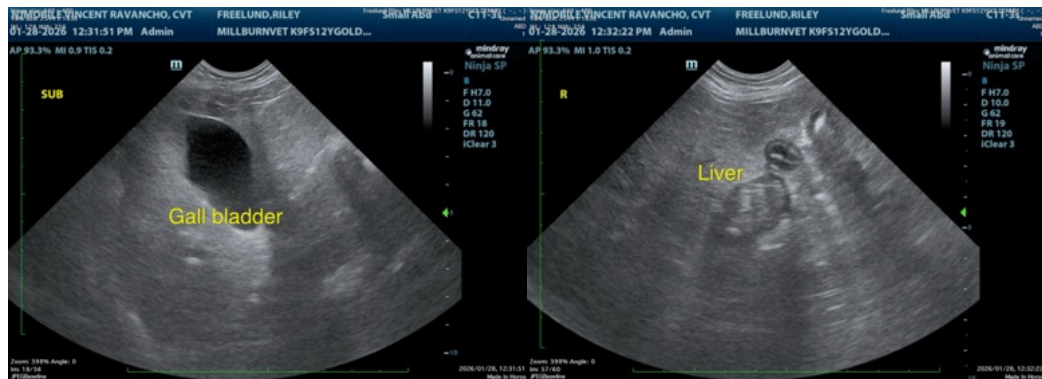
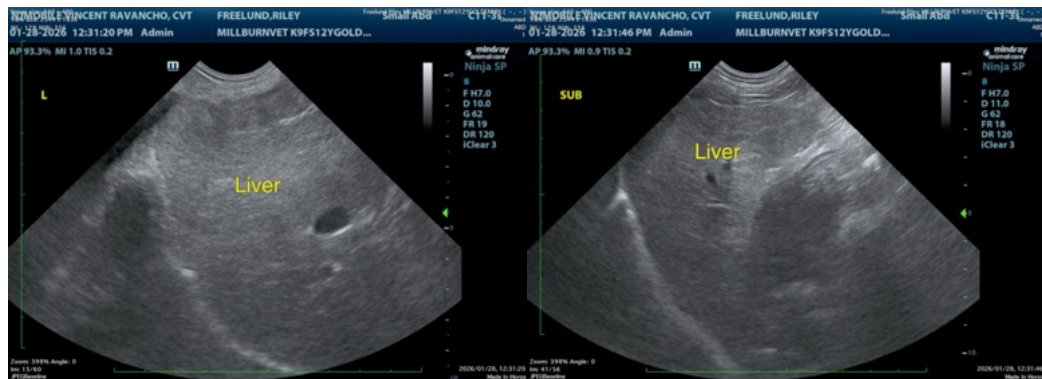
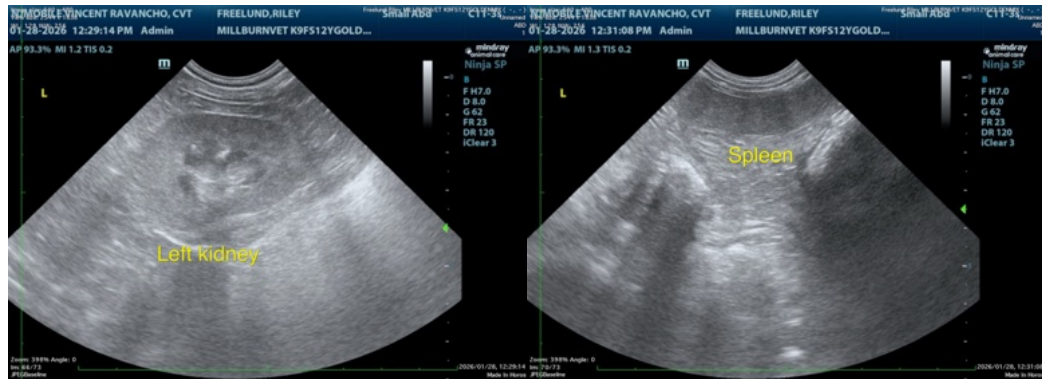
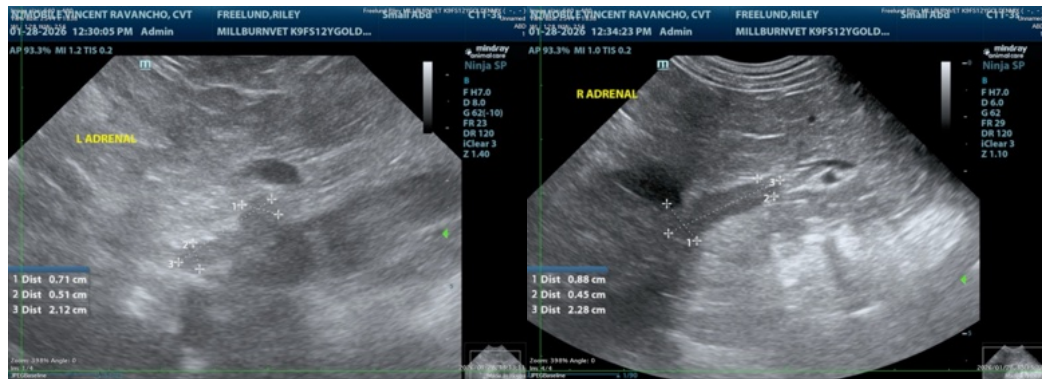
Dr. Turowsky

INVOICE

71019

DATE

1/28/26





PATIENT

Riley Freelund

SPECIES

Canine

BREED

Golden

SEX

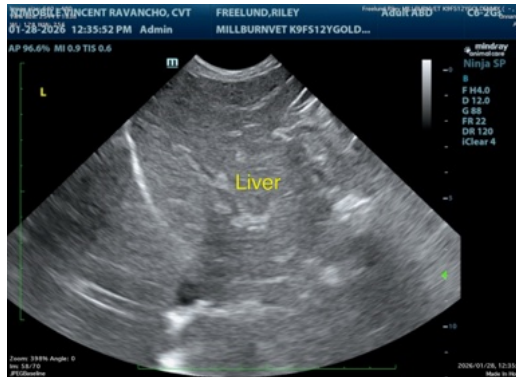Spayed female

AGE

12 years

WEIGHT

34 lbs



The information and recommendations provided are based on the images presented by the referring veterinarian/sonographer. No evaluation can be communicated regarding pathology that was not visible in the image/video clips provided.

Thank you for this referral. If the clinical or image interpretation does not parallel your findings or if I can be of any further assistance please contact me.

Remo Lobetti, BVSc, MMedVet (Med), PhD, Dipl. ECVIM (Internal Medicine)

info@sonopath.com

INTERPRETED BY

Remo Lobetti, BVSc,
MMedVet (Med), PhD,
Dipl. ECVIM (Internal
Medicine)

IMAGING PERFORMED BY

Vincent Ravancho,
CVT

HOSPITAL NAME

Millburn VH

REFERRING VET

Dr. Turowsky

INVOICE

71019

DATE

1/28/26