



## PATIENT

Katara Christian

## SPECIES

Canine

## BREED

Lab Mix

## SEX

Spayed Female

## AGE

5 years

## WEIGHT

69.6 lbs

## INTERPRETED BY

Remo Lobetti, BVSc,  
MMedVet (Med),  
PhD, Dipl. ECVIM

## IMAGING PERFORMED BY

Kerri Becker

## HOSPITAL NAME

Animal General  
Hudson

## REFERRING VET

Dr. Hodges

## INVOICE

71014

## DATE

1/28/26

## PRESENTING CLINICAL SIGNS

- Mass in caudal abd on rads. Blood in urine.

## ULTRASONOGRAPHIC EXAMINATION OF THE ABDOMEN

### *Urinary System*

The urinary bladder is full with a normal thickness and smooth appearance of the wall. Normal anechoic urine with no sediment or uroliths evident.

Normal appearance of the trigone area, proximal urethra, and iliac blood vessels.

Normal appearance and size of the iliac lymph nodes. Ureters not visualized, which can be considered a normal finding.

Normal renal size (left measured 6.0 cm, right measured 6.5 cm), architecture, echogenic appearance, cortico-medullary differentiation, which maintains a 1:3 cortex to medulla ratio, pelvis, and capsule. No infarcts, mineralization or renoliths evident. Normal color flow pattern evident in both kidneys.

### *Adrenal Glands*

Normal shape, echogenic appearance, size, position, and appearance of the visible peri-adrenal vasculature. Left adrenal gland measured 2.25 cm in length x 0.5 cm and 0.48 cm in width. The right adrenal gland measured 2.59 cm in length x 0.57 cm in width.

### *Spleen*

Normal size and echogenic appearance. Smooth homogenous parenchyma and regular curvilinear capsule. Normal volume of the splenic vasculature without any overt congestion or thrombosis evident. No inflammatory, neoplastic, infarction, or infiltrative changes evident. The spleen measured 2.1 cm in width.

### *Liver*

Normal size, echogenic appearance, portal markings, and regular curvilinear capsule. No nodules or masses evident. Normal appearance of the hepatic and portal vasculature.

### *Gallbladder*

The gallbladder is small containing normal anechoic bile. Normal thickness and echogenic appearance of the wall. Normal size and appearance of the cystic and common bile duct.



**PATIENT**

Katara Christian

**SPECIES**

Canine

**BREED**

Lab Mix

**SEX**

Spayed Female

**AGE**

5 years

**WEIGHT**

69.6 lbs

**INTERPRETED BY**

Remo Lobetti, BVSc,  
MMedVet (Med),  
PhD, Dipl. ECVIM

**IMAGING PERFORMED BY**

Kerri Becker

**HOSPITAL NAME**

Animal General  
Hudson

**REFERRING VET**

Dr. Hodges

**INVOICE**

71014

**DATE**

1/28/26

**Gastrointestinal**

Normal appearance of the stomach, duodenum, small intestine, ileo-cecal junction, and colon with no loss of layering, 1:3 muscularis to mucosa ratio, normal wall thickness and peristaltic activity, and no distension of the lumen.

**Pancreas**

The visible sections of the pancreas are of normal size and echogenic appearance with a regular capsule. Normal echogenic appearance of the mesentery and fat surrounding the pancreas.

**Free Abdomen**

Normal mesenteric lymph nodes.

No ascites evident.

**ULTRASONOGRAPHIC FINDINGS**

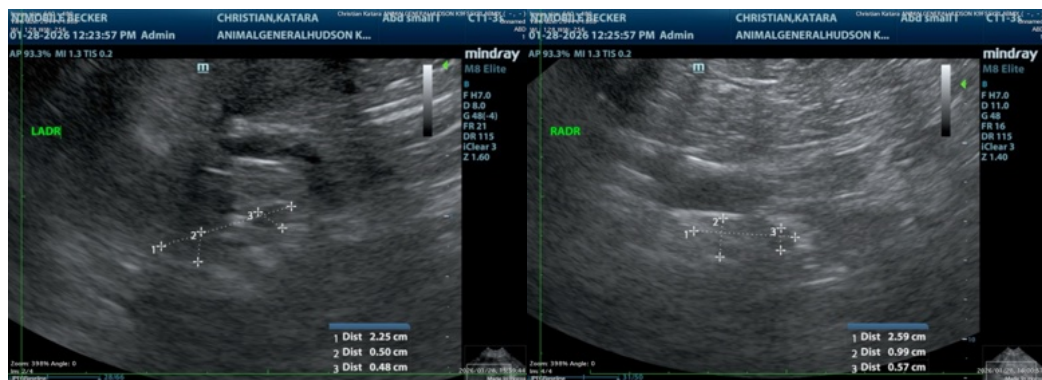
- Normal ultrasound examination of the abdomen.

**INTERPRETATION OF THE FINDINGS & FURTHER RECOMMENDATIONS**

On this ultrasound there is no obvious abdominal mass evident. There is also no obvious etiology for the hematuria.

Further assessment would be urine culture.

Specific therapy would be dependent on an etiological diagnosis.





**PATIENT**

Katara Christian

**SPECIES**

Canine

**BREED**

Lab Mix

**SEX**

Spayed Female

**AGE**

5 years

**WEIGHT**

69.6 lbs

**INTERPRETED BY**

Remo Lobetti, BVSc,  
 MMedVet (Med),  
 PhD, Dipl. ECVIM

**IMAGING PERFORMED BY**

Kerri Becker

**HOSPITAL NAME**

Animal General  
 Hudson

**REFERRING VET**

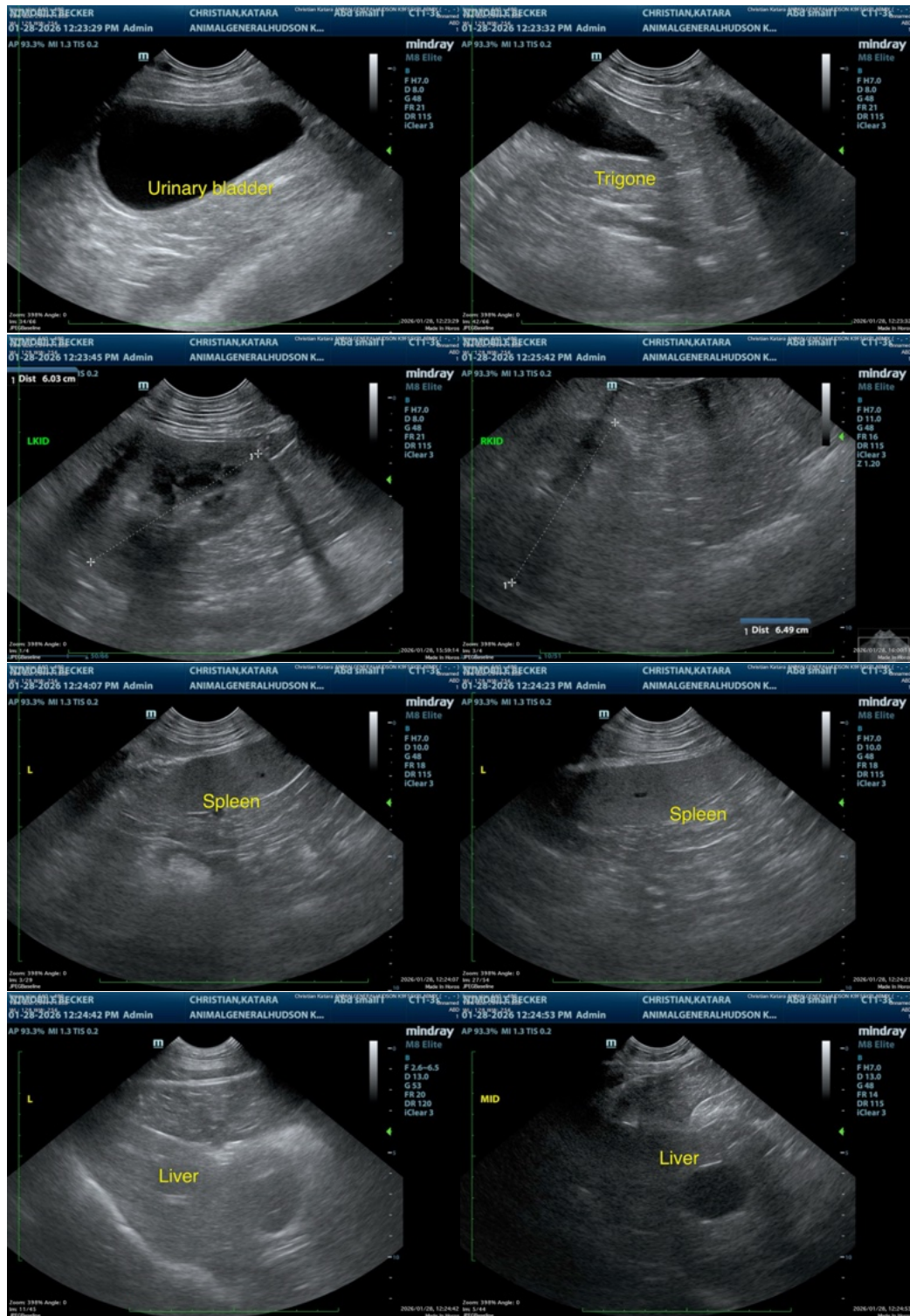
Dr. Hodges

**INVOICE**

71014

**DATE**

1/28/26





**PATIENT**

Katara Christian

**SPECIES**

Canine

**BREED**

Lab Mix

**SEX**

Spayed Female

**AGE**

5 years

**WEIGHT**

69.6 lbs

**INTERPRETED BY**

Remo Lobetti, BVSc,  
 MMedVet (Med),  
 PhD, Dipl. ECVIM

**IMAGING PERFORMED BY**

Kerri Becker

**HOSPITAL NAME**

Animal General  
 Hudson

**REFERRING VET**

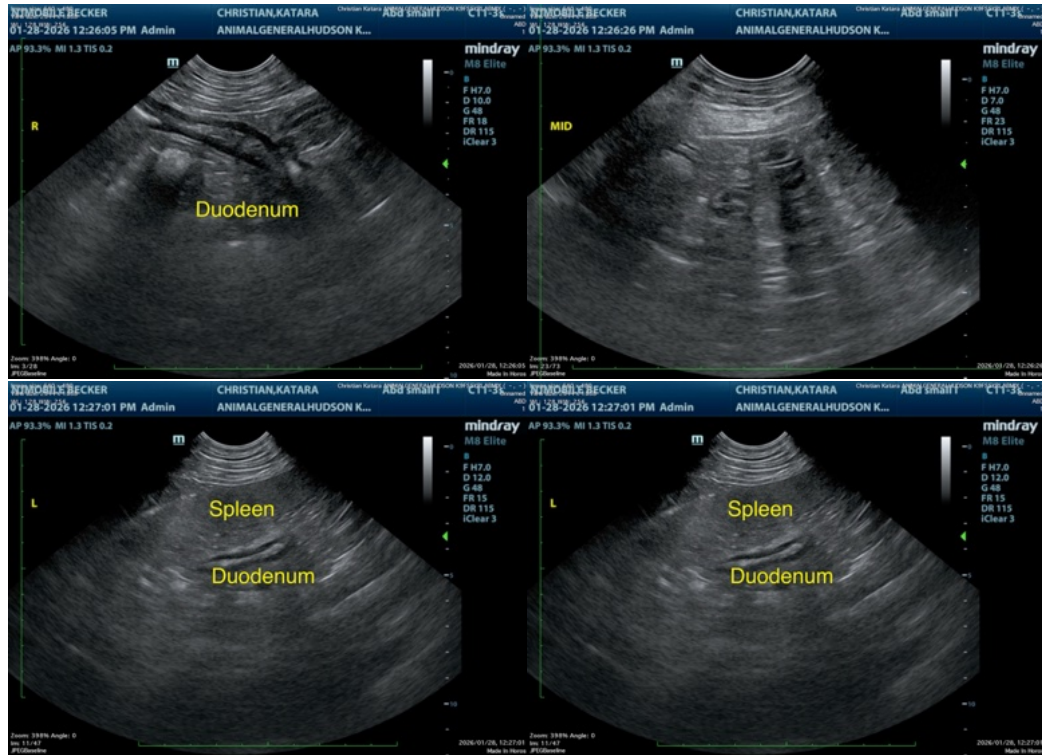
Dr. Hodges

**INVOICE**

71014

**DATE**

1/28/26



The information and recommendations provided are based on the images presented by the referring veterinarian/sonographer. No evaluation can be communicated regarding pathology that was not visible in the image/video clips provided.

Thank you for this referral. If the clinical or image interpretation does not parallel your findings or if I can be of any further assistance please contact me.

Remo Lobetti, BVSc, MMedVet (Med), PhD, Dipl. ECVIM (Internal Medicine)

[info@sonopath.com](mailto:info@sonopath.com)