



PATIENT

Elsie Wong

SPECIES

Canine

BREED

Australian Shepherd
Mix

SEX

Spayed female

AGE

7 years

WEIGHT

79 lbs

INTERPRETED BY

Remo Lobetti, BVSc,
MMedVet (Med),
PhD, Dipl. ECVIM

IMAGING PERFORMED BY

Rebecca Hamilton

HOSPITAL NAME

Oakland AH

REFERRING VET

Dr. Pellicano

INVOICE

71017

DATE

1/28/26

PRESENTING CLINICAL SIGNS

- Inappetence/ vomiting/ diarrhea - started 1/19, has been improving.
- Abd rads WNL, treat supportively
- Meds: Provable Probiotic
- Triglyceride slight ^ - 277, Urine WNL USG 1038

ULTRASONOGRAPHIC EXAMINATION OF THE ABDOMEN

Urinary System

The urinary bladder is full with a normal thickness and smooth appearance of the wall. Normal anechoic urine with no sediment or uroliths evident.

Normal appearance of the trigone area, proximal urethra, and iliac blood vessels.

Normal appearance and size of the iliac lymph nodes. Ureters not visualized, which can be considered a normal finding.

Normal renal size (left measured 5.6 cm, right measured 6.2 cm), architecture, echogenic appearance, cortico-medullary differentiation, which maintains a 1:3 cortex to medulla ratio, pelvis, and capsule. No infarcts, mineralization or renoliths evident. Normal color flow pattern is evident in both kidneys.

Adrenal Glands

Normal shape, echogenic appearance, size, position, and appearance of the visible peri-adrenal vasculature. Left adrenal gland measured 2.2 cm in length x 0.61 cm and 0.34 cm in width. The right adrenal gland measured 2.62 cm in length x 0.54 cm and 0.76 cm in width.

Spleen

Normal size and echogenic appearance. Smooth homogenous parenchyma and regular curvilinear capsule. Normal volume of the splenic vasculature without any overt congestion or thrombosis evident. No inflammatory, neoplastic, infarction, or infiltrative changes evident. The spleen measured 2.0 cm in width.

Liver

Normal size, echogenic appearance, portal markings, and regular curvilinear capsule. No nodules or masses evident. Normal appearance of the hepatic and portal vasculature.

Gallbladder

The gallbladder is full containing normal anechoic bile. Normal thickness and echogenic appearance of the wall. Normal size and appearance of the cystic and common bile duct.



PATIENT

Gastrointestinal

Elsee Wong

Normal appearance of the stomach, duodenum, small intestine, ileo-cecal junction, and colon with no loss of layering, 1:3 muscularis to mucosa ratio, normal wall thickness and peristaltic activity, and no distension of the lumen.

SPECIES

Canine

BREED

Pancreas

Australian Shepherd
 Mix

The visible sections of the pancreas are of normal size and echogenic appearance with a regular capsule. Normal echogenic appearance of the mesentery and fat surrounding the pancreas.

SEX

Spayed female

Free Abdomen

AGE

7 years

Normal mesenteric lymph nodes.

No ascites evident.

WEIGHT

79 lbs

ULTRASONOGRAPHIC FINDINGS

- Normal ultrasound examination of the abdomen.

INTERPRETED BY

INTERPRETATION OF THE FINDINGS & FURTHER RECOMMENDATIONS

Remo Lobetti, BVSc,
 MMedVet (Med),
 PhD, Dipl. ECVIM

The most likely etiology for the presenting clinical signs would be resolving, non-specific gastroenteritis.

Management would be to continue with the current therapy.

IMAGING PERFORMED BY

Rebecca Hamilton

HOSPITAL NAME

Oakland AH

REFERRING VET

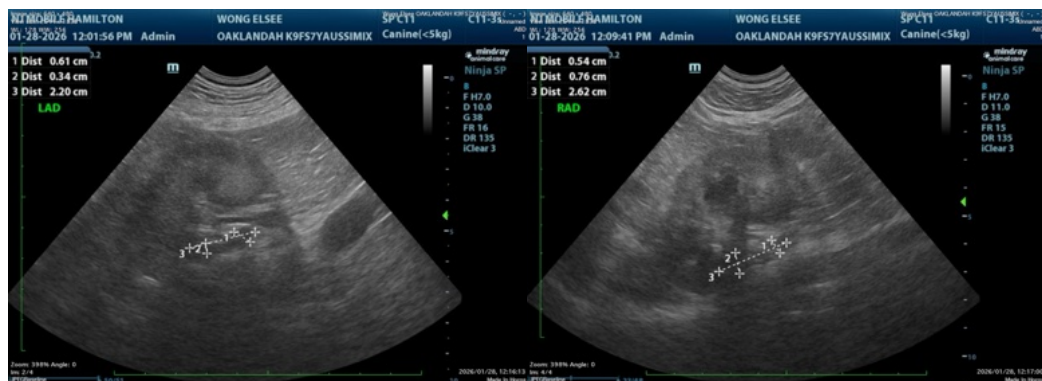
Dr. Pellicano

INVOICE

71017

DATE

1/28/26





PATIENT

Elsee Wong

SPECIES

Canine

BREED

Australian Shepherd
 Mix

SEX

Spayed female

AGE

7 years

WEIGHT

79 lbs

INTERPRETED BY

Remo Lobetti, BVSc,
 MMedVet (Med),
 PhD, Dipl. ECVIM

IMAGING PERFORMED BY

Rebecca Hamilton

HOSPITAL NAME

Oakland AH

REFERRING VET

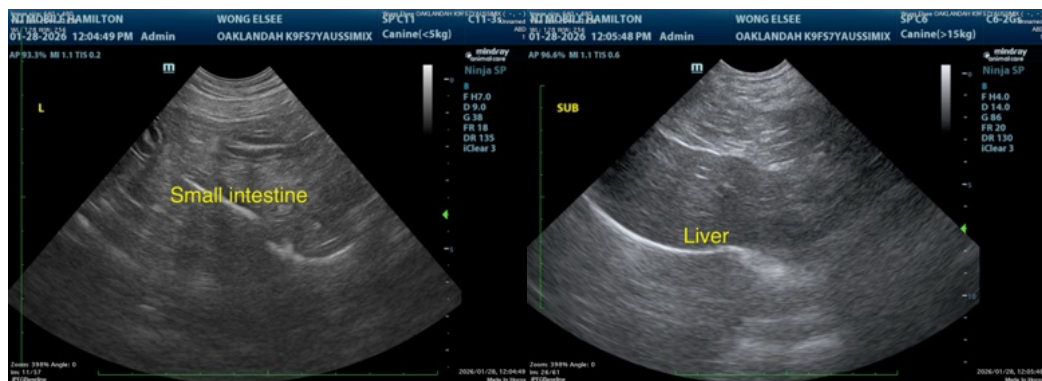
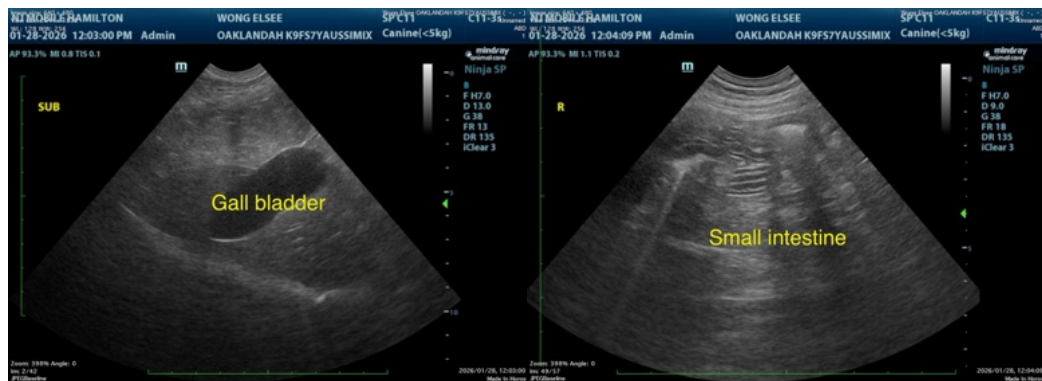
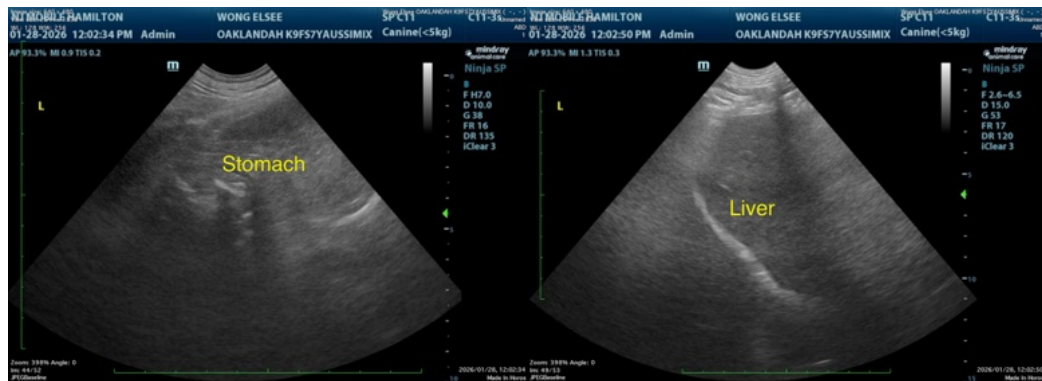
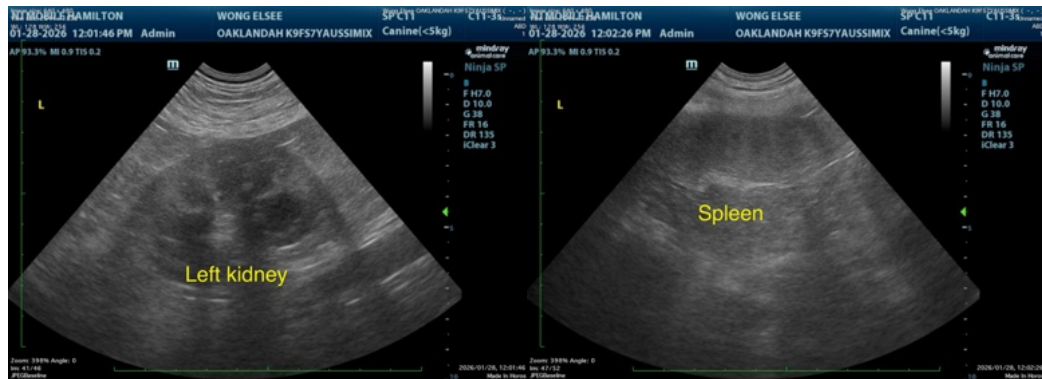
Dr. Pellicano

INVOICE

71017

DATE

1/28/26





PATIENT

Elsee Wong

The information and recommendations provided are based on the images presented by the referring veterinarian/sonographer. No evaluation can be communicated regarding pathology that was not visible in the image/video clips provided.

SPECIES

Canine

Thank you for this referral. If the clinical or image interpretation does not parallel your findings or if I can be of any further assistance please contact me.

Remo Lobetti, BVSc, MMedVet (Med), PhD, Dipl. ECVIM (Internal Medicine)

BREED

Australian Shepherd
Mix

info@sonopath.com

SEX

Spayed female

AGE

7 years

WEIGHT

79 lbs

INTERPRETED BY

Remo Lobetti, BVSc,
MMedVet (Med),
PhD, Dipl. ECVIM

IMAGING PERFORMED BY

Rebecca Hamilton

HOSPITAL NAME

Oakland AH

REFERRING VET

Dr. Pellicano

INVOICE

71017

DATE

1/28/26