



**PATIENT**

Bombo Kim

**SPECIES**

Canine

**BREED**

Shih Tzu

**SEX**

Female

**AGE**

10 years

**WEIGHT**

9 lbs

**INTERPRETED BY**

Remo Lobetti, BVSc,  
 MMedVet (Med),  
 PhD, Dipl. ECVIM

**IMAGING PERFORMED BY**

Kerri Becker

**HOSPITAL NAME**

Animal Paradise  
 Hospital

**REFERRING VET**

Dr. Elshafie

**INVOICE**

71020

**DATE**

1/28/26

**PRESENTING CLINICAL SIGNS**

- Rad report stated normal thorax, colitis, and historical mammary chain masses- recommend biopsy of sq masses, fasted AUS with emphasis on the lymph node chain and supportive care for the colitis.

**ULTRASONOGRAPHIC EXAMINATION OF THE ABDOMEN**

**Urinary System**

The urinary bladder is small with a normal thickness and smooth appearance of the wall. Normal anechoic urine with no sediment or uroliths evident.

Normal appearance of the trigone area, proximal urethra, and iliac blood vessels.

Normal appearance and size of the iliac lymph nodes. Ureters not visualized, which can be considered a normal finding.

Normal renal size (left measured 3.4 cm, right measured 3.9 cm), architecture, echogenic appearance, cortico-medullary differentiation, which maintains a 1:3 cortex to medulla ratio, pelvis, and capsule. No infarcts, mineralization or renoliths evident.

**Adrenal Glands**

Normal shape, echogenic appearance, size, position, and appearance of the visible peri-adrenal vasculature. Left adrenal gland measured 1.46 cm in length x 0.35 cm and 0.36 cm in width. The right adrenal gland measured 1.49 cm in length x 0.51 cm in width.

**Spleen**

Normal size and echogenic appearance. Smooth homogenous parenchyma and regular curvilinear capsule. Normal volume of the splenic vasculature without any overt congestion or thrombosis evident. No inflammatory, neoplastic, infarction, or infiltrative changes evident. The spleen measured 0.8 cm in width.

**Liver**

Normal size, echogenic appearance, portal markings, and regular curvilinear capsule. No nodules or masses evident. Normal appearance of the hepatic and portal vasculature.

**Gallbladder**

The gallbladder is small containing normal anechoic bile. Normal thickness and echogenic appearance of the wall. Normal size and appearance of the cystic and common bile duct.



**PATIENT**

Bombo Kim

**SPECIES**

Canine

**BREED**

Shih Tzu

**SEX**

Female

**AGE**

10 years

**WEIGHT**

9 lbs

**INTERPRETED BY**

Remo Lobetti, BVSc,  
 MMedVet (Med),  
 PhD, Dipl. ECVIM

**IMAGING PERFORMED BY**

Kerri Becker

**HOSPITAL NAME**

Animal Paradise  
 Hospital

**REFERRING VET**

Dr. Elshafie

**INVOICE**

71020

**DATE**

1/28/26

**Gastrointestinal**

Normal appearance of the stomach, duodenum, small intestine, ileo-cecal junction, and colon with no loss of layering, 1:3 muscularis to mucosa ratio, normal wall thickness and peristaltic activity, and no distension of the lumen.

**Pancreas**

The visible sections of the pancreas are of normal size and echogenic appearance with a regular capsule. Normal echogenic appearance of the mesentery and fat surrounding the pancreas.

**Free Abdomen**

Normal mesenteric lymph nodes.

No ascites evident.

Few, non-vascularized, hypoechoic nodules in the mammary chain measuring up to 0.9 x 1.8 cm in size.

**ULTRASONOGRAPHIC FINDINGS**

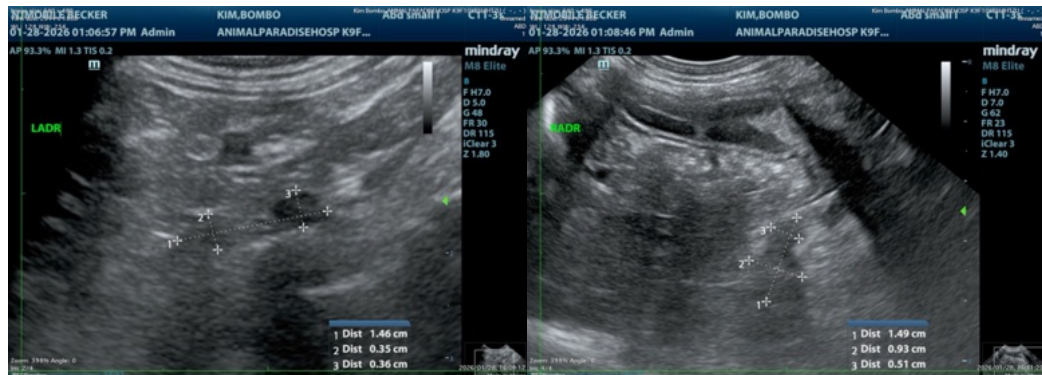
- Normal ultrasound examination of the abdomen.
- Mammary gland nodules.

**INTERPRETATION OF THE FINDINGS & FURTHER RECOMMENDATIONS**

The most likely etiology for the mammary gland nodule would be neoplasia (benign adenomas or carcinomas).

Further assessment would be FNA cytology of the mammary nodules.

Specific therapy would be a mastectomy.





**PATIENT**

Bombo Kim

**SPECIES**

Canine

**BREED**

Shih Tzu

**SEX**

Female

**AGE**

10 years

**WEIGHT**

9 lbs

**INTERPRETED BY**

Remo Lobetti, BVSc,  
 MMedVet (Med),  
 PhD, Dipl. ECVIM

**IMAGING PERFORMED BY**

Kerri Becker

**HOSPITAL NAME**

Animal Paradise  
 Hospital

**REFERRING VET**

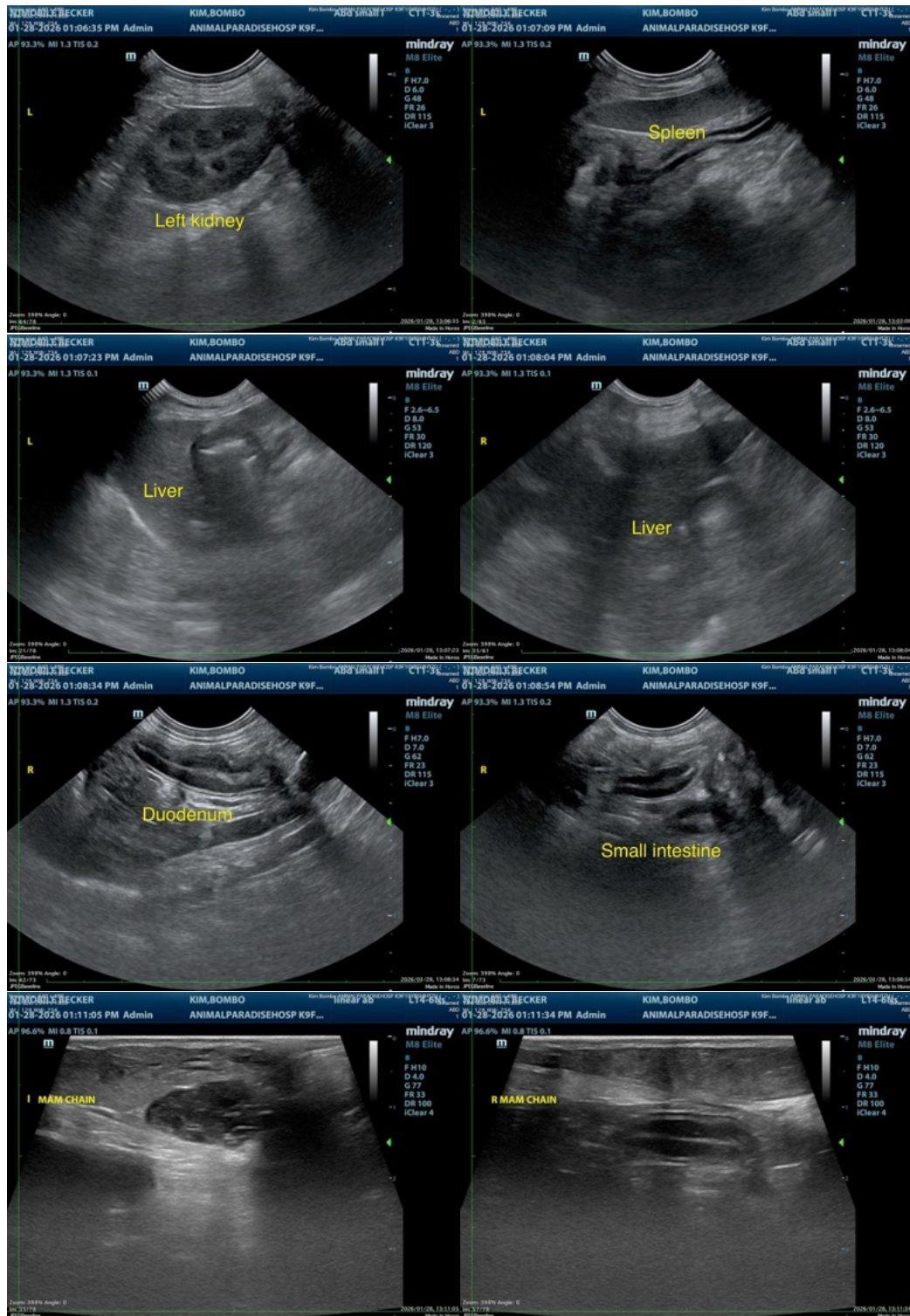
Dr. Elshafie

**INVOICE**

71020

**DATE**

1/28/26





**PATIENT**

Bombo Kim

**SPECIES**

Canine

**BREED**

Shih Tzu

**SEX**

Female

**AGE**

10 years

**WEIGHT**

9 lbs

**INTERPRETED BY**

Remo Lobetti, BVSc,  
MMedVet (Med),  
PhD, Dipl. ECVIM

**IMAGING PERFORMED BY**

Kerri Becker

**HOSPITAL NAME**

Animal Paradise  
Hospital

**REFERRING VET**

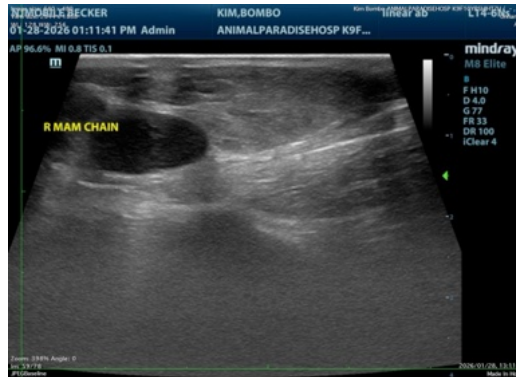
Dr. Elshafie

**INVOICE**

71020

**DATE**

1/28/26



The information and recommendations provided are based on the images presented by the referring veterinarian/sonographer. No evaluation can be communicated regarding pathology that was not visible in the image/video clips provided.

Thank you for this referral. If the clinical or image interpretation does not parallel your findings or if I can be of any further assistance please contact me.

Remo Lobetti, BVSc, MMedVet (Med), PhD, Dipl. ECVIM (Internal Medicine)

[info@sonopath.com](mailto:info@sonopath.com)