



PATIENT

Linus Smith

SPECIES

Canine

BREED

Standard Poodle

SEX

Neutered male

AGE

7 years

WEIGHT

62 lbs

INTERPRETED BY

Remo Lobetti, BVSc,
MMedVet (Med),
PhD, Dipl. ECVIM

IMAGING PERFORMED BY

Shari Reffi, CVT

HOSPITAL NAME

Shohola VH

REFERRING VET

Dr. DeMeo

INVOICE

70311

DATE

1/20/26

PRESENTING CLINICAL SIGNS

- Mass check
- Lethargy
- 4 x 5cm cranio dorsal mass in thorax
- Current meds: Torb sedation; Pred 15mg SID (owner weaned off 1 week ago), no other current meds.

ULTRASONOGRAPHIC EXAMINATION OF THE ABDOMEN

Urinary System

The urinary bladder is small with a normal thickness and smooth appearance of the wall. Normal anechoic urine with no sediment or uroliths evident.

Normal appearance of the trigone area, proximal urethra, and iliac blood vessels.

Normal appearance and size of the iliac lymph nodes. Ureters not visualized, which can be considered a normal finding.

Normal renal size (left measured 6.3 cm, right measured 5.7 cm), architecture, echogenic appearance, cortico-medullary differentiation, which maintains a 1:3 cortex to medulla ratio, pelvis, and capsule. No infarcts, mineralization or renoliths evident. Normal color flow pattern is evident in both kidneys.

The prostate is small and hypoechogenic measuring 0.8 cm in width.

Adrenal Glands

Normal shape, echogenic appearance, size, position, and appearance of the visible peri-adrenal vasculature. Left adrenal gland measured 0.55 cm and 0.43 cm in width. The right adrenal gland measured 0.46 cm in width.

Spleen

Normal size and echogenic appearance. Smooth homogenous parenchyma and regular curvilinear capsule. Normal volume of the splenic vasculature without any overt congestion or thrombosis evident. Small, focal, hypoechogenic parenchymal nodule in the body of the spleen measuring 1.1 x 1.4 cm in size. The spleen measures 1.9 cm in width.

Liver

Normal size, echogenic appearance, portal markings, and regular curvilinear capsule. No nodules or masses evident. Normal appearance of the hepatic and portal vasculature.



PATIENT

Linus Smith

SPECIES

Canine

BREED

Standard Poodle

SEX

Neutered male

AGE

7 years

WEIGHT

62 lbs

INTERPRETED BY

Remo Lobetti, BVSc,
MMedVet (Med),
PhD, Dipl. ECVIM

IMAGING PERFORMED BY

Shari Reffi, CVT

HOSPITAL NAME

Shohola VH

REFERRING VET

Dr. DeMeo

INVOICE

70311

DATE

1/20/26

Gallbladder

The gallbladder is full containing normal anechoic bile. Normal thickness and echogenic appearance of the wall. Normal size and appearance of the cystic and common bile duct.

Gastrointestinal

Normal appearance of the stomach, duodenum, small intestine, ileo-cecal junction, and colon with no loss of layering, 1:3 muscularis to mucosa ratio, normal wall thickness and peristaltic activity, and no distension of the lumen. Fecal material was present in the colon.

Pancreas

The visible sections of the pancreas are of normal size and echogenic appearance with a regular capsule. Normal echogenic appearance of the mesentery and fat surrounding the pancreas.

Free Abdomen

Normal mesenteric lymph nodes.

No ascites evident.

Thorax

Normal appearance of the heart. No pericardial or pleural effusion evident.

ULTRASONOGRAPHIC FINDINGS

- Splenic nodule.

INTERPRETATION OF THE FINDINGS & FURTHER RECOMMENDATIONS

The most likely etiology for the splenic nodule would be an incidental reactive hyperplasia/extramedullary hemopoiesis with hematoma and granuloma a less likely differential diagnosis and neoplasia an unlikely differential diagnosis.

Further assessment that can be considered would be FNA cytology of the splenic nodule especially as there is a thoracic mass.

Monitoring of the splenic nodule would be recommended and if there is any progressive enlargement or bulging of the overlying capsule noted, then a splenectomy should be considered.



PATIENT

Linus Smith

SPECIES

Canine

BREED

Standard Poodle

SEX

Neutered male

AGE

7 years

WEIGHT

62 lbs

INTERPRETED BY

Remo Lobetti, BVSc,
MMedVet (Med),
PhD, Dipl. ECVIM

IMAGING PERFORMED BY

Shari Reffi, CVT

HOSPITAL NAME

Shohola VH

REFERRING VET

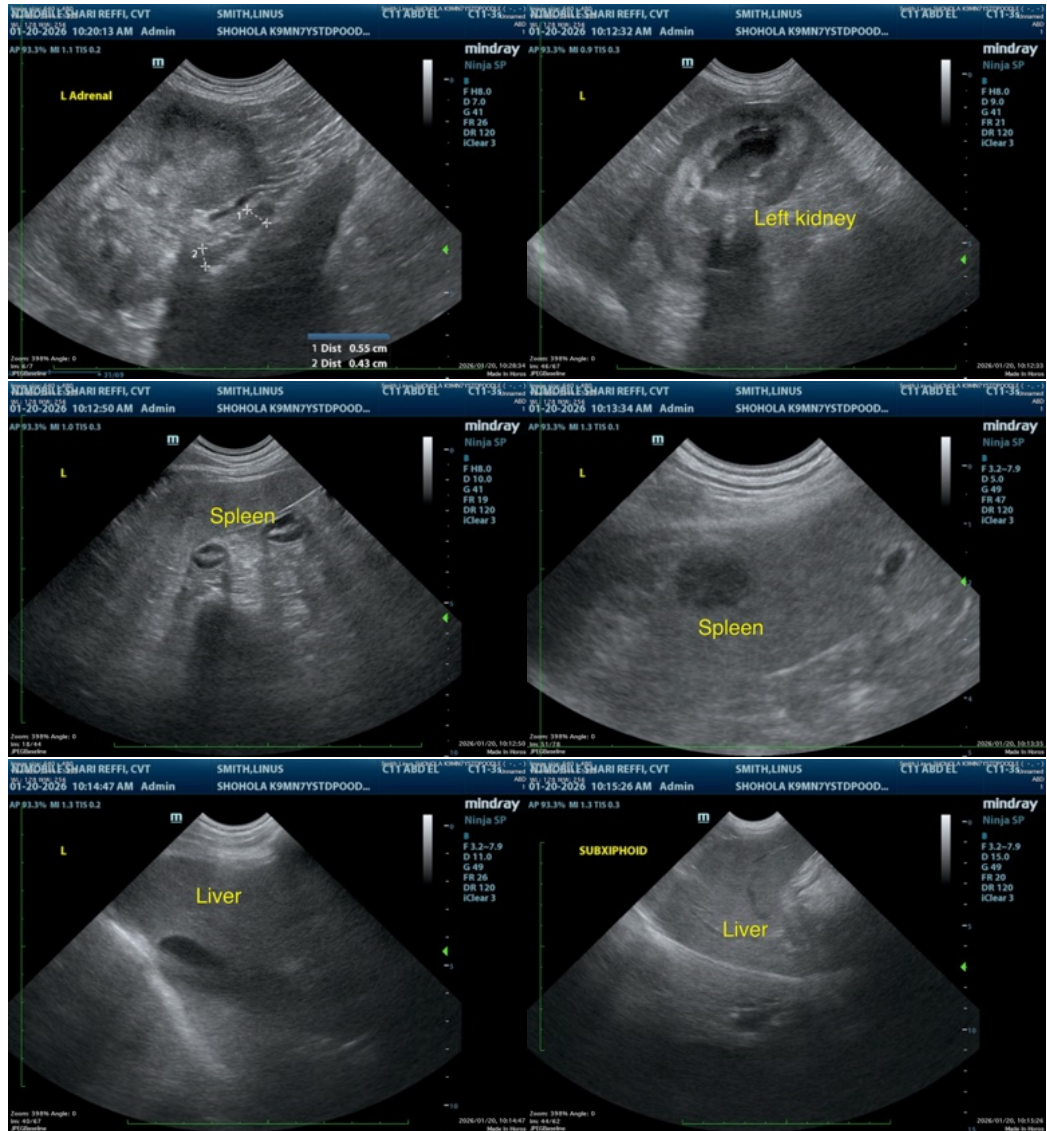
Dr. DeMeo

INVOICE

70311

DATE

1/20/26





PATIENT

Linus Smith

SPECIES

Canine

BREED

Standard Poodle

SEX

Neutered male

AGE

7 years

WEIGHT

62 lbs

INTERPRETED BY

Remo Lobetti, BVSc,
MMedVet (Med),
PhD, Dipl. ECVIM

IMAGING PERFORMED BY

Shari Reffi, CVT

HOSPITAL NAME

Shohola VH

REFERRING VET

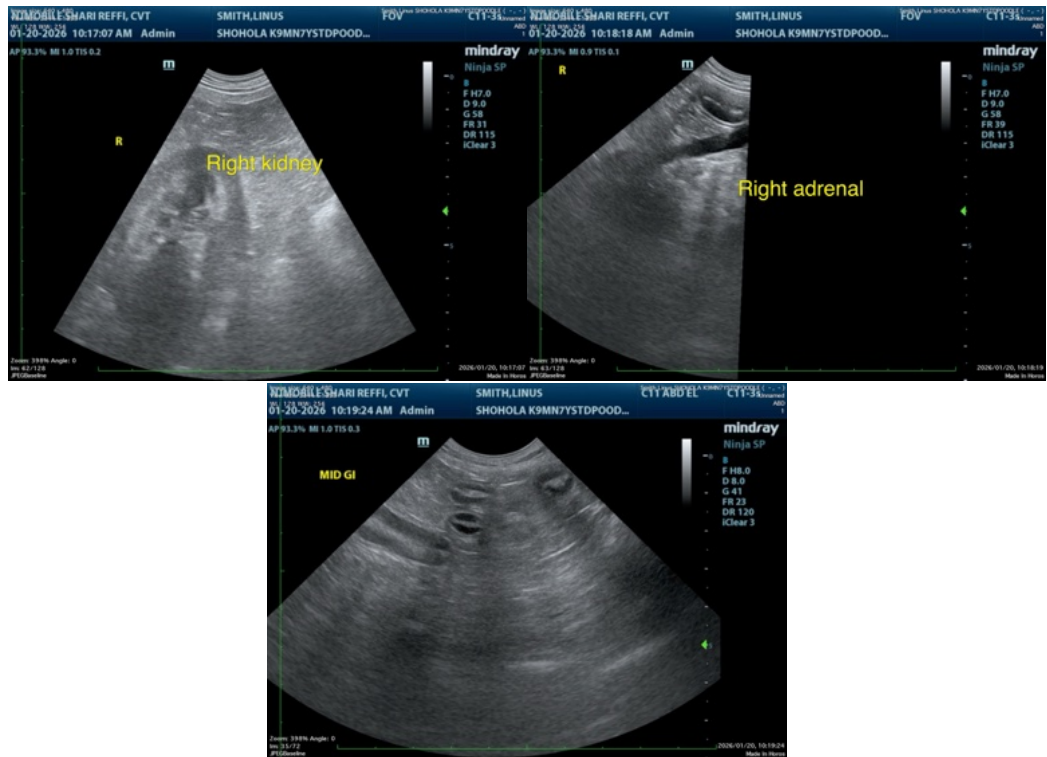
Dr. DeMeo

INVOICE

70311

DATE

1/20/26



The information and recommendations provided are based on the images presented by the referring veterinarian/sonographer. No evaluation can be communicated regarding pathology that was not visible in the image/video clips provided.

Thank you for this referral. If the clinical or image interpretation does not parallel your findings or if I can be of any further assistance please contact me.

Remo Lobetti, BVSc, MMedVet (Med), PhD, Dipl. ECVIM (Internal Medicine)

info@sonopath.com