



PATIENT

Rocky Balboa

SPECIES

Canine

BREED

Havanese

SEX

Neutered male

AGE

12 ½ years

WEIGHT

-

INTERPRETED BY

Remo Lobetti, BVSc,
MMedVet (Med),
PhD, Dipl. ECVIM

**IMAGING
PERFORMED BY**

Kerri Becker

HOSPITAL NAME

Englewood Cliffs VH

REFERRING VET

Dr. Park

INVOICE

70202

DATE

1/16/26

PRESENTING CLINICAL SIGNS

History: Chronic V+D hx of chronic ge managed with LF diet. Woke up this morning with Vand D went to VEG- rads unremarkable, cerenia, visbiome given. Cerenia given at ER this AM

ULTRASONOGRAPHIC EXAMINATION OF THE ABDOMEN

Urinary System

The urinary bladder is small with a normal thickness and smooth appearance of the wall. Normal anechoic urine with no sediment or uroliths evident.

Normal appearance of the trigone area, proximal urethra, and iliac blood vessels.

Normal appearance and size of the iliac lymph nodes. Ureters not visualized, which can be considered a normal finding.

Normal renal size (left measured 3.8 cm, right measured 4.3 cm), architecture, echogenic appearance, cortico-medullary differentiation, which maintains a 1:3 cortex to medulla ratio, pelvis, and capsule. No infarcts, mineralization or renoliths evident. Normal color flow pattern is evident in both kidneys.

The prostate was small and hypoechogenic.

Adrenal Glands

Normal shape, echogenic appearance, size, position, and appearance of the visible peri-adrenal vasculature. Left adrenal gland measured 1.32 cm in length x 0.47 cm and 0.42 cm in width. The right adrenal gland measured 1.78 cm in length x 0.51 cm and 0.41 cm in width.

Spleen

Normal size and echogenic appearance. Smooth homogenous parenchyma and regular curvilinear capsule. Normal volume of the splenic vasculature without any overt congestion or thrombosis evident. No inflammatory, neoplastic, infarction, or infiltrative changes evident. The spleen measured 0.9 cm in width.

Liver

Normal size, echogenic appearance, portal markings, and regular curvilinear capsule. No nodules or masses evident. Normal appearance of the hepatic and portal vasculature.

Gallbladder

The gallbladder is full containing normal anechoic bile. Normal thickness and echogenic appearance of the wall. Normal size and appearance of the cystic and common bile duct.



PATIENT

Rocky Balboa

SPECIES

Canine

BREED

Havanese

SEX

Neutered male

AGE

12 ½ years

WEIGHT

-

INTERPRETED BY

Remo Lobetti, BVSc,
MMedVet (Med),
PhD, Dipl. ECVIM

IMAGING PERFORMED BY

Kerri Becker

HOSPITAL NAME

Englewood Cliffs VH

REFERRING VET

Dr. Park

INVOICE

70202

DATE

1/16/26

Gastrointestinal

Normal appearance of the stomach, duodenum, small intestine, ileo-cecal junction, and colon with no loss of layering, 1:3 muscularis to mucosa ratio, normal wall thickness and peristaltic activity, and no distension of the lumen.

Pancreas

The visible sections of the pancreas are of normal size and echogenic appearance with a regular capsule. Normal echogenic appearance of the mesentery and fat surrounding the pancreas.

Free Abdomen

Normal mesenteric lymph nodes.

No ascites evident.

ULTRASONOGRAPHIC FINDINGS

- Normal ultrasound examination of the abdomen.

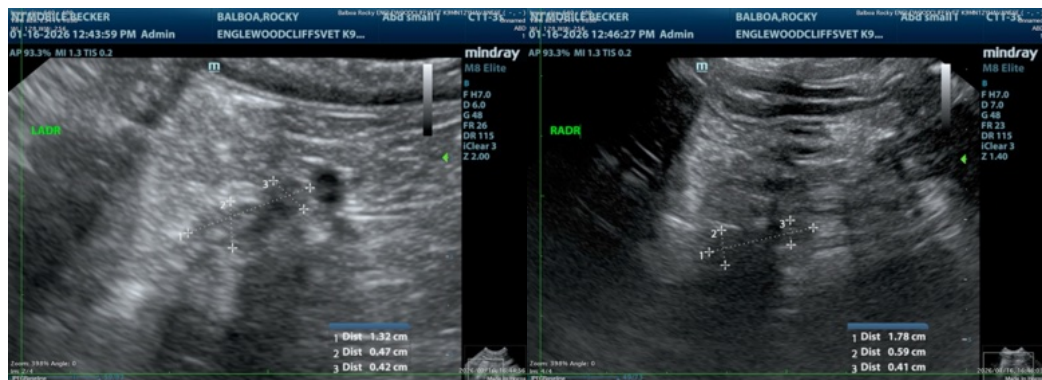
INTERPRETATION OF THE FINDINGS & FURTHER RECOMMENDATIONS

On this ultrasound there is no obvious etiology for the acute vomiting and diarrhea.

The most likely etiology would be non-specific gastroenteritis such as dietary indiscretion, toxins, viral and possibly parasitic.

Initial further assessment would be fecal analysis.

Management would be to continue with the symptomatic therapy.





PATIENT

Rocky Balboa

SPECIES

Canine

BREED

Havanese

SEX

Neutered male

AGE

12 ½ years

WEIGHT

-

INTERPRETED BY

Remo Lobetti, BVSc,
 MMedVet (Med),
 PhD, Dipl. ECVIM

IMAGING PERFORMED BY

Kerri Becker

HOSPITAL NAME

Englewood Cliffs VH

REFERRING VET

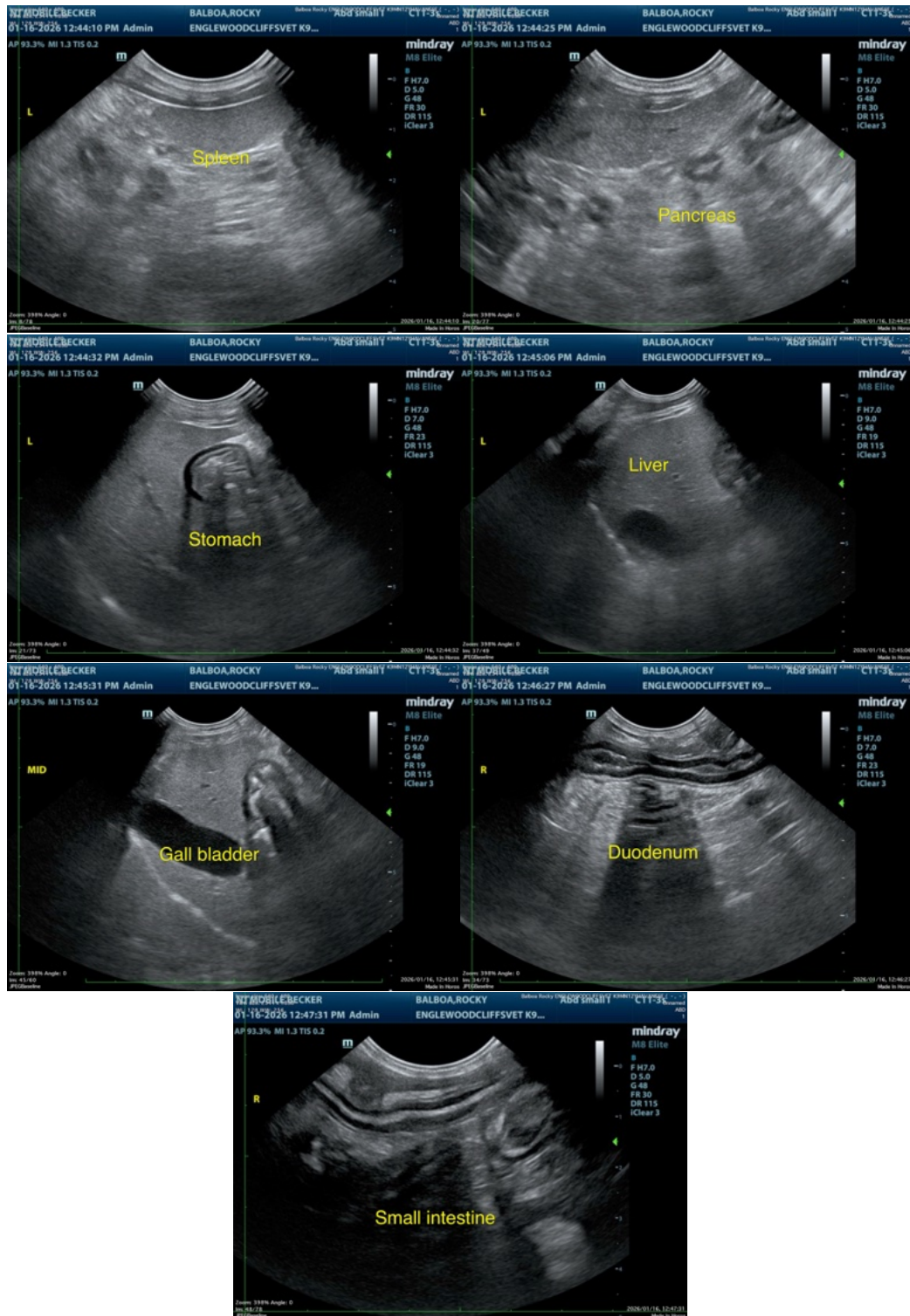
Dr. Park

INVOICE

70202

DATE

1/16/26



The information and recommendations provided are based on the images presented by the referring veterinarian/sonographer. No evaluation can be communicated regarding pathology



PATIENT

Rocky Balboa

SPECIES

Canine

BREED

Havanese

SEX

Neutered male

AGE

12 ½ years

WEIGHT

-

INTERPRETED BY

Remo Lobetti, BVSc,
MMedVet (Med),
PhD, Dipl. ECVIM

**IMAGING
PERFORMED BY**

Kerri Becker

HOSPITAL NAME

Englewood Cliffs VH

REFERRING VET

Dr. Park

INVOICE

70202

DATE

1/16/26

that was not visible in the image/video clips provided.

Thank you for this referral. If the clinical or image interpretation does not parallel your findings or if I can be of any further assistance please contact me.

Remo Lobetti, BVSc, MMedVet (Med), PhD, Dipl. ECVIM (Internal Medicine)

info@sonopath.com