



**PATIENT**

Fluffy Mayer

**SPECIES**

Canine

**BREED**

Mix

**SEX**

Neutered male

**AGE**

15 years

**WEIGHT**

11 lbs

**INTERPRETED BY**

Remo Lobetti, BVSc,  
MMedVet (Med),  
PhD, Dipl. ECVIM

**IMAGING PERFORMED BY**

Kerri Becker

**HOSPITAL NAME**

Englewood Cliffs VH

**REFERRING VET**

Dr. Park

**INVOICE**

70203

**DATE**

1/16/26

**PRESENTING CLINICAL SIGNS**

History: HX inter. hematochezia and poss. melena for 3 wks.  
Abnormal PE/Chem/CBC/UA Results: non regen anemia.

**ULTRASONOGRAPHIC EXAMINATION OF THE ABDOMEN**

**Urinary System**

The urinary bladder is small with a normal thickness and smooth appearance of the wall. Normal anechoic urine with no sediment or uroliths evident.

Normal appearance of the trigone area, proximal urethra, and iliac blood vessels.

Normal appearance and size of the iliac lymph nodes. Ureters not visualized, which can be considered a normal finding.

Normal renal size (left measured 3.4 cm, right measured 3.2 cm), increased echogenic appearance, some loss of cortico-medullary differentiation and normal pelvis and capsule. No infarcts, mineralization or renoliths evident. Normal color flow pattern is evident in both kidneys.

The prostate is enlarged (for a neutered male) measuring 1.4 x 1.4 cm in size with a mottled echogenic appearance and a mildly irregular capsule. Parenchymal mineralization is present. Normal appearance of the periprostatic tissue.

**Adrenal Glands**

Normal shape, echogenic appearance, size, position, and appearance of the visible peri-adrenal vasculature. Left adrenal gland measured 1.77 cm in length x 0.52 cm and 0.53 cm in width. The right adrenal gland measured 1.71 cm in length x 0.74 cm and 0.54 cm in width.

**Spleen**

Normal size and echogenic appearance. Smooth homogenous parenchyma and regular curvilinear capsule. Normal volume of the splenic vasculature without any overt congestion or thrombosis evident. No inflammatory, neoplastic, infarction, or infiltrative changes evident. The spleen measured 1.1 cm in width.

**Liver**

Normal size, echogenic appearance, portal markings, and regular curvilinear capsule. No nodules or masses evident. Normal appearance of the hepatic and portal vasculature.



**PATIENT**

Fluffy Mayer

**SPECIES**

Canine

**BREED**

Mix

**SEX**

Neutered male

**AGE**

15 years

**WEIGHT**

11 lbs

**INTERPRETED BY**

Remo Lobetti, BVSc,  
MMedVet (Med),  
PhD, Dipl. ECVIM

**IMAGING  
PERFORMED BY**

Kerri Becker

**HOSPITAL NAME**

Englewood Cliffs VH

**REFERRING VET**

Dr. Park

**INVOICE**

70203

**DATE**

1/16/26

***Gallbladder***

The gallbladder is small containing normal anechoic bile. Normal thickness and echogenic appearance of the wall. Normal size and appearance of the cystic and common bile duct.

***Gastrointestinal***

Normal appearance of the stomach, duodenum, small intestine, ileo-cecal junction, and colon with no loss of layering, 1:3 muscularis to mucosa ratio, normal wall thickness and peristaltic activity, and no distension of the lumen.

***Pancreas***

The visible sections of the pancreas are of normal size and echogenic appearance with a regular capsule. Normal echogenic appearance of the mesentery and fat surrounding the pancreas.

***Free Abdomen***

Normal mesenteric lymph nodes.

No ascites evident.

**ULTRASONOGRAPHIC FINDINGS**

- Prostatomegaly.
- Age related renal changes versus early chronic kidney disease.

**INTERPRETATION OF THE FINDINGS & FURTHER RECOMMENDATIONS**

The most likely etiology for the prostatomegaly would be neoplasia with chronic prostatitis a less likely differential diagnosis.

Further assessment would be prostatic wash for cytology and culture.

Further assessment of the non-regenerative anemia that may be required would be bone marrow cytology and/or a biopsy.

Specific therapy would be dependent on an etiological diagnosis.



**PATIENT**

Fluffy Mayer

**SPECIES**

Canine

**BREED**

Mix

**SEX**

Neutered male

**AGE**

15 years

**WEIGHT**

11 lbs

**INTERPRETED BY**

Remo Lobetti, BVSc,  
 MMedVet (Med),  
 PhD, Dipl. ECVIM

**IMAGING PERFORMED BY**

Kerri Becker

**HOSPITAL NAME**

Englewood Cliffs VH

**REFERRING VET**

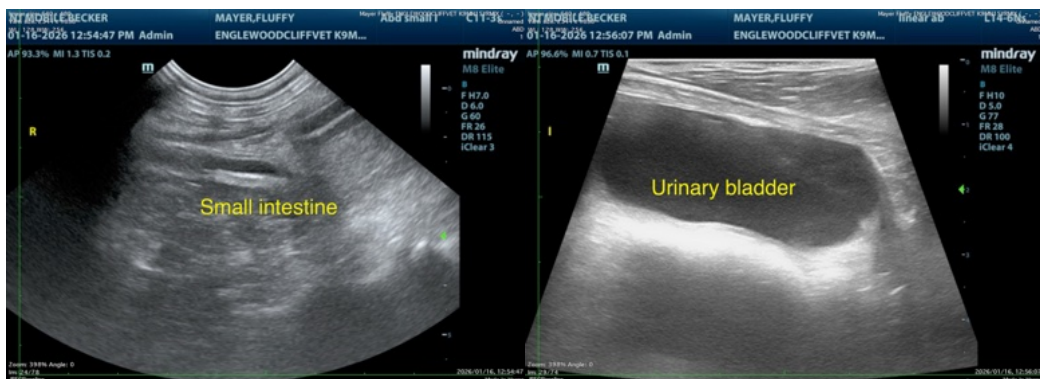
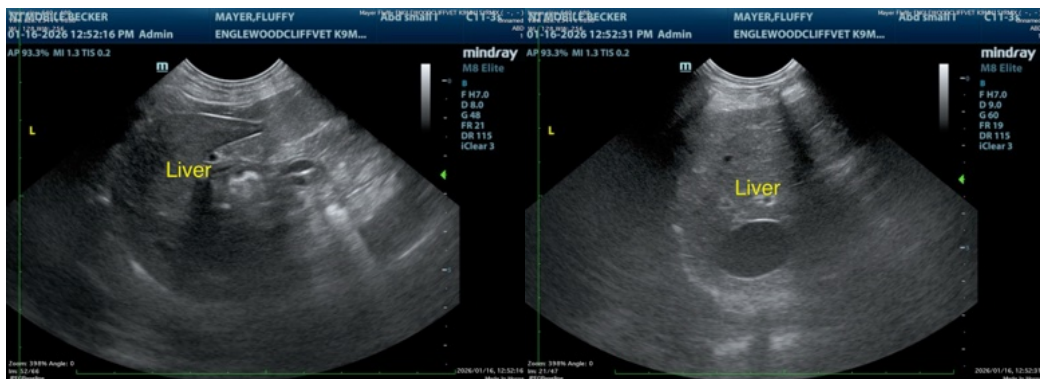
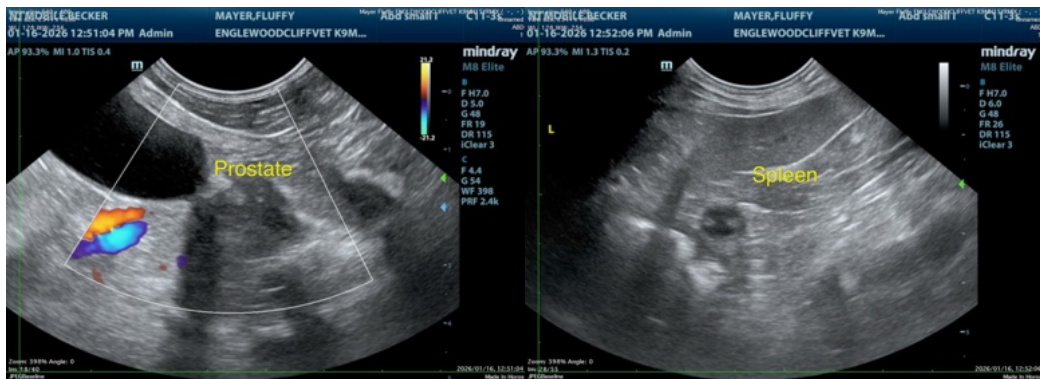
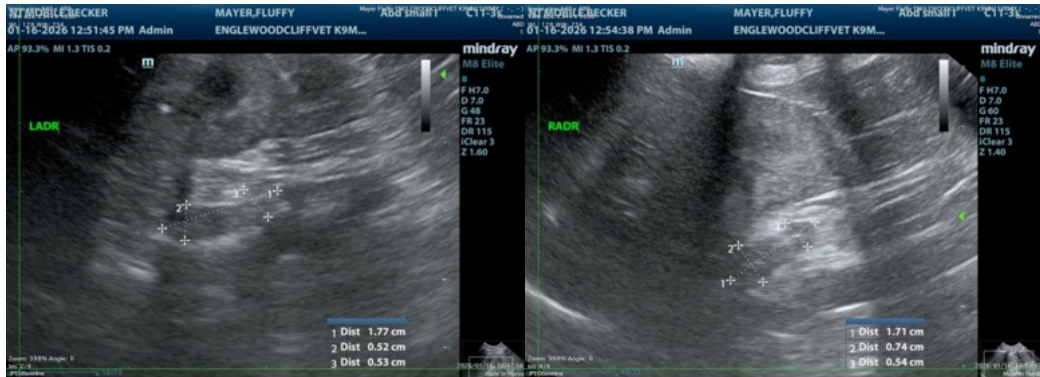
Dr. Park

**INVOICE**

70203

**DATE**

1/16/26





**PATIENT**

Fluffy Mayer

**SPECIES**

Canine

**BREED**

Mix

**SEX**

Neutered male

**AGE**

15 years

**WEIGHT**

11 lbs

**INTERPRETED BY**

Remo Lobetti, BVSc,  
MMedVet (Med),  
PhD, Dipl. ECVIM

**IMAGING  
PERFORMED BY**

Kerri Becker

**HOSPITAL NAME**

Englewood Cliffs VH

**REFERRING VET**

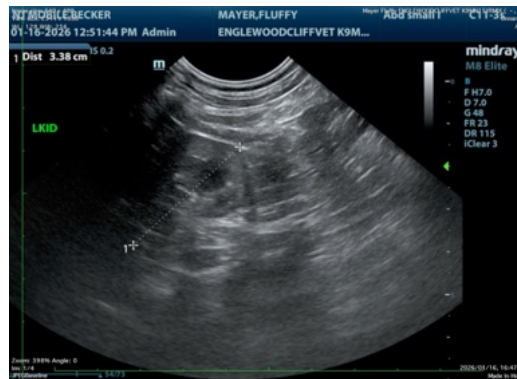Dr. Park

**INVOICE**

70203

**DATE**

1/16/26



The information and recommendations provided are based on the images presented by the referring veterinarian/sonographer. No evaluation can be communicated regarding pathology that was not visible in the image/video clips provided.

Thank you for this referral. If the clinical or image interpretation does not parallel your findings or if I can be of any further assistance please contact me.

Remo Lobetti, BVSc, MMedVet (Med), PhD, Dipl. ECVIM (Internal Medicine)

[info@sonopath.com](mailto:info@sonopath.com)