



## PATIENT

Nala Butler

## SPECIES

Feline

## BREED

Havana Brown

## SEX

Spaed female

## AGE

8 ½ years

## WEIGHT

11.5 lbs

## INTERPRETED BY

Remo Lobetti, BVSc,  
MMedVet (Med),  
PhD, Dipl. ECVIM

## IMAGING PERFORMED BY

Shari Reffi, CVT

## HOSPITAL NAME

Legacy AH

## REFERRING VET

Dr. Pontenzone

## INVOICE

69997

## DATE

1/12/26

## PRESENTING CLINICAL SIGNS

History: Mass affect L side of abdomen. R/O mass vs other  
Abnormal PE/Chem/CBC/UA Results: 1:10- GGT 5; Eos 1.72

## ULTRASONOGRAPHIC EXAMINATION OF THE ABDOMEN

### *Urinary System*

The urinary bladder is full with a normal thickness and smooth appearance of the wall. A scant amount of floating, hyperechogenic sediment is noted.

Normal appearance of the trigone area, proximal urethra, and iliac blood vessels.

Normal appearance and size of the iliac lymph nodes. Ureters not visualized, which can be considered a normal finding.

Normal renal size (left measured 3.8 cm, right measured 3.8 cm), architecture, echogenic appearance, cortico-medullary differentiation, which maintains a 1:3 cortex to medulla ratio, pelvis, and capsule. No infarcts, mineralization or renoliths evident. Both kidneys had a normal color flow pattern.

### *Adrenal Glands*

Normal shape, echogenic appearance, size, position, and appearance of the visible peri-adrenal vasculature. Left adrenal gland measured 0.32 cm in width. The right adrenal gland measured 0.34 cm in width.

### *Spleen*

Normal size and echogenic appearance. Smooth homogenous parenchyma and regular curvilinear capsule. Normal volume of the splenic vasculature without any overt congestion or thrombosis evident. No inflammatory, neoplastic, infarction, or infiltrative changes evident. The spleen measured 0.7 cm in width.

### *Liver*

Normal size, echogenic appearance, portal markings, and regular curvilinear capsule. No nodules or masses evident. Normal appearance of the hepatic and portal vasculature.

### *Gallbladder*

The gallbladder is full containing normal anechoic bile. Normal thickness and echogenic appearance of the wall. Normal size and appearance of the cystic and common bile duct.



**PATIENT**

Nala Butler

**SPECIES**

Feline

**BREED**

Havana Brown

**SEX**

Spaed female

**AGE**

8 ½ years

**WEIGHT**

11.5 lbs

**INTERPRETED BY**

Remo Lobetti, BVSc,  
MMedVet (Med),  
PhD, Dipl. ECVIM

**IMAGING PERFORMED BY**

Shari Reffi, CVT

**HOSPITAL NAME**

Legacy AH

**REFERRING VET**

Dr. Pontenzone

**INVOICE**

69997

**DATE**

1/12/26

**Gastrointestinal**

Normal appearance of the stomach, duodenum, small intestine, ileo-cecal junction, and colon with no loss of layering, 1:3 muscularis to mucosa ratio, normal wall thickness and peristaltic activity, and no distension of the lumen.

**Pancreas**

The visible sections of the pancreas are of normal size and echogenic appearance with a regular capsule. Normal echogenic appearance of the mesentery and fat surrounding the pancreas.

**Free Abdomen**

Normal mesenteric lymph nodes.

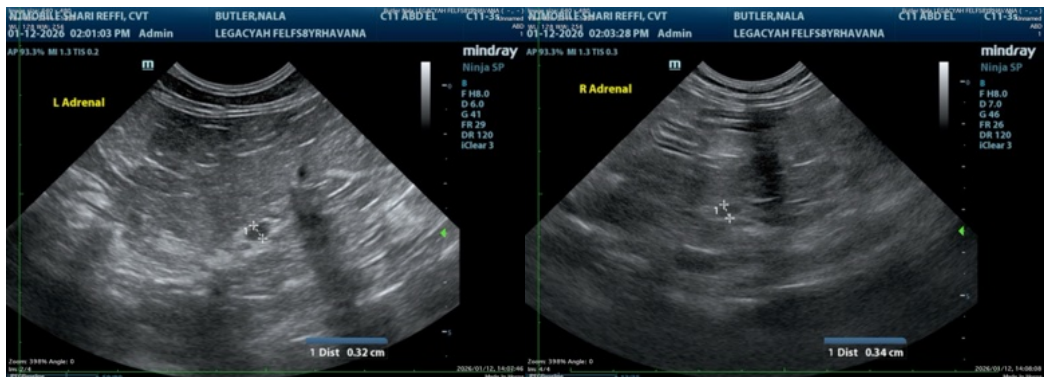
No ascites evident.

**ULTRASONOGRAPHIC FINDINGS**

- Normal ultrasound examination of the abdomen.

**INTERPRETATION OF THE FINDINGS & FURTHER RECOMMENDATIONS**

No specific therapy is recommended at this time.





**PATIENT**

Nala Butler

**SPECIES**

Feline

**BREED**

Havana Brown

**SEX**

Spaed female

**AGE**

8 ½ years

**WEIGHT**

11.5 lbs

**INTERPRETED BY**

Remo Lobetti, BVSc,  
MMedVet (Med),  
PhD, Dipl. ECVIM

**IMAGING PERFORMED BY**

Shari Reffi, CVT

**HOSPITAL NAME**

Legacy AH

**REFERRING VET**

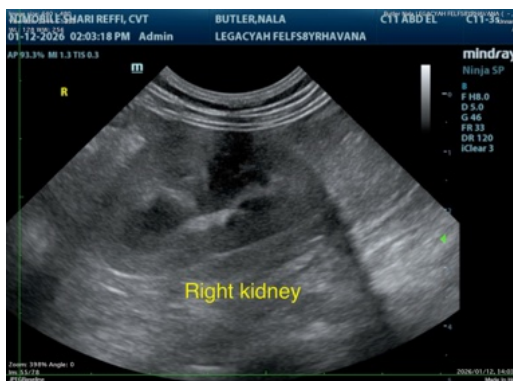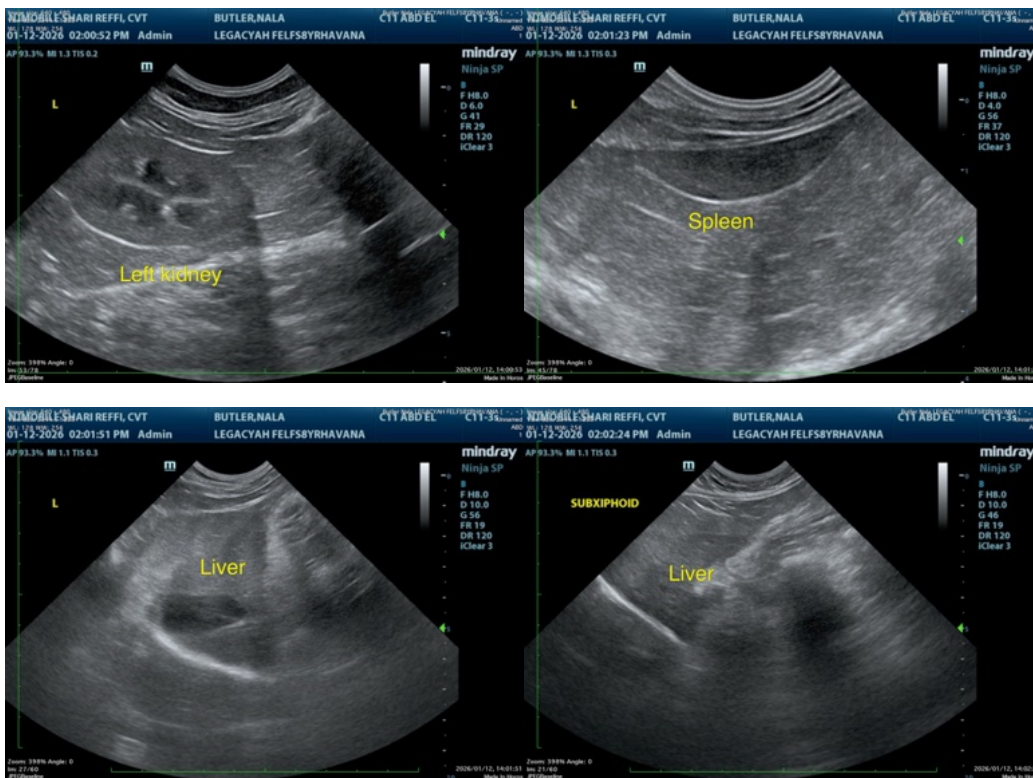
Dr. Pontenzone

**INVOICE**

69997

**DATE**

1/12/26



The information and recommendations provided are based on the images presented by the referring veterinarian/sonographer. No evaluation can be communicated regarding pathology that was not visible in the image/video clips provided.

Thank you for this referral. If the clinical or image interpretation does not parallel your findings or if I can be of any further assistance please contact me.

Remo Lobetti, BVSc, MMedVet (Med), PhD, Dipl. ECVIM (Internal Medicine)

[info@sonopath.com](mailto:info@sonopath.com)



## PATIENT

Nala Butler

## SPECIES

Feline

## BREED

Havana Brown

## SEX

Spaed female

## AGE

8 ½ years

## WEIGHT

11.5 lbs

## INTERPRETED BY

Remo Lobetti, BVSc,  
MMedVet (Med),  
PhD, Dipl. ECVIM

## IMAGING PERFORMED BY

Shari Reffi, CVT

## HOSPITAL NAME

Legacy AH

## REFERRING VET

Dr. Pontenzone

## INVOICE

69997

## DATE

1/12/26