



**PATIENT**

Mika Negron

**SPECIES**

Canine

**BREED**

Pomeranian

**SEX**

Spayed female

**AGE**

7 years

**WEIGHT**

-

**INTERPRETED BY**

Remo Lobetti, BVSc,  
MMedVet (Med),  
PhD, Dipl. ECVIM

**IMAGING PERFORMED BY**

Kerri Becker

**HOSPITAL NAME**

Englewood Cliffs VH

**REFERRING VET**

Dr. Park

**INVOICE**

69989

**DATE**

1/12/26

**PRESENTING CLINICAL SIGNS**

Intermittent vomiting, grade 1 HM. When taking rads questionable cardiomegaly nonspecific.

**ULTRASONOGRAPHIC EXAMINATION OF THE ABDOMEN**

**Urinary System**

The urinary bladder is full with a normal thickness and smooth appearance of the wall. Normal anechoic urine with no sediment or uroliths evident.

Normal appearance of the trigone area, proximal urethra, and iliac blood vessels.

Normal appearance and size of the iliac lymph nodes. Ureters not visualized, which can be considered a normal finding.

Normal renal size (left measured 2.6 cm, right measured 3.0 cm), architecture, echogenic appearance, cortico-medullary differentiation, which maintains a 1:3 cortex to medulla ratio, pelvis, and capsule. No infarcts, mineralization or renoliths evident. Normal color flow pattern is evident in both kidneys.

**Adrenal Glands**

Normal shape, echogenic appearance, size, position, and appearance of the visible peri-adrenal vasculature. Left adrenal gland measured 1.3 cm in length x 0.32 and 0.34 cm in width. The right adrenal gland measured 1.68 cm in length x 0.36 cm in width.

**Spleen**

Normal size and echogenic appearance. Smooth homogenous parenchyma and regular curvilinear capsule. Normal volume of the splenic vasculature without any overt congestion or thrombosis evident. No inflammatory, neoplastic, infarction, or infiltrative changes evident. The spleen measured 1.0 cm in width.

**Liver**

Normal size, echogenic appearance, portal markings, and regular curvilinear capsule. No nodules or masses evident. Normal appearance of the hepatic and portal vasculature.

**Gallbladder**

The gallbladder is full containing normal anechoic bile. Normal thickness and echogenic appearance of the wall. Normal size and appearance of the cystic and common bile duct.



**PATIENT**

Mika Negron

**SPECIES**

Canine

**BREED**

Pomeranian

**SEX**

Spayed female

**AGE**

7 years

**WEIGHT**

-

**INTERPRETED BY**

Remo Lobetti, BVSc,  
MMedVet (Med),  
PhD, Dipl. ECVIM

**IMAGING PERFORMED BY**

Kerri Becker

**HOSPITAL NAME**

Englewood Cliffs VH

**REFERRING VET**

Dr. Park

**INVOICE**

69989

**DATE**

1/12/26

***Gastrointestinal***

Normal appearance of the stomach, duodenum, small intestine, ileo-cecal junction, and colon with no loss of layering, 1:3 muscularis to mucosa ratio, normal wall thickness and peristaltic activity, and no distension of the lumen.

***Pancreas***

The visible sections of the pancreas are of normal size and echogenic appearance with a regular capsule. Normal echogenic appearance of the mesentery and fat surrounding the pancreas.

***Free Abdomen***

Normal mesenteric lymph nodes.

No ascites evident.

**ULTRASONOGRAPHIC FINDINGS**

- Normal ultrasound examination of the abdomen.

**INTERPRETATION OF THE FINDINGS & FURTHER RECOMMENDATIONS**

On this ultrasound there is no obvious etiology for the intermittent vomiting.

Although the GI tract appears ultrasonographically normal, with the intermittent vomiting, an underlying gastroenteropathy such as chronic gastritis, Helicobacter gastritis, dietary hypersensitivity, parasitic gastroenteritis and inflammatory bowel disease should still be considered.

Further assessment would be fecal analysis, cobalamin and folate assay and endoscopy of the upper GI tract with biopsies.

Specific therapy would be dependent on an etiological diagnosis.

Symptomatic management that can be considered would be feeding small frequent meals of a novel protein/hypoallergenic diet, course of Fenbendazole, cobalamin supplementation and if there is still not a satisfactory improvement then a course of Prednisolone would then be indicated.

Triple therapy for Helicobacter gastritis could also be considered.



**PATIENT**

Mika Negron

**SPECIES**

Canine

**BREED**

Pomeranian

**SEX**

Spayed female

**AGE**

7 years

**WEIGHT**

-

**INTERPRETED BY**

Remo Lobetti, BVSc,  
 MMedVet (Med),  
 PhD, Dipl. ECVIM

**IMAGING PERFORMED BY**

Kerri Becker

**HOSPITAL NAME**

Englewood Cliffs VH

**REFERRING VET**

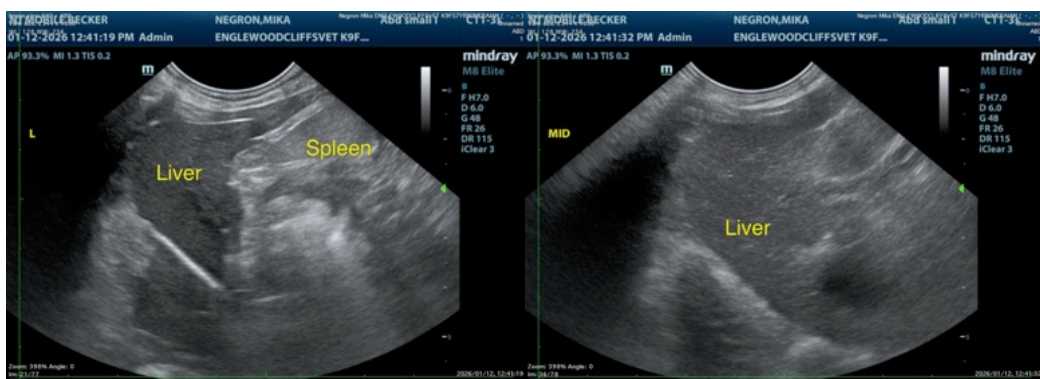
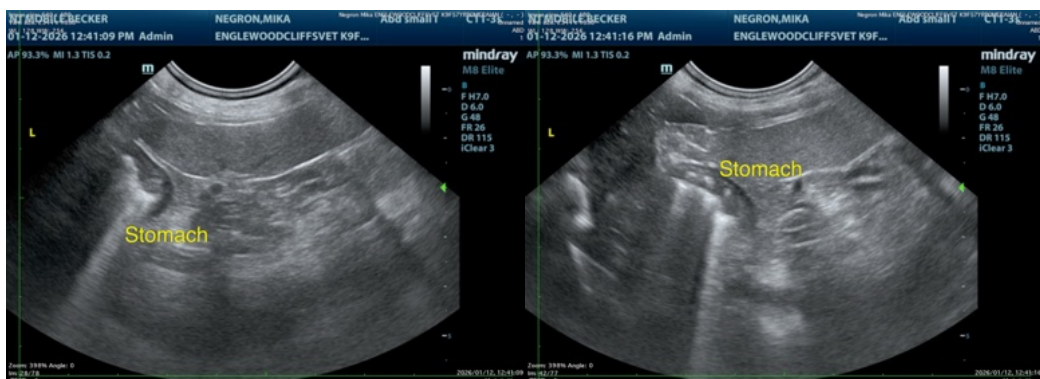
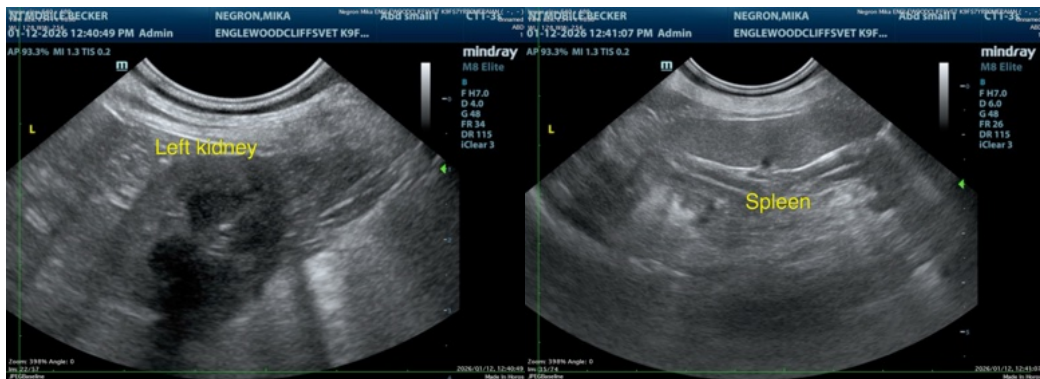
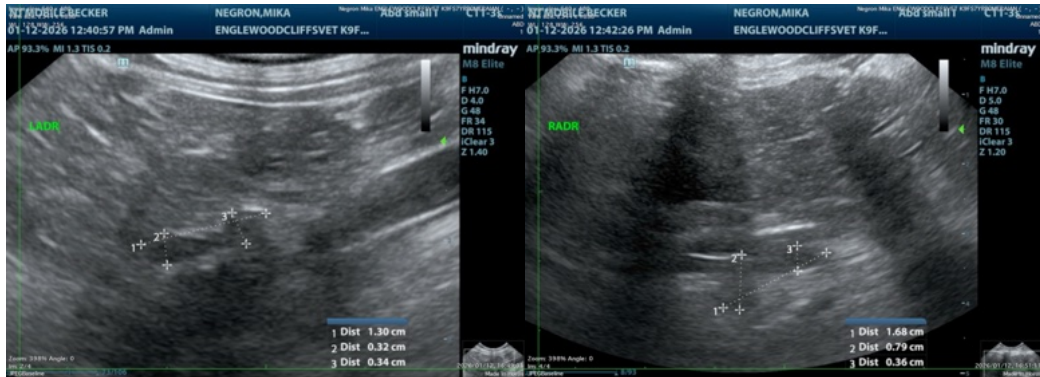
Dr. Park

**INVOICE**

69989

**DATE**

1/12/26





**PATIENT**

Mika Negron

**SPECIES**

Canine

**BREED**

Pomeranian

**SEX**

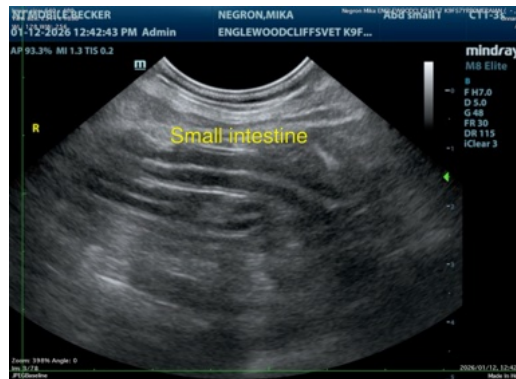Spayed female

**AGE**

7 years

**WEIGHT**

-



The information and recommendations provided are based on the images presented by the referring veterinarian/sonographer. No evaluation can be communicated regarding pathology that was not visible in the image/video clips provided.

Thank you for this referral. If the clinical or image interpretation does not parallel your findings or if I can be of any further assistance please contact me.

**Remo Lobetti, BVSc, MMedVet (Med), PhD, Dipl. ECVIM (Internal Medicine)**

[info@sonopath.com](mailto:info@sonopath.com)

**INTERPRETED BY**

Remo Lobetti, BVSc,  
MMedVet (Med),  
PhD, Dipl. ECVIM

**IMAGING PERFORMED BY**

Kerri Becker

**HOSPITAL NAME**

Englewood Cliffs VH

**REFERRING VET**

Dr. Park

**INVOICE**

69989

**DATE**

1/12/26