



PATIENT

Sadie Quick

SPECIES

Feline

BREED

Siamese

SEX

Spayed female

AGE

7 years

WEIGHT

3.3 kg

INTERPRETED BY

Remo Lobetti, BVSc,
MMedVet (Med),
PhD, Dipl. ECVIM

**IMAGING
PERFORMED BY**

Kelly Reschny

HOSPITAL NAME

Beattie PH of Stoney
Creek

REFERRING VET

Dr. Salib

INVOICE

69155

DATE

11/28/25

PRESENTING CLINICAL SIGNS

History: Diagnosed with mild pancreatitis a couple of weeks ago, no other information given

ULTRASONOGRAPHIC EXAMINATION OF THE ABDOMEN

Urinary System

The urinary bladder is small with a normal thickness and smooth appearance of the wall. Normal anechoic urine with no sediment or uroliths evident.

Normal appearance of the trigone area, proximal urethra, and iliac blood vessels.

Normal appearance and size of the iliac lymph nodes. Ureters not visualized, which can be considered a normal finding.

Normal renal size (left measured 3.5 cm, right measured 3.5 cm), architecture, echogenic appearance, cortico-medullary differentiation, which maintains a 1:3 cortex to medulla ratio, pelvis, and capsule. No infarcts, mineralization or renoliths evident. Normal color flow pattern is evident in both kidneys.

Adrenal Glands

Normal shape, echogenic appearance, size, position, and appearance of the visible peri-adrenal vasculature. Left adrenal gland measured 0.48 cm in length x 0.29 cm in width. The right adrenal gland measured 0.48 cm in length x 0.32 cm in width.

Spleen

Normal size and echogenic appearance. Smooth homogenous parenchyma and regular curvilinear capsule. Normal volume of the splenic vasculature without any overt congestion or thrombosis evident. No inflammatory, neoplastic, infarction, or infiltrative changes evident. The spleen measured 0.9 cm in width.

Liver

Normal size, echogenic appearance, portal markings, and regular curvilinear capsule. No nodules or masses evident. Normal appearance of the hepatic and portal vasculature.

Gallbladder

The gallbladder is small containing normal anechoic bile. Normal thickness and echogenic appearance of the wall. Normal size and appearance of the cystic and common bile duct.



PATIENT

Sadie Quick

SPECIES

Feline

BREED

Siamese

SEX

Spayed female

AGE

7 years

WEIGHT

3.3 kg

INTERPRETED BY

Remo Lobetti, BVSc,
 MMedVet (Med),
 PhD, Dipl. ECVIM

IMAGING PERFORMED BY

Kelly Reschny

HOSPITAL NAME

Beattie PH of Stoney
 Creek

REFERRING VET

Dr. Salib

INVOICE

69155

DATE

11/28/25

Gastrointestinal

Normal appearance of the stomach, duodenum, small intestine, ileo-cecal junction, and colon with no loss of layering, 1:3 muscularis to mucosa ratio, normal wall thickness and peristaltic activity, and no distension of the lumen.

Pancreas

The visible sections of the pancreas are of normal size and echogenic appearance with a regular capsule. Normal echogenic appearance of the mesentery and fat surrounding the pancreas.

Free Abdomen

Normal mesenteric lymph nodes.

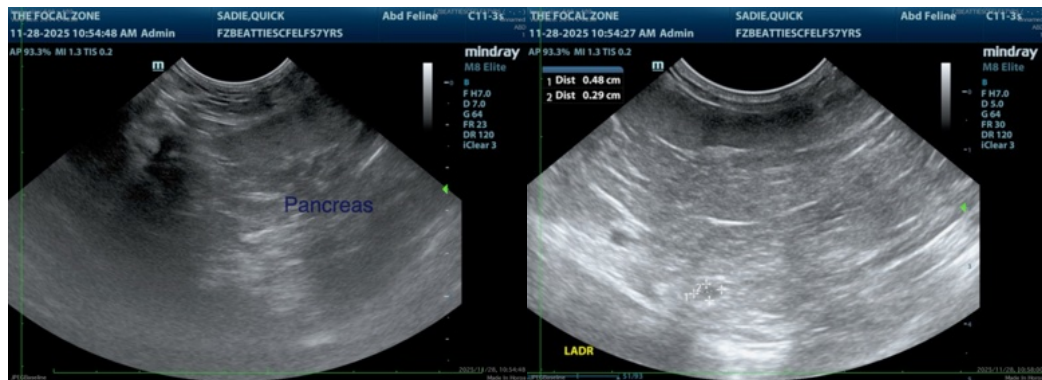
No ascites evident.

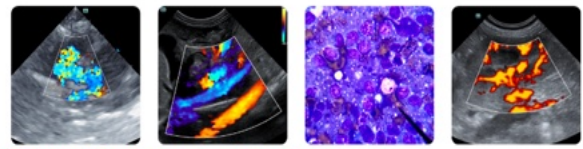
ULTRASONOGRAPHIC FINDINGS

- Normal ultrasound examination of the abdomen.

INTERPRETATION OF THE FINDINGS & FURTHER RECOMMENDATIONS

No specific therapy is recommended at this time.





PATIENT

Sadie Quick

SPECIES

Feline

BREED

Siamese

SEX

Spayed female

AGE

7 years

WEIGHT

3.3 kg

INTERPRETED BY

Remo Lobetti, BVSc,
 MMedVet (Med),
 PhD, Dipl. ECVIM

IMAGING PERFORMED BY

Kelly Reschny

HOSPITAL NAME

Beattie PH of Stoney
 Creek

REFERRING VET

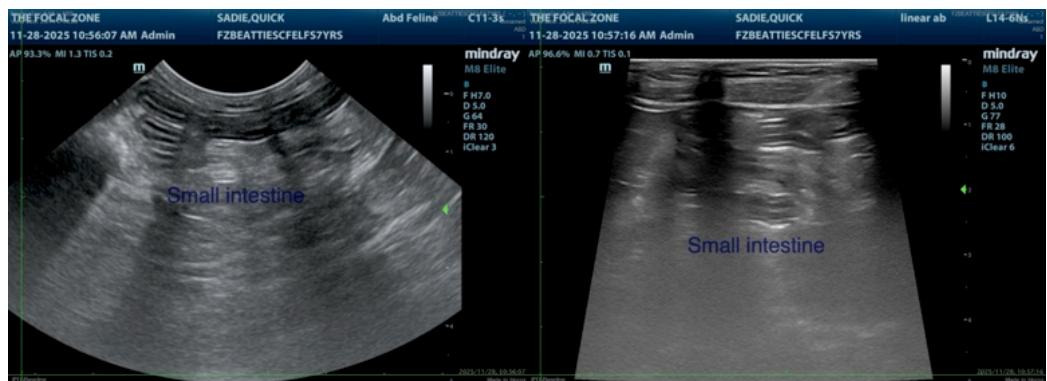
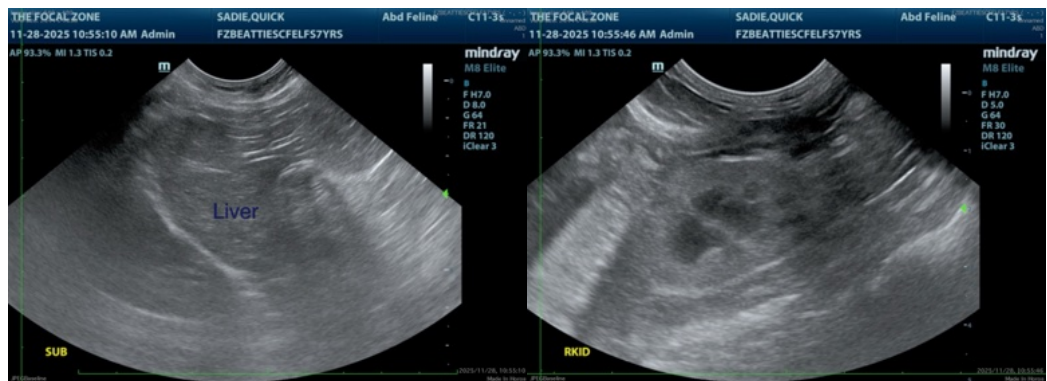
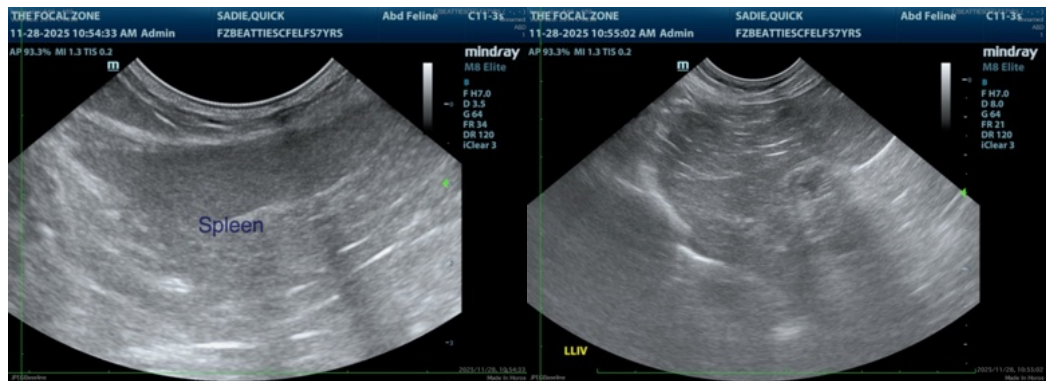
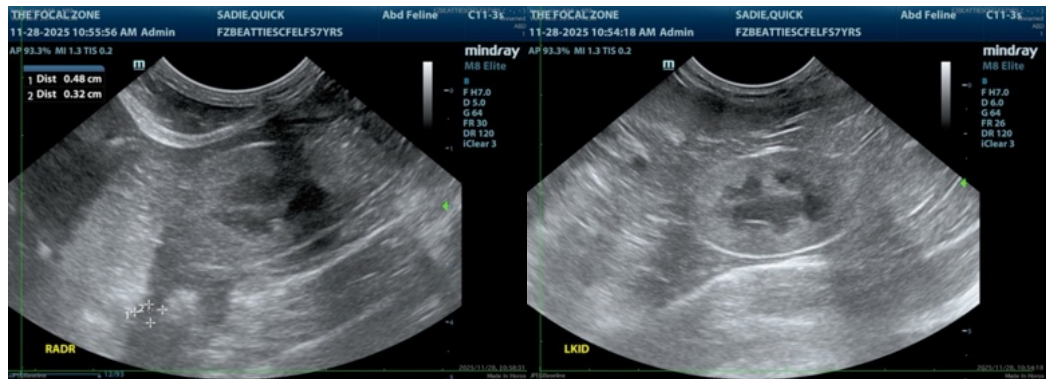
Dr. Salib

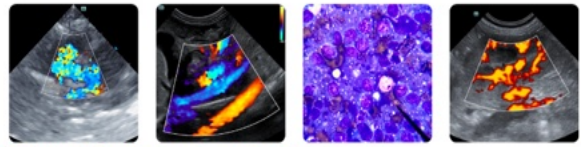
INVOICE

69155

DATE

11/28/25





PATIENT

Sadie Quick

SPECIES

Feline

BREED

Siamese

SEX

Spayed female

AGE

7 years

WEIGHT

3.3 kg

INTERPRETED BY

Remo Lobetti, BVSc,
MMedVet (Med),
PhD, Dipl. ECVIM

**IMAGING
PERFORMED BY**

Kelly Reschny

HOSPITAL NAME

Beattie PH of Stoney
Creek

REFERRING VET

Dr. Salib

INVOICE

69155

DATE

11/28/25

The information and recommendations provided are based on the images presented by the referring veterinarian/sonographer. No evaluation can be communicated regarding pathology that was not visible in the image/video clips provided.

Thank you for this referral. If the clinical or image interpretation does not parallel your findings or if I can be of any further assistance please contact me.

Remo Lobetti, BVSc, MMedVet (Med), PhD, Dipl. ECVIM (Internal Medicine)

info@sonopath.com