



**PATIENT**

Kirsta Barnett

**SPECIES**

Feline

**BREED**

Domestic Shorthair

**SEX**

Spayed female

**AGE**

13 years

**WEIGHT**

6.1 lbs

**INTERPRETED BY**

Remo Lobetti, BVSc,  
 MMedVet (Med),  
 PhD, Dipl. ECVIM

**IMAGING PERFORMED BY**

Ginny Dodd, DVM

**HOSPITAL NAME**

Ironton AH

**REFERRING VET**

Dr. Creech

**INVOICE**

78396

**DATE**

6/4/26

**PRESENTING CLINICAL SIGNS**

History: H/O hyperthyroidism- trt with I 131 and became hypothyroid- has been on thyroxine 100 mcg q 24 hr since. She was also hypertensive also so has also been on Amlodipine 0.625 mg q 24 hr . Now she gets it transdermally. Last BP was 177.

General malaise, decreased appetite, less playful

She seems sicker than her labs show.

Abnormal PE/Chem/CBC/UA Results: PE: BCS 4/9, HR 200, no crackles or wheezes, no palpable abnormalities CBC- not seen CHEM- gluc 197; SDMA 17; creat- normal 1.5; potassium 3.4 sl >; glob 5.0 hi normal; ALT 177 (N < 130), chol 241 ^ (N< 225); TT4 1.1 abd rads 3 mon ago- no masses or foreign bodies noted

**ULTRASONOGRAPHIC EXAMINATION OF THE ABDOMEN**

**Urinary System**

The urinary bladder is full with a normal thickness and smooth appearance of the wall. A scant amount of floating, hyperechogenic sediment.

Normal appearance of the trigone area, proximal urethra, and iliac blood vessels.

Normal appearance and size of the iliac lymph nodes. Ureters not visualized, which can be considered a normal finding.

Normal renal size (left measured 3.1 cm, right measured 3.2 cm), normal echogenic appearance, but some loss of cortico-medullary differentiation, normal pelvis and capsule. No infarcts, mineralization or renoliths evident. Normal color flow pattern is evident in both kidneys.

**Adrenal Glands**

Normal shape, echogenic appearance, size, position, and appearance of the visible peri-adrenal vasculature. Left adrenal gland measured 0.52 cm in length x 0.31 cm in width. The right adrenal gland measured 0.91 cm in length x 0.28 cm and 0.24 cm in width.

**Spleen**

Normal size and echogenic appearance. Smooth homogenous parenchyma and regular curvilinear capsule. Normal volume of the splenic vasculature without any overt congestion or thrombosis evident. No inflammatory, neoplastic, infarction, or infiltrative changes evident. The spleen measured 0.7 cm in width.

**Liver**

Normal size, echogenic appearance, portal markings, and regular curvilinear capsule. No nodules or masses evident. Normal appearance of the hepatic and portal vasculature.



**PATIENT**

Kirsta Barnett

**SPECIES**

Feline

**BREED**

Domestic Shorthair

**SEX**

Spayed female

**AGE**

13 years

**WEIGHT**

6.1 lbs

**INTERPRETED BY**

Remo Lobetti, BVSc,  
MMedVet (Med),  
PhD, Dipl. ECVIM

**IMAGING PERFORMED BY**

Ginny Dodd, DVM

**HOSPITAL NAME**

Ironton AH

**REFERRING VET**

Dr. Creech

**INVOICE**

78396

**DATE**

6/4/26

**Gallbladder**

The gallbladder is small containing normal anechoic bile. Normal thickness and echogenic appearance of the wall. Normal size and appearance of the cystic and common bile duct.

**Gastrointestinal**

Normal appearance of the stomach, duodenum, small intestine, ileo-cecal junction, and colon with no loss of layering, 1:3 muscularis to mucosa ratio, normal wall thickness and peristaltic activity, and no distension of the lumen.

**Pancreas**

Normal size with a hyperechogenic appearance and an irregular capsule. Normal echogenic appearance of the mesentery and fat surrounding the pancreas.

**Free Abdomen**

Normal mesenteric lymph nodes.

No ascites evident.

**ULTRASONOGRAPHIC FINDINGS**

- Renal disease.
- Chronic pancreatitis versus pancreatic fibrosis.

**INTERPRETATION OF THE FINDINGS & FURTHER RECOMMENDATIONS**

The appearance of the kidneys would be consistent with chronic kidney disease with potassium losing neuropathy a possible differential diagnosis.

Further assessment would be urinalysis, possibly urine culture, UPC, fractional clearance of potassium and FPL/PSL assay.

Specific therapy would be dependent on an etiological diagnosis.

Further symptomatic therapy that can be considered would be feeding a renal diet, enteric phosphate binders as needed, potassium supplementation and either an ace inhibitor or receptor blocker.



**PATIENT**

Kirsta Barnett

**SPECIES**

Feline

**BREED**

Domestic Shorthair

**SEX**

Spayed female

**AGE**

13 years

**WEIGHT**

6.1 lbs

**INTERPRETED BY**

Remo Lobetti, BVSc,  
 MMedVet (Med),  
 PhD, Dipl. ECVIM

**IMAGING PERFORMED BY**

Ginny Dodd, DVM

**HOSPITAL NAME**

Ironton AH

**REFERRING VET**

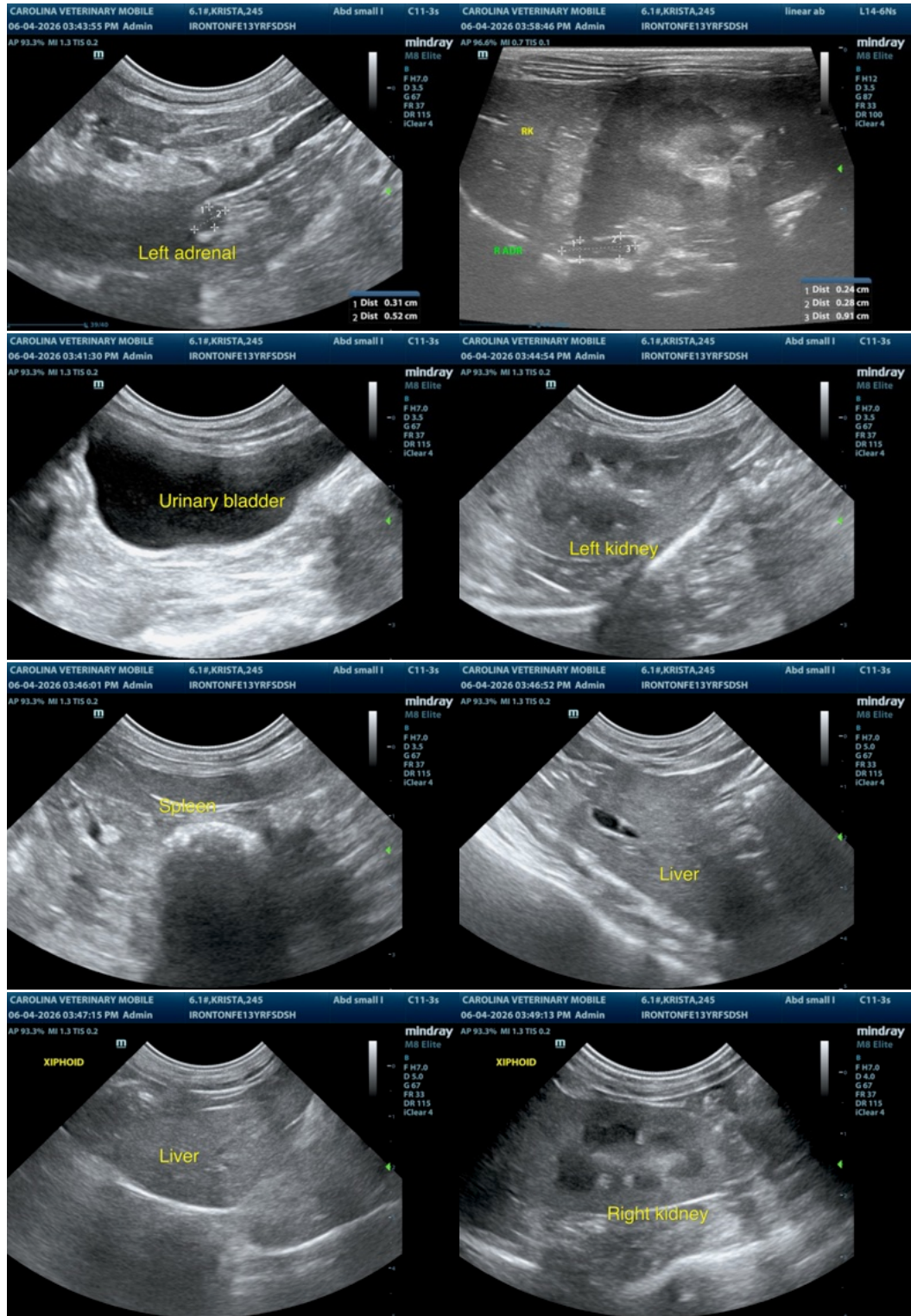
Dr. Creech

**INVOICE**

78396

**DATE**

6/4/26





**PATIENT**

Kirsta Barnett

**SPECIES**

Feline

**BREED**

Domestic Shorthair

**SEX**

Spayed female

**AGE**

13 years

**WEIGHT**

6.1 lbs

**INTERPRETED BY**

Remo Lobetti, BVSc,  
 MMedVet (Med),  
 PhD, Dipl. ECVIM

**IMAGING PERFORMED BY**

Ginny Dodd, DVM

**HOSPITAL NAME**

Ironton AH

**REFERRING VET**

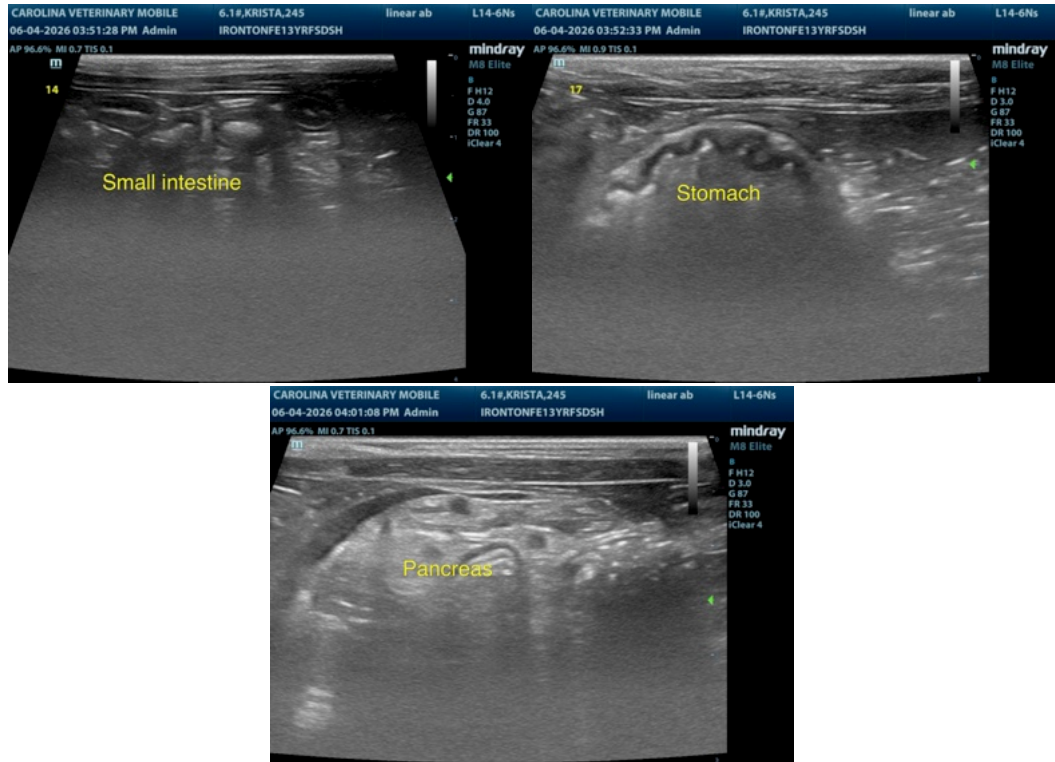
Dr. Creech

**INVOICE**

78396

**DATE**

6/4/26



The information and recommendations provided are based on the images presented by the referring veterinarian/sonographer. No evaluation can be communicated regarding pathology that was not visible in the image/video clips provided.

Thank you for this referral. If the clinical or image interpretation does not parallel your findings or if I can be of any further assistance please contact me.

Remo Lobetti, BVSc, MMedVet (Med), PhD, Dipl. ECVIM (Internal Medicine)

[info@sonopath.com](mailto:info@sonopath.com)