



PATIENT

Maisy Mae McClure

SPECIES

Canine

BREED

Sheltie

SEX

Spayed female

AGE

5 years

WEIGHT

23.4 lbs

INTERPRETED BY

Remo Lobetti, BVSc,
MMedVet (Med),
PhD, Dipl. ECVIM

IMAGING PERFORMED BY

Kathleen Byrnes

HOSPITAL NAME

Stewart's Mountain
View AH

REFERRING VET

Dr. Stewart

INVOICE

75469

DATE

5/13/26

PRESENTING CLINICAL SIGNS

History: P presented for vomiting. Sludge seen in GB, Concern for cholecystitis. P treated supportively. Returned today for repeat bloodwork and US. Bloodwork now normal.
Abnormal PE/Chem/CBC/UA Results: TP 9.7, Alb 4.8, Glob 4.9, ALT 206, Tbili 3.9, Chol 403

ULTRASONOGRAPHIC EXAMINATION OF THE ABDOMEN

Urinary System

The urinary bladder is full with a normal thickness and smooth appearance of the wall. Normal anechoic urine with no sediment or uroliths evident.

Normal appearance of the trigone area, proximal urethra, and iliac blood vessels.

Normal appearance and size of the iliac lymph nodes. Ureters not visualized, which can be considered a normal finding.

Normal renal size (left measured 3.9 cm, right measured 4.5 cm), architecture, echogenic appearance, cortico-medullary differentiation, which maintains a 1:3 cortex to medulla ratio, pelvis, and capsule. No infarcts, mineralization or renoliths evident.

Adrenal Glands

Normal shape, echogenic appearance, size, position, and appearance of the visible peri-adrenal vasculature. Left adrenal gland measured 1.79 cm in length x 0.38 cm and 0.32 cm in width. The right adrenal gland measured 2.09 cm in length x 0.47 cm in width.

Spleen

Normal size and echogenic appearance. Smooth homogenous parenchyma and regular curvilinear capsule. Normal volume of the splenic vasculature without any overt congestion or thrombosis evident. No inflammatory, neoplastic, infarction, or infiltrative changes evident. The spleen measured 1.4 cm in width.

Liver

Normal size, echogenic appearance, portal markings, and regular curvilinear capsule. No nodules or masses evident. Normal appearance of the hepatic and portal vasculature.

Gallbladder

The gallbladder is full containing a moderate amount of non-adhered, hyperechogenic sediment. Normal thickness and echogenic appearance of the wall. Normal size and appearance of the cystic and common bile duct.



PATIENT

Maisy Mae McClure

SPECIES

Canine

BREED

Sheltie

SEX

Spayed female

AGE

5 years

WEIGHT

23.4 lbs

INTERPRETED BY

Remo Lobetti, BVSc,
 MMedVet (Med),
 PhD, Dipl. ECVIM

IMAGING PERFORMED BY

Kathleen Byrnes

HOSPITAL NAME

Stewart's Mountain
 View AH

REFERRING VET

Dr. Stewart

INVOICE

75469

DATE

5/13/26

Gastrointestinal

Normal appearance of the stomach, duodenum, small intestine, ileo-cecal junction, and colon with no loss of layering, 1:3 muscularis to mucosa ratio, normal wall thickness and peristaltic activity, and no distension of the lumen.

Pancreas

Normal size and echogenic appearance with a regular capsule. Normal echogenic appearance of the mesentery and fat surrounding the pancreas.

Free Abdomen

Normal mesenteric lymph nodes.

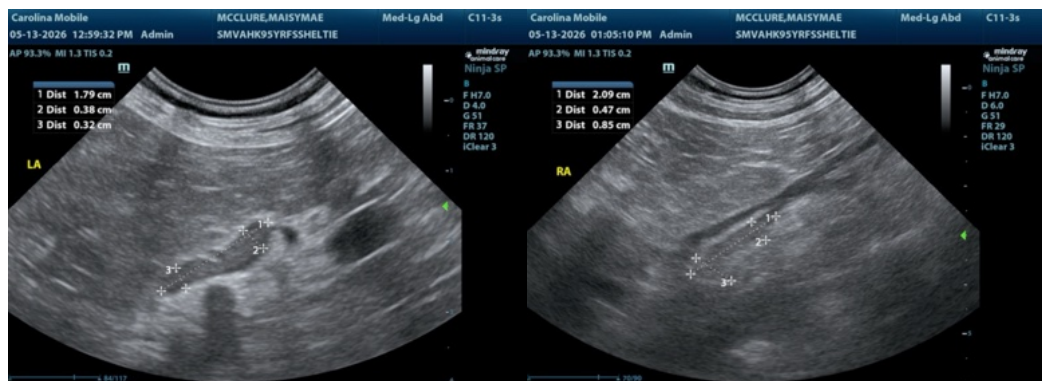
No ascites evident.

ULTRASONOGRAPHIC FINDINGS

- Gallbladder sediment

INTERPRETATION OF THE FINDINGS & FURTHER RECOMMENDATIONS

In essence, a normal ultrasound examination of the abdomen as gallbladder sediment can be considered incidental finding. However, monitoring of possible development of a mucocele would still be recommended.





PATIENT

Maisy Mae McClure

SPECIES

Canine

BREED

Sheltie

SEX

Spayed female

AGE

5 years

WEIGHT

23.4 lbs

INTERPRETED BY

Remo Lobetti, BVSc,
 MMedVet (Med),
 PhD, Dipl. ECVIM

IMAGING PERFORMED BY

Kathleen Byrnes

HOSPITAL NAME

Stewart's Mountain
 View AH

REFERRING VET

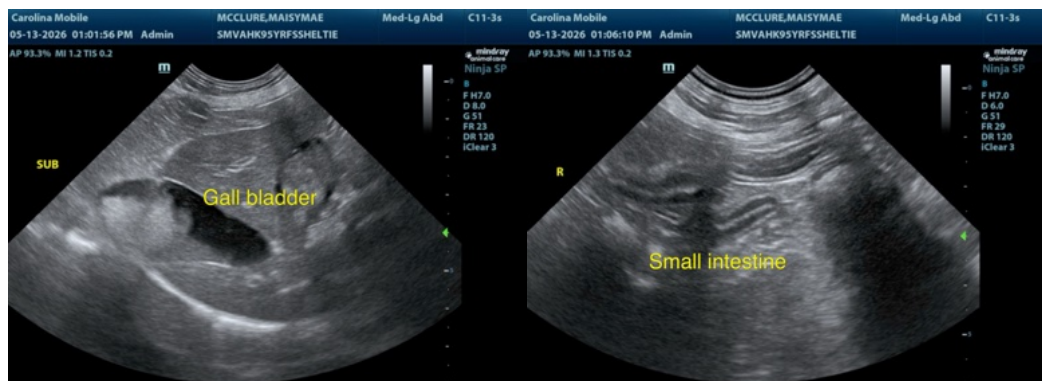
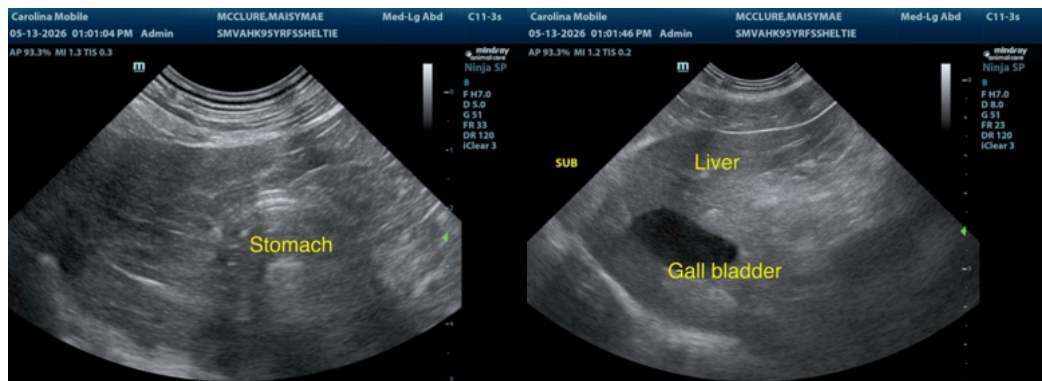
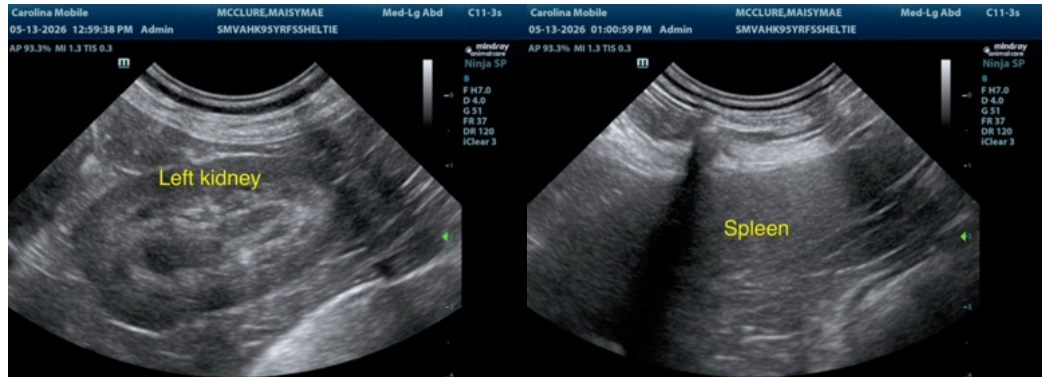
Dr. Stewart

INVOICE

75469

DATE

5/13/26



The information and recommendations provided are based on the images presented by the referring veterinarian/sonographer. No evaluation can be communicated regarding pathology that was not visible in the image/video clips provided.

Thank you for this referral. If the clinical or image interpretation does not parallel your findings or if I can be of any further assistance please contact me.

Remo Lobetti, BVSc, MMedVet (Med), PhD, Dipl. ECVIM (Internal Medicine)

info@sonopath.com