



PATIENT

Tebow Lane

SPECIES

Canine

BREED

Mix

SEX

Neutered male

AGE

14 years

WEIGHT

32.6 lbs

PRESENTING CLINICAL SIGNS

History: P presented for US due to increased panting, restless at night, cough occasionally, weak in rear legs, Muffled heart sounds on exam, ALKP and GGT very elevated

ULTRASONOGRAPHIC EXAMINATION OF THE ABDOMEN

Urinary System

The urinary bladder is small with a normal thickness and smooth appearance of the wall. Normal anechoic urine with no sediment or uroliths evident.

Normal appearance of the trigone area, proximal urethra, and iliac blood vessels.

Normal appearance and size of the iliac lymph nodes. Ureters not visualized, which can be considered a normal finding.

Normal renal size (left measured 5.6 cm, right measured 5.7 cm), increased echogenic appearance, some loss of cortico-medullary differentiation, mild bilateral pyelectasia and a regular, curvilinear capsule. No infarcts, mineralization or renoliths evident.

The prostate was small and hypoechoic measuring 2.5 cm in width.

INTERPRETED BY

Remo Lobetti, BVSc,
MMedVet (Med),
PhD, Dipl. ECVIM

IMAGING PERFORMED BY

Kathleen Byrnes

HOSPITAL NAME

Monroe Road AH

REFERRING VET

Dr. Davis

INVOICE

75086

DATE

5/1/26

Adrenal Glands

Normal shape, echogenic appearance, size, position, and appearance of the visible peri-adrenal vasculature. Left adrenal gland measured 2.02 cm in length x 0.55 cm and 0.39 cm in width. The right adrenal gland measured 2.29 cm in length x 0.63 cm and 0.6 cm in width.

Spleen

Normal size and echogenic appearance. Smooth homogenous parenchyma and regular curvilinear capsule. Normal volume of the splenic vasculature without any overt congestion or thrombosis evident. No inflammatory, neoplastic, infarction, or infiltrative changes evident. The spleen measured 1.8 cm in width.

Liver

Normal size, echogenic appearance, portal markings, and regular curvilinear capsule. Few, hyperechogenic parenchymal nodules measuring up to 1.7 cm in size. No masses evident. Normal appearance of the hepatic and portal vasculature.



PATIENT

Tebow Lane

SPECIES

Canine

BREED

Mix

SEX

Neutered male

AGE

14 years

WEIGHT

32.6 lbs

INTERPRETED BY

Remo Lobetti, BVSc,
 MMedVet (Med),
 PhD, Dipl. ECVIM

IMAGING PERFORMED BY

Kathleen Byrnes

HOSPITAL NAME

Monroe Road AH

REFERRING VET

Dr. Davis

INVOICE

75086

DATE

5/1/26

Gallbladder

The gallbladder is full containing a small amount of non-adhered, hyperechogenic sediment. Normal thickness and echogenic appearance of the wall. Normal size and appearance of the cystic and common bile duct.

Gastrointestinal

Normal appearance of the stomach, duodenum, small intestine, ileo-cecal junction, and colon with no loss of layering, 1:3 muscularis to mucosa ratio, normal wall thickness and peristaltic activity, and no distension of the lumen.

Pancreas

The visible sections of the pancreas are of normal size and echogenic appearance with a regular capsule. Normal echogenic appearance of the mesentery and fat surrounding the pancreas. The right pancreas measures 1.1 cm in width.

Free Abdomen

Normal mesenteric lymph nodes.

No ascites evident.

ULTRASONOGRAPHIC FINDINGS

- Hepatic nodules
- Age related renal changes versus early chronic kidney disease
- Gallbladder sediment

INTERPRETATION OF THE FINDINGS & FURTHER RECOMMENDATIONS

The most likely etiology for the hepatic nodules would be incidental nodular hyperplasia with granulomas and organized hematoma a less likely differential diagnosis.

Emerging neoplasia would be an unlikely differential diagnosis.

The gallbladder sediment is most likely an incidental finding.

Further assessment would be FNA cytology of the hepatic nodules. However, a tru cut or wedge biopsy may be required for a final etiological diagnosis.

Symptomatic management that can be considered would be the use of Ursodiol with regular monitoring of liver enzyme activity.



PATIENT

Tebow Lane

SPECIES

Canine

BREED

Mix

SEX

Neutered male

AGE

14 years

WEIGHT

32.6 lbs

INTERPRETED BY

Remo Lobetti, BVSc,
 MMedVet (Med),
 PhD, Dipl. ECVIM

IMAGING PERFORMED BY

Kathleen Byrnes

HOSPITAL NAME

Monroe Road AH

REFERRING VET

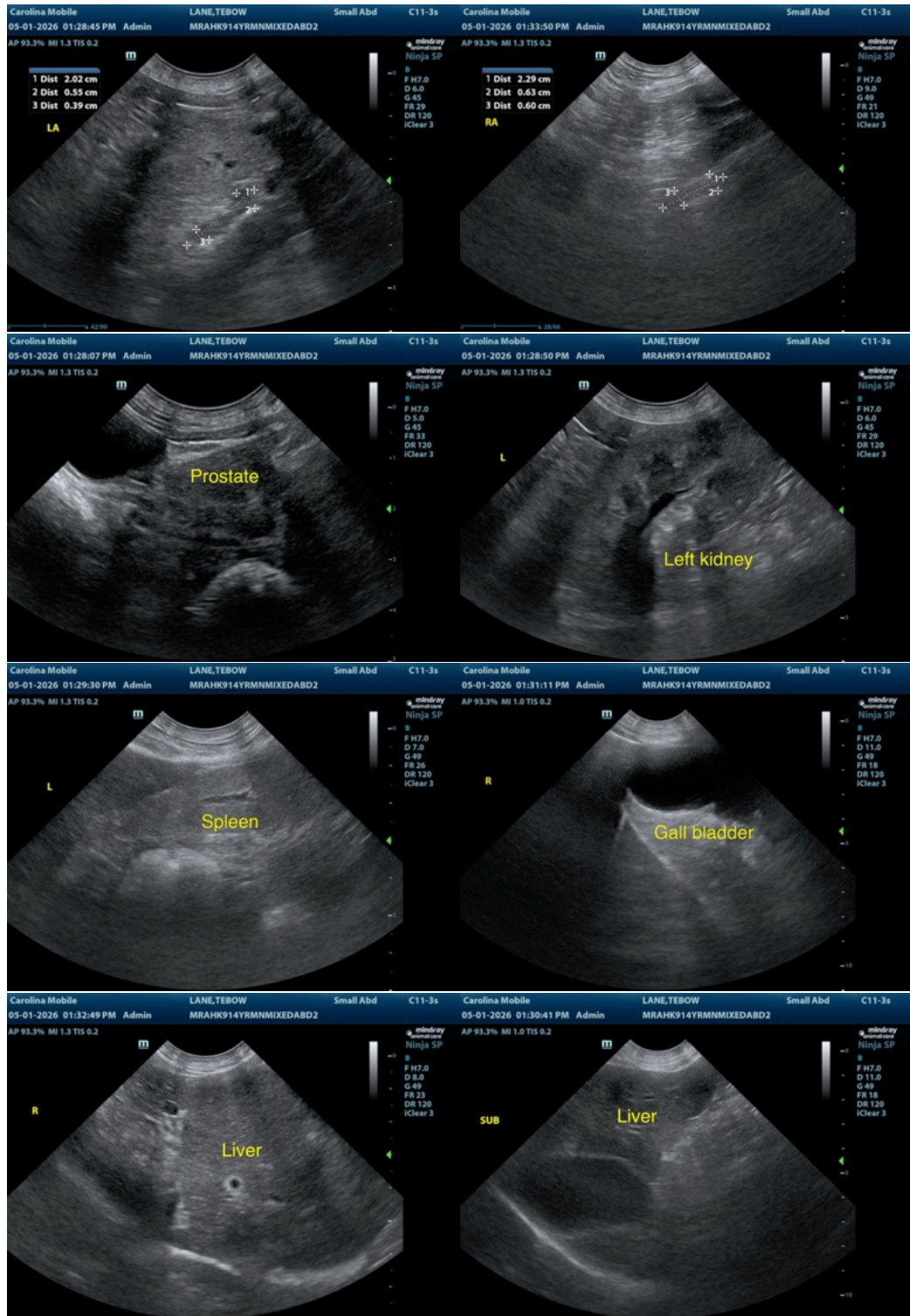
Dr. Davis

INVOICE

75086

DATE

5/1/26





PATIENT

Tebow Lane

SPECIES

Canine

BREED

Mix

SEX

Neutered male

AGE

14 years

WEIGHT

32.6 lbs

INTERPRETED BY

Remo Lobetti, BVSc,
 MMedVet (Med),
 PhD, Dipl. ECVIM

IMAGING PERFORMED BY

Kathleen Byrnes

HOSPITAL NAME

Monroe Road AH

REFERRING VET

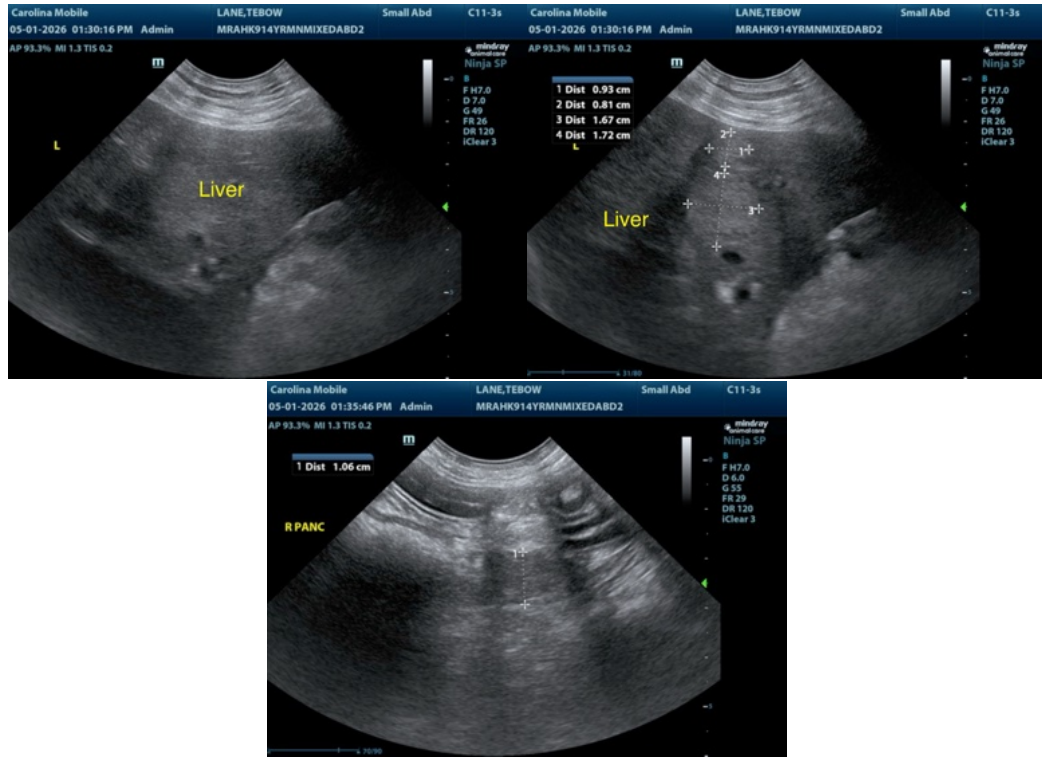
Dr. Davis

INVOICE

75086

DATE

5/1/26



The information and recommendations provided are based on the images presented by the referring veterinarian/sonographer. No evaluation can be communicated regarding pathology that was not visible in the image/video clips provided.

Thank you for this referral. If the clinical or image interpretation does not parallel your findings or if I can be of any further assistance please contact me.

Remo Lobetti, BVSc, MMedVet (Med), PhD, Dipl. ECVIM (Internal Medicine)

info@sonopath.com