



**PATIENT**

Max Griffie

**SPECIES**

Canine

**BREED**

Yorkshire Terrier

**SEX**

Neutered male

**AGE**

11 years

**WEIGHT**

7.4 lbs

**INTERPRETED BY**

Remo Lobetti, BVSc,  
MMedVet (Med),  
PhD, Dipl. ECVIM

**IMAGING PERFORMED BY**

Ginny Dodd, DVM

**HOSPITAL NAME**

Ironton AH

**REFERRING VET**

Dr. Creech

**INVOICE**

74610

**DATE**

4/20/26

**PRESENTING CLINICAL SIGNS**

History: Acute onset of abdominal pain, anorexia  
P CHEM- SDMA 26<sup>^</sup>, creat 2.4<sup>^</sup>, BUN 66, phos 8.8, Ca 6.1<sup>></sup>, posts 7.0<sup>^</sup>E: abdomen distended, bladder distended mild alopecia of ventral abdomen CBC- WBC 8.75, HCT 59.3, abd rads- multiple renoliths, cystoliths

**ULTRASONOGRAPHIC EXAMINATION OF THE ABDOMEN**

**Urinary System**

The urinary bladder is full with a normal thickness and smooth appearance of the wall. A small amount of floating, hyperechogenic sediment as well as small uroliths measuring up to 0.5 cm in size.

Normal appearance of the trigone area and iliac blood vessels. A small lith was present in the proximal urethra.

Normal appearance and size of the iliac lymph nodes. Ureters not visualized, which can be considered a normal finding.

Normal renal size (left measured 3.0 cm, right measured 4.0 cm), architecture, echogenic appearance, cortico-medullary differentiation, which maintains a 1:3 cortex to medulla ratio, pelvis, and capsule. No infarcts or mineralization evident. Bilateral, small, non-obstructive renoliths are present. Normal color flow pattern is evident in both kidneys.

The prostate is small and hypoechogenic measuring 0.5 cm in width.

**Adrenal Glands**

Normal shape, echogenic appearance, size, position, and appearance of the visible peri-adrenal vasculature. Left adrenal gland measured 1.54 cm in length x 0.58 cm and 0.52 cm in width. The right adrenal gland measured 1.2 cm in length x 0.41 cm and 0.51 cm in width.

**Spleen**

Normal size and echogenic appearance. Smooth homogenous parenchyma and regular curvilinear capsule. Normal volume of the splenic vasculature without any overt congestion or thrombosis evident. No inflammatory, neoplastic, infarction, or infiltrative changes evident. The spleen measured 1.2 cm in width.

**Liver**

Normal size, echogenic appearance, portal markings, and regular curvilinear capsule. No nodules or masses evident. Normal appearance of the hepatic and portal vasculature.



**PATIENT**

Max Griffie

**SPECIES**

Canine

**BREED**

Yorkshire Terrier

**SEX**

Neutered male

**AGE**

11 years

**WEIGHT**

7.4 lbs

**INTERPRETED BY**

Remo Lobetti, BVSc,  
MMedVet (Med),  
PhD, Dipl. ECVIM

**IMAGING PERFORMED BY**

Ginny Dodd, DVM

**HOSPITAL NAME**

Ironton AH

**REFERRING VET**

Dr. Creech

**INVOICE**

74610

**DATE**

4/20/26

**Gallbladder**

The gallbladder is full containing a small amount of non-adhered, hyperechogenic sediment. Normal thickness and echogenic appearance of the wall. Normal size and appearance of the cystic and common bile duct.

**Gastrointestinal**

Normal appearance of the stomach, duodenum, small intestine, ileo-cecal junction, and colon with no loss of layering, 1:3 muscularis to mucosa ratio, normal wall thickness and peristaltic activity, and no distension of the lumen.

**Pancreas**

The visible sections of the pancreas are of normal size and echogenic appearance with a regular capsule. Normal echogenic appearance of the mesentery and fat surrounding the pancreas.

**Free Abdomen**

Normal mesenteric lymph nodes.

No ascites evident.

**ULTRASONOGRAPHIC FINDINGS**

- Renoliths.
- Uroliths.
- Urethral lith.
- Urinary and gallbladder sediment.

**INTERPRETATION OF THE FINDINGS & FURTHER RECOMMENDATIONS**

Etiologies for the urinary bladder sediment would be crystalluria, hematuria and possibly bacterial cystitis.

The gallbladder sediment can be considered an incidental finding.

Further assessment would be urethral catheterization, urinalysis and urine culture.

Surgical removal of the uroliths may be required.

Specific therapy would be dependent on an etiological diagnosis.

Long term management of the urinary tract liths would be dietary therapy based on analysis of the uroliths.



**PATIENT**

Max Griffie

**SPECIES**

Canine

**BREED**

Yorkshire Terrier

**SEX**

Neutered male

**AGE**

11 years

**WEIGHT**

7.4 lbs

**INTERPRETED BY**

Remo Lobetti, BVSc,  
 MMedVet (Med),  
 PhD, Dipl. ECVIM

**IMAGING PERFORMED BY**

Ginny Dodd, DVM

**HOSPITAL NAME**

Ironton AH

**REFERRING VET**

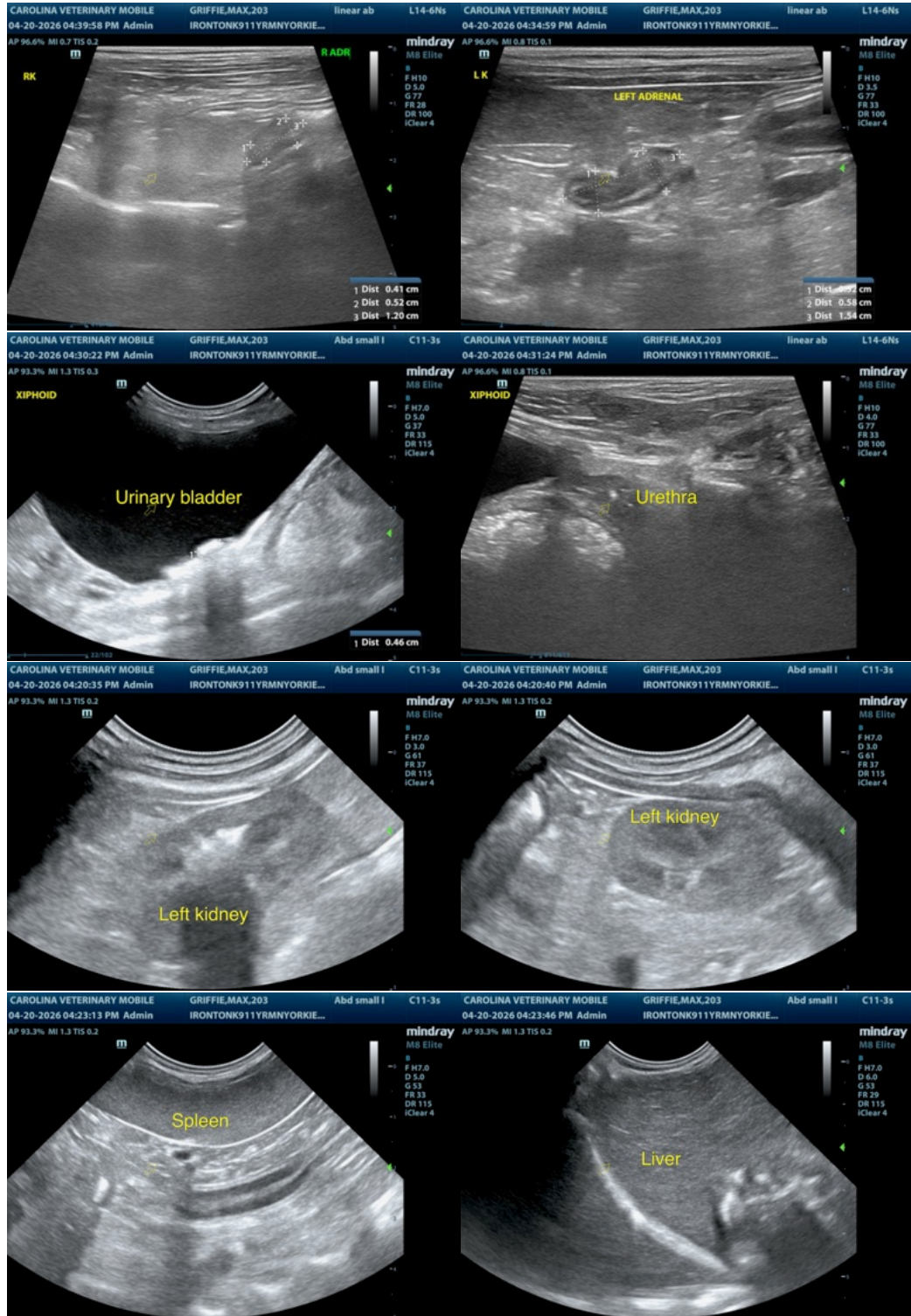
Dr. Creech

**INVOICE**

74610

**DATE**

4/20/26





**PATIENT**

Max Griffie

**SPECIES**

Canine

**BREED**

Yorkshire Terrier

**SEX**

Neutered male

**AGE**

11 years

**WEIGHT**

7.4 lbs

**INTERPRETED BY**

Remo Lobetti, BVSc,  
 MMedVet (Med),  
 PhD, Dipl. ECVIM

**IMAGING PERFORMED BY**

Ginny Dodd, DVM

**HOSPITAL NAME**

Ironton AH

**REFERRING VET**

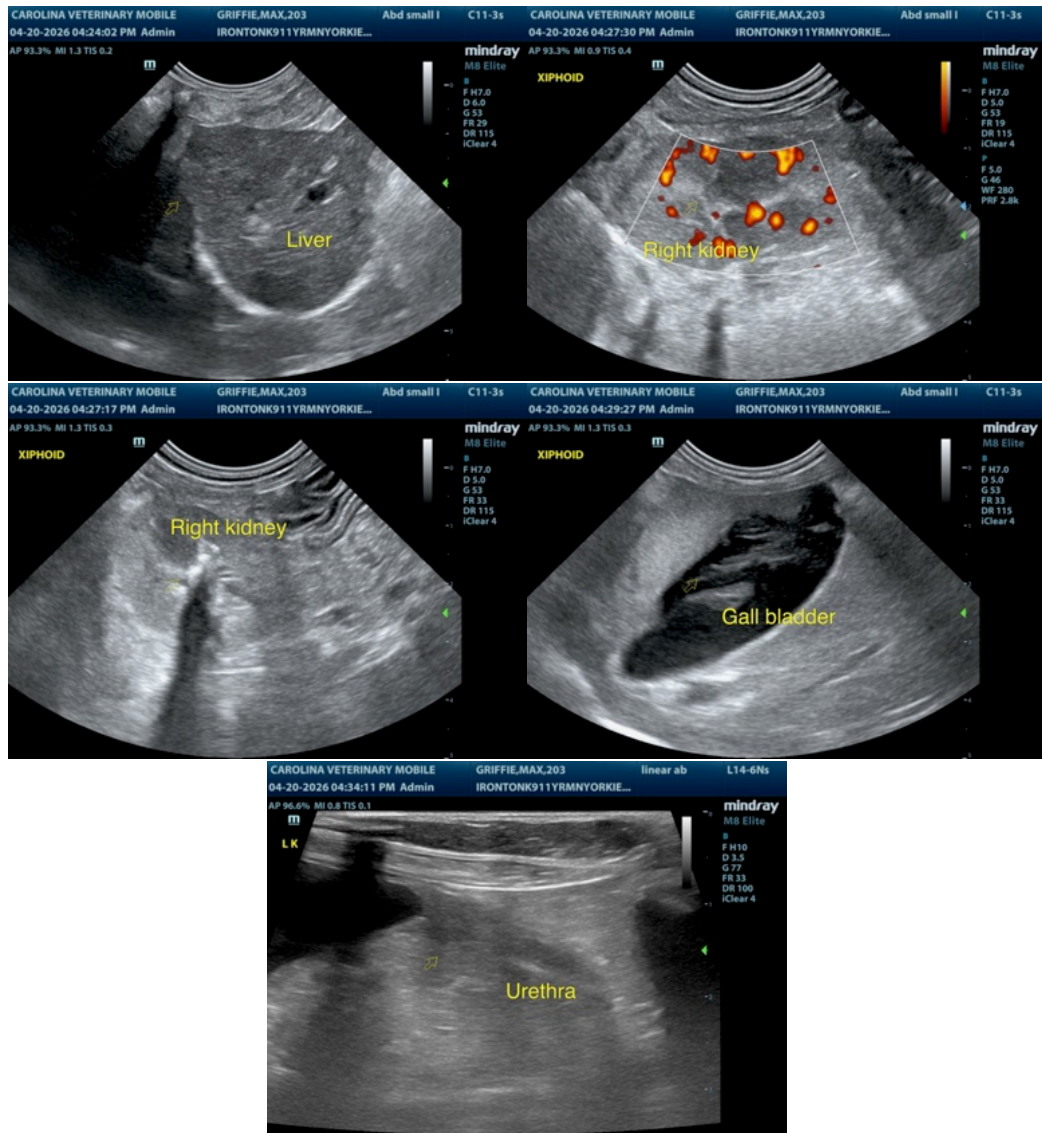
Dr. Creech

**INVOICE**

74610

**DATE**

4/20/26



The information and recommendations provided are based on the images presented by the referring veterinarian/sonographer. No evaluation can be communicated regarding pathology that was not visible in the image/video clips provided.

Thank you for this referral. If the clinical or image interpretation does not parallel your findings or if I can be of any further assistance please contact me.

Remo Lobetti, BVSc, MMedVet (Med), PhD, Dipl. ECVIM (Internal Medicine)

[info@sonopath.com](mailto:info@sonopath.com)