



**PATIENT**

Salomon Bialski

**SPECIES**

Canine

**BREED**

Bully Mix

**SEX**

Neutered male

**AGE**

13 years

**WEIGHT**

57.5 lbs

**INTERPRETED BY**

Remo Lobetti, BVSc,  
 MMedVet (Med),  
 PhD, Dipl. ECVIM

**IMAGING PERFORMED BY**

Ginny Dodd, DVM

**HOSPITAL NAME**

Steele Creek AH

**REFERRING VET**

Dr. Young

**INVOICE**

73739

**DATE**

3/24/26

**PRESENTING CLINICAL SIGNS**

- Multiple subcutaneous mast cell tumors excised 5 yr ago
- Routine monitoring-and AUS-no significant abnormalities
- Had gallbladder mucocele excised 2 yr ago
- Currently has no clinical signs
- CBC normal CHEM- slight ^ ALKP

**ULTRASONOGRAPHIC EXAMINATION OF THE ABDOMEN**

**Urinary System**

The urinary bladder is small with a normal thickness and smooth appearance of the wall. Normal anechoic urine with no sediment or uroliths evident.

Normal appearance of the trigone area, proximal urethra, and iliac blood vessels.

Normal appearance and size of the iliac lymph nodes. Ureters not visualized, which can be considered a normal finding.

Normal renal size (left measured 6.1 cm, right measured 6.1 cm), architecture, echogenic appearance, cortico-medullary differentiation, which maintains a 1:3 cortex to medulla ratio, pelvis, and capsule. No infarcts, mineralization or renoliths evident. Normal color pattern is evident in the kidneys.

The prostate is small and hypoechogenic measuring 1.1 cm in width.

**Adrenal Glands**

Normal shape, echogenic appearance, size, position, and appearance of the visible peri-adrenal vasculature. Left adrenal gland measured 2.62 cm in length x 0.58 cm and 0.54 cm in width. The right adrenal gland measured 1.92 cm in length x 0.69 cm and 0.56 cm in width.

**Spleen**

Normal size (1.9 cm in width) with a diffuse, mottled echogenic appearance and regular regular curvilinear capsule. Normal volume of the splenic vasculature without any overt congestion or thrombosis evident. No inflammatory, neoplastic, infarction, or infiltrative changes evident.

**Liver**

Normal size, echogenic appearance, portal markings, and regular curvilinear capsule. No nodules or masses evident. Normal appearance of the hepatic and portal vasculature.



**PATIENT**

Salomon Bialski

**SPECIES**

Canine

**BREED**

Bully Mix

**SEX**

Neutered male

**AGE**

13 years

**WEIGHT**

57.5 lbs

**INTERPRETED BY**

Remo Lobetti, BVSc,  
 MMedVet (Med),  
 PhD, Dipl. ECVIM

**IMAGING PERFORMED BY**

Ginny Dodd, DVM

**HOSPITAL NAME**

Steele Creek AH

**REFERRING VET**

Dr. Young

**INVOICE**

73739

**DATE**

3/24/26

**Gallbladder**

The gallbladder is absent (previous cholecystectomy).

**Gastrointestinal**

Normal appearance of the stomach, duodenum, small intestine, ileo-cecal junction, and colon with no loss of layering, 1:3 muscularis to mucosa ratio, normal wall thickness and peristaltic activity, and no distension of the lumen.

**Pancreas**

The visible sections of the pancreas are of normal size and echogenic appearance with a regular capsule. Normal echogenic appearance of the mesentery and fat surrounding the pancreas.

**Free Abdomen**

Normal mesenteric lymph nodes.

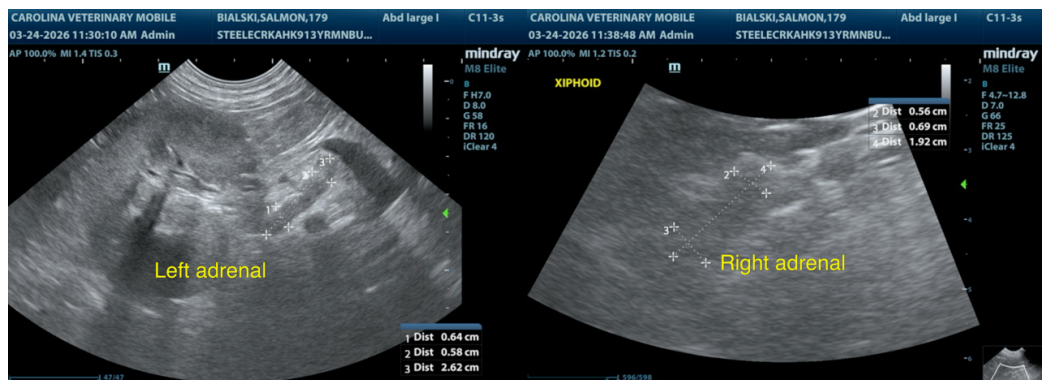
No ascites evident.

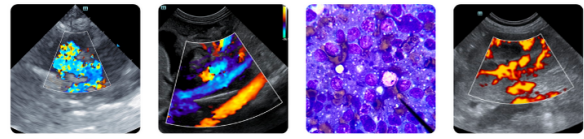
**ULTRASONOGRAPHIC FINDINGS**

- Normal ultrasound examination of the abdomen.

**INTERPRETATION OF THE FINDINGS & FURTHER RECOMMENDATIONS**

The appearance of the spleen can be considered an incidental age related finding.





**PATIENT**

Salomon Bialski

**SPECIES**

Canine

**BREED**

Bully Mix

**SEX**

Neutered male

**AGE**

13 years

**WEIGHT**

57.5 lbs

**INTERPRETED BY**

Remo Lobetti, BVSc,  
 MMedVet (Med),  
 PhD, Dipl. ECVIM

**IMAGING PERFORMED BY**

Ginny Dodd, DVM

**HOSPITAL NAME**

Steele Creek AH

**REFERRING VET**

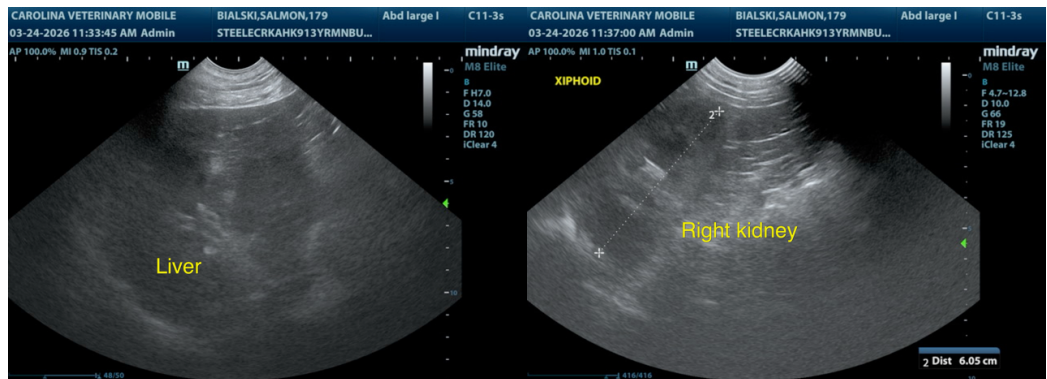
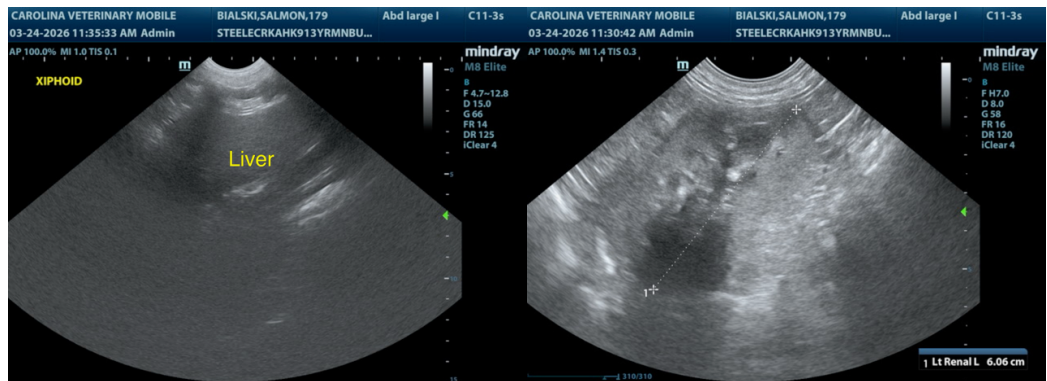
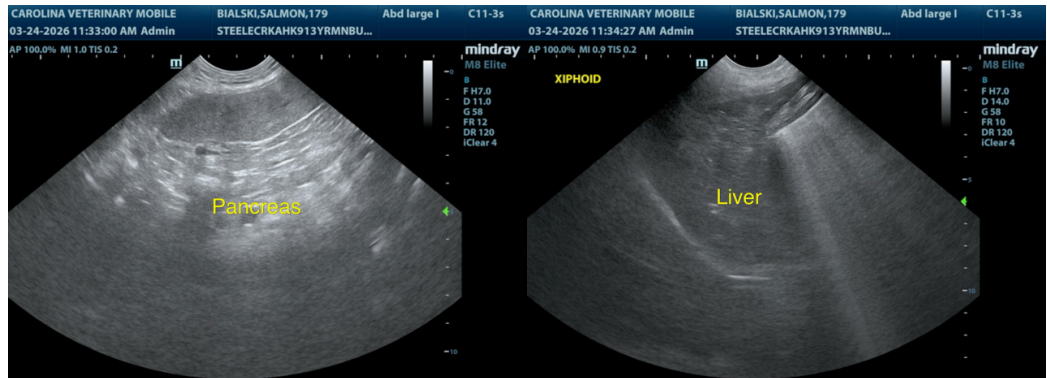
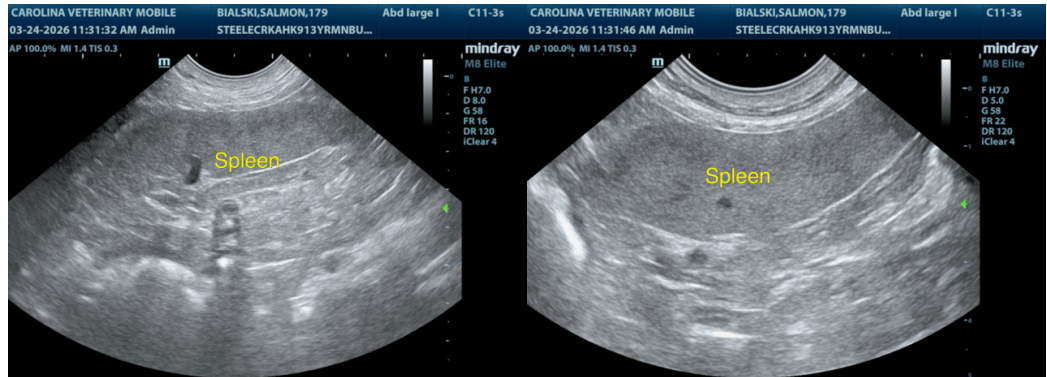
Dr. Young

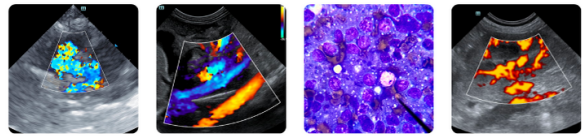
**INVOICE**

73739

**DATE**

3/24/26





**PATIENT**

Salomon Bialski

**SPECIES**

Canine

**BREED**

Bully Mix

**SEX**

Neutered male

**AGE**

13 years

**WEIGHT**

57.5 lbs

**INTERPRETED BY**

Remo Lobetti, BVSc,  
MMedVet (Med),  
PhD, Dipl. ECVIM

**IMAGING PERFORMED BY**

Ginny Dodd, DVM

**HOSPITAL NAME**

Steele Creek AH

**REFERRING VET**

Dr. Young

**INVOICE**

73739

**DATE**

3/24/26

The information and recommendations provided are based on the images presented by the referring veterinarian/sonographer. No evaluation can be communicated regarding pathology that was not visible in the image/video clips provided.

Thank you for this referral. If the clinical or image interpretation does not parallel your findings or if I can be of any further assistance please contact me.

Remo Lobetti, BVSc, MMedVet (Med), PhD, Dipl. ECVIM (Internal Medicine)

[info@sonopath.com](mailto:info@sonopath.com)