



PATIENT

Chencho Cruz

SPECIES

Feline

BREED

Domestic Medium Hair

SEX

Neutered male

AGE

2 years

WEIGHT

10 lbs

INTERPRETED BY

Remo Lobetti, BVSc,
 MMedVet (Med),
 PhD, Dipl. ECVIM

IMAGING PERFORMED BY

Kathleen Byrnes

HOSPITAL NAME

Chatham Veterinary
 Services

REFERRING VET

Dr. Weiser

INVOICE

73448

DATE

3/12/26

PRESENTING CLINICAL SIGNS

- P presented for losing weight, vomited a worm, and then vomited blood today. not eating well. P is icteric and lethargic
- HCT 30%, Neu 2.2 Bands suspected, PLT 63 Glob 5.4, Tbili 8.5, ALKP <10, GGT 1,

ULTRASONOGRAPHIC EXAMINATION OF THE ABDOMEN

Urinary System

The urinary bladder is full with a normal thickness and smooth appearance of the wall. Normal anechoic urine with no sediment or uroliths evident.

Normal appearance of the trigone area, proximal urethra, and iliac blood vessels.

Normal appearance and size of the iliac lymph nodes. Ureters not visualized, which can be considered a normal finding.

The kidneys are bilaterally enlarged with normal echogenic appearance, but some loss of corticomedullary differentiation and normal pelvis and capsule. No infarcts, mineralization or renoliths evident. Normal color flow pattern is noted in both kidneys. The left kidney measured 5.0 cm. The right kidney measured 5.2 cm.

Adrenal Glands

Normal shape, echogenic appearance, size, position, and appearance of the visible peri-adrenal vasculature. Left adrenal gland measured 0.94 cm in length x 0.42 cm and 0.42 cm in width. The right adrenal gland measured 0.72 cm in length x 0.4 cm in width.

Spleen

The spleen is enlarged (1.2 cm in width) with a diffuse, increased echogenic and fine nodular appearance, but maintained a regular curvilinear capsule. Normal volume of the splenic vasculature without any overt congestion or thrombosis evident.

Liver

The liver is enlarged with a diffuse increased echogenic appearance, normal portal markings, and regular curvilinear capsule. No nodules or masses evident. Normal appearance of the hepatic and portal vasculature.

Gallbladder

The gallbladder is small containing normal anechoic bile. Thickened and hyperechogenic appearance of the wall (0.2 cm). Normal size and appearance of the cystic and common bile duct.



PATIENT

Chencho Cruz

SPECIES

Feline

BREED

Domestic Medium Hair

SEX

Neutered male

AGE

2 years

WEIGHT

10 lbs

INTERPRETED BY

Remo Lobetti, BVSc,
MMedVet (Med),
PhD, Dipl. ECVIM

**IMAGING
PERFORMED BY**

Kathleen Byrnes

HOSPITAL NAME

Chatham Veterinary
Services

REFERRING VET

Dr. Weiser

INVOICE

73448

DATE

3/12/26

Gastrointestinal

Normal appearance of the stomach, duodenum, small intestine, ileo-cecal junction, and colon with no loss of layering, 1:3 muscularis to mucosa ratio, normal wall thickness and peristaltic activity, and no distension of the lumen.

Pancreas

The pancreas is enlarged (left pancreas measured 1.1 cm in width) with a hypoechoic appearance and an irregular capsule. Mild increase in the echogenic appearance of the mesentery and fat surrounding the pancreas.

Free Abdomen

Enlarged mesenteric lymph nodes measuring up to 0.6 x 1.5 cm in size with a hypoechoic appearance and some shadowing a rounded shape.

No ascites evident.

ULTRASONOGRAPHIC FINDINGS

- Splenic pathology.
- Hepatopathy.
- Mesenteric lymphadenomegaly.
- Pancreatitis.
- Renal disease.
- Cholecystitis.

INTERPRETATION OF THE FINDINGS & FURTHER RECOMMENDATIONS

The appearance of the spleen and the mesenteric lymph nodes would be consistent with lymphoma with granulomatous disease such as FIP a differential diagnosis with both the renal disease and the hepatopathy ascribed to either lymphoma or granulomatous disease.

Initial further assessment would be FNA cytology of the spleen, liver and mesenteric lymph nodes.

Specific therapy would be dependent on an etiological diagnosis.



PATIENT

Chencho Cruz

SPECIES

Feline

BREED

Domestic Medium Hair

SEX

Neutered male

AGE

2 years

WEIGHT

10 lbs

INTERPRETED BY

Remo Lobetti, BVSc,
 MMedVet (Med),
 PhD, Dipl. ECVIM

IMAGING PERFORMED BY

Kathleen Byrnes

HOSPITAL NAME

Chatham Veterinary
 Services

REFERRING VET

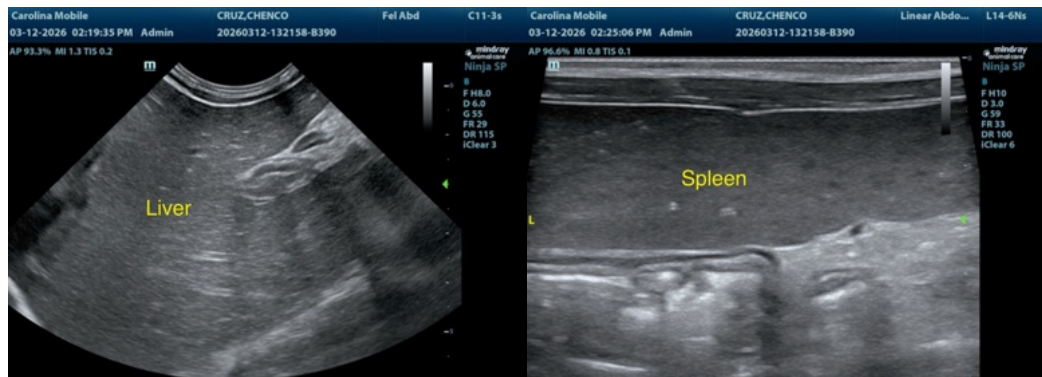
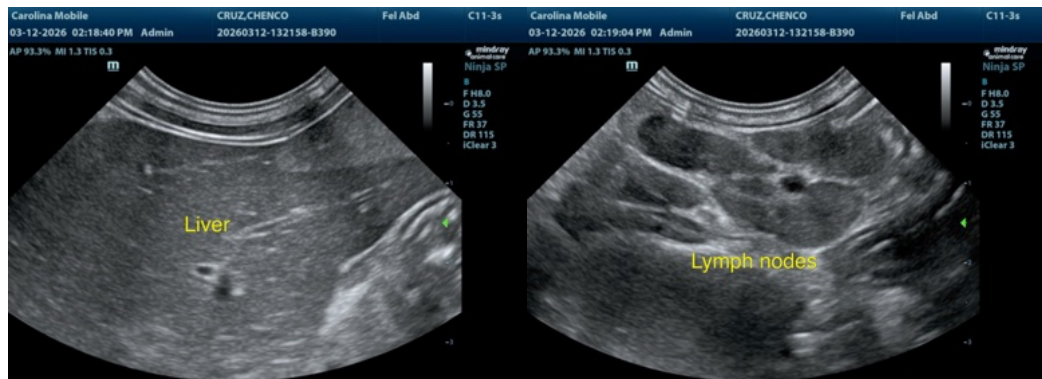
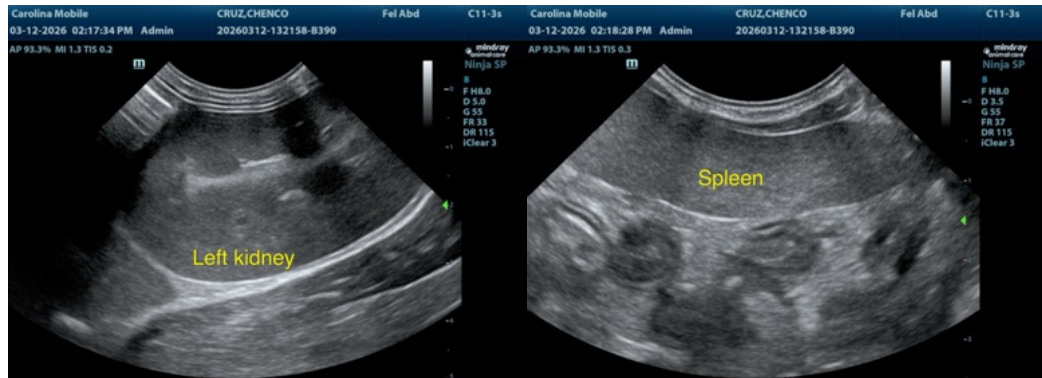
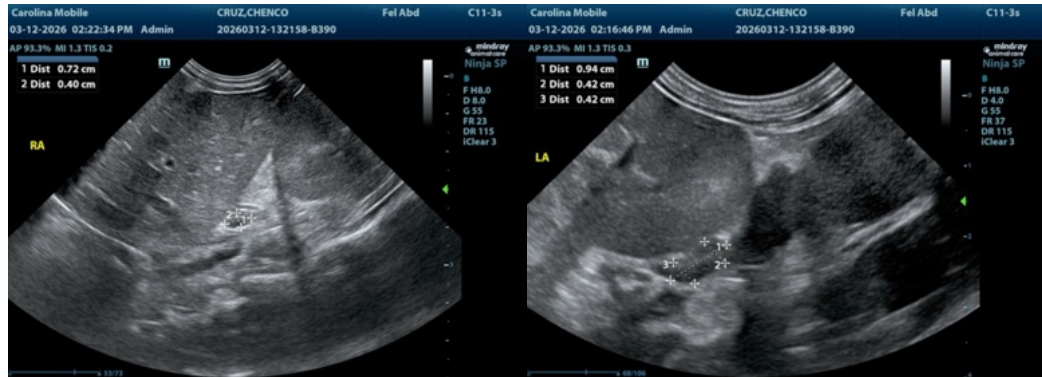
Dr. Weiser

INVOICE

73448

DATE

3/12/26





PATIENT

Chencho Cruz

SPECIES

Feline

BREED

Domestic Medium Hair

SEX

Neutered male

AGE

2 years

WEIGHT

10 lbs

INTERPRETED BY

Remo Lobetti, BVSc,
 MMedVet (Med),
 PhD, Dipl. ECVIM

IMAGING PERFORMED BY

Kathleen Byrnes

HOSPITAL NAME

Chatham Veterinary
 Services

REFERRING VET

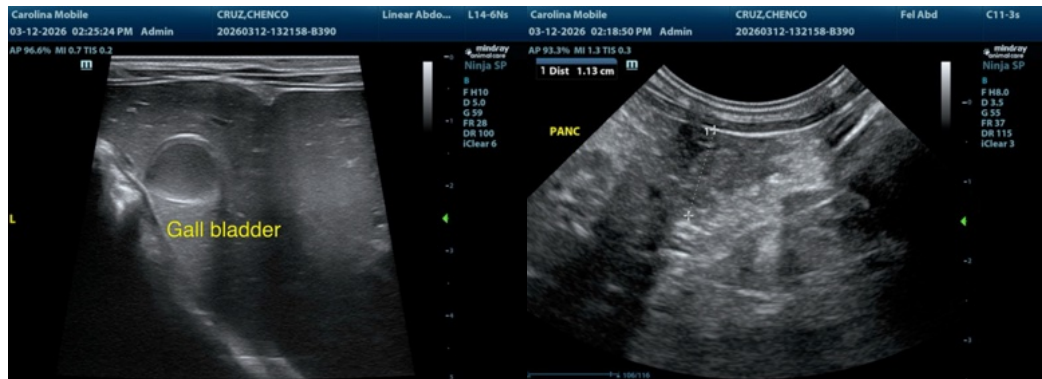
Dr. Weiser

INVOICE

73448

DATE

3/12/26



The information and recommendations provided are based on the images presented by the referring veterinarian/sonographer. No evaluation can be communicated regarding pathology that was not visible in the image/video clips provided.

Thank you for this referral. If the clinical or image interpretation does not parallel your findings or if I can be of any further assistance please contact me.

Remo Lobetti, BVSc, MMedVet (Med), PhD, Dipl. ECVIM (Internal Medicine)

info@sonopath.com