



PATIENT

Bacchus Basso

SPECIES

Canine

BREED

Golden Retriever

SEX

Neutered male

AGE

8 years

WEIGHT

70 lbs

INTERPRETED BY

Remo Lobetti, BVSc,
MMedVet (Med),
PhD, Dipl. ECVIM

IMAGING PERFORMED BY

Ginny Dodd, DVM

HOSPITAL NAME

All Creatures

REFERRING VET

Dr. McLean

INVOICE

71526

DATE

2/12/26

PRESENTING CLINICAL SIGNS

- Routine scans of spleen to check for HSA- last one on 9/2/25 by Dr. Scott Tidwell showed anechoic to hypo echoic avascular nodules 4- 5 mm in the spleen- r/o lymphoid hyperplasia. Advised recheck in 3 months.
- PE: eupneic, BCS 5/9, no palpable masses CBC- WNL CHEM- WNL Parasites- neg HWM- neg ag

ULTRASONOGRAPHIC EXAMINATION OF THE ABDOMEN

Urinary System

The urinary bladder is small with a normal thickness and smooth appearance of the wall. Normal anechoic urine with no sediment or uroliths evident.

Normal appearance of the trigone area, proximal urethra, and iliac blood vessels.

Normal appearance and size of the iliac lymph nodes. Ureters not visualized, which can be considered a normal finding.

Normal renal size (left measured 5.8 cm, right measured 5.5 cm), architecture, echogenic appearance, cortico-medullary differentiation, which maintains a 1:3 cortex to medulla ratio, pelvis, and capsule. No infarcts, mineralization or renoliths evident. Normal color flow pattern is evident in both kidneys.

The prostate is small and hypoechogenic measuring 1.3 cm in width.

Adrenal Glands

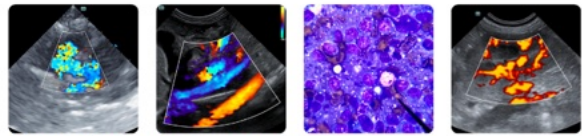
Normal shape, echogenic appearance, size, position, and appearance of the visible peri-adrenal vasculature. Left adrenal gland measured 2.74 cm in length x 0.68 cm and 0.61 cm in width. The right adrenal gland measured 2.02 cm. in length x 0.76 cm and 0.59 cm in width.

Spleen

Normal size and echogenic appearance. Smooth homogenous parenchyma and regular curvilinear capsule. Normal volume of the splenic vasculature without any overt congestion or thrombosis evident. No inflammatory, neoplastic, infarction, or infiltrative changes evident. The spleen measured 1.9 cm in width.

Liver

Normal size, echogenic appearance, portal markings, and regular curvilinear capsule. No nodules or masses evident. Normal appearance of the hepatic and portal vasculature.



PATIENT

Bacchus Basso

SPECIES

Canine

BREED

Golden Retriever

SEX

Neutered male

AGE

8 years

WEIGHT

70 lbs

INTERPRETED BY

Remo Lobetti, BVSc,
MMedVet (Med),
PhD, Dipl. ECVIM

**IMAGING
PERFORMED BY**

Ginny Dodd, DVM

HOSPITAL NAME

All Creatures

REFERRING VET

Dr. McLean

INVOICE

71526

DATE

2/12/26

Gallbladder

The gallbladder is full containing normal anechoic bile. Normal thickness and echogenic appearance of the wall. Normal size and appearance of the cystic and common bile duct.

Gastrointestinal

Normal appearance of the stomach, duodenum, small intestine, ileo-cecal junction, and colon with no loss of layering, 1:3 muscularis to mucosa ratio, normal wall thickness and peristaltic activity, and no distension of the lumen. A small amount of gas and ingesta was present in the stomach compatible with a recent meal.

Pancreas

The visible sections of the pancreas are of normal size and echogenic appearance with a regular capsule. Normal echogenic appearance of the mesentery and fat surrounding the pancreas.

Free Abdomen

Normal mesenteric lymph nodes.

No ascites evident.

Thorax

Normal appearance of the heart. No pericardial or pleural effusion evident.

ULTRASONOGRAPHIC FINDINGS

- Normal ultrasound examination of the abdomen.

INTERPRETATION OF THE FINDINGS & FURTHER RECOMMENDATIONS

No specific therapy is recommended at this time.



PATIENT

Bacchus Basso

SPECIES

Canine

BREED

Golden Retriever

SEX

Neutered male

AGE

8 years

WEIGHT

70 lbs

INTERPRETED BY

Remo Lobetti, BVSc,
 MMedVet (Med),
 PhD, Dipl. ECVIM

IMAGING PERFORMED BY

Ginny Dodd, DVM

HOSPITAL NAME

All Creatures

REFERRING VET

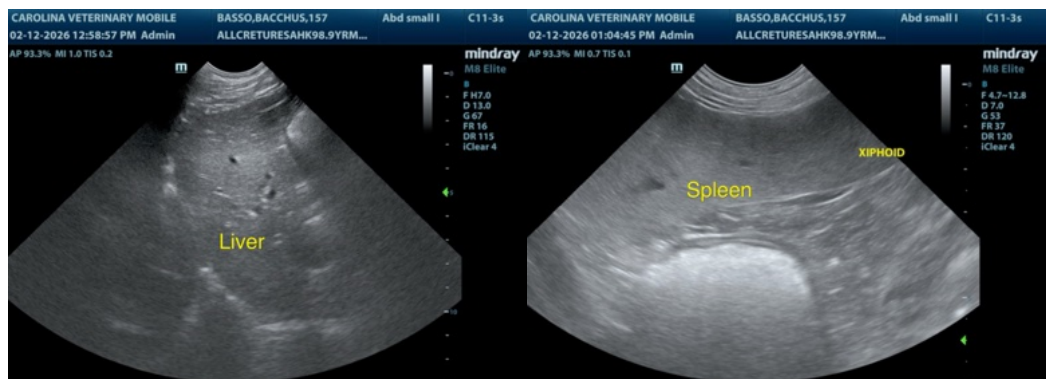
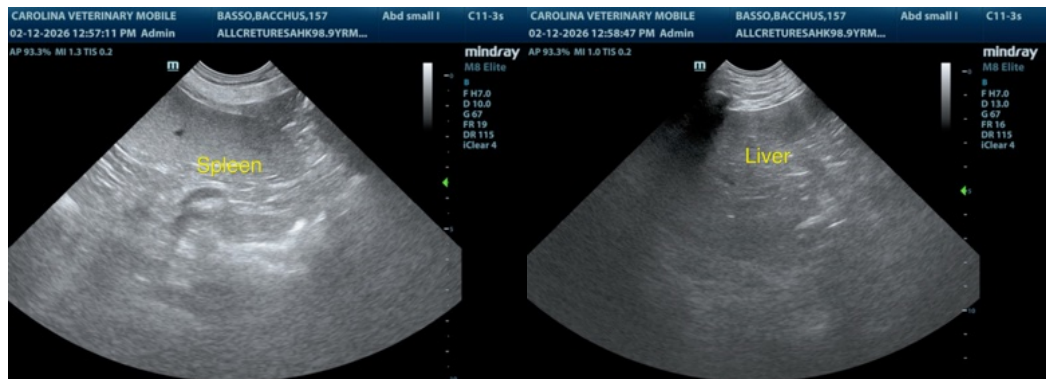
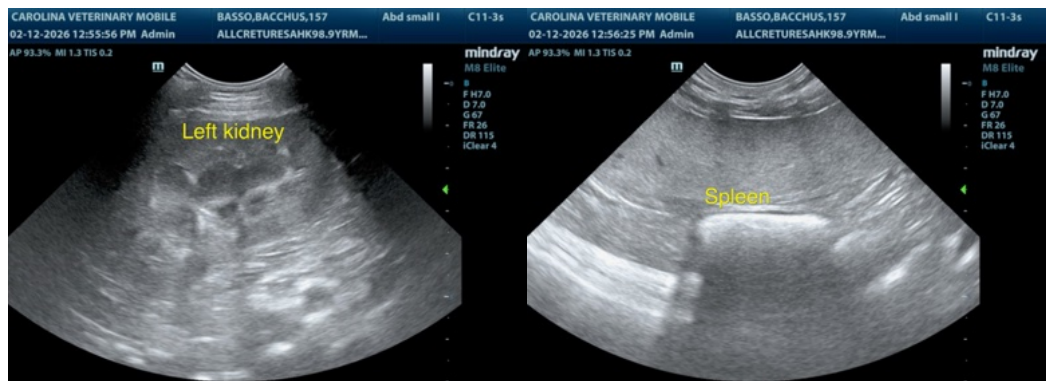
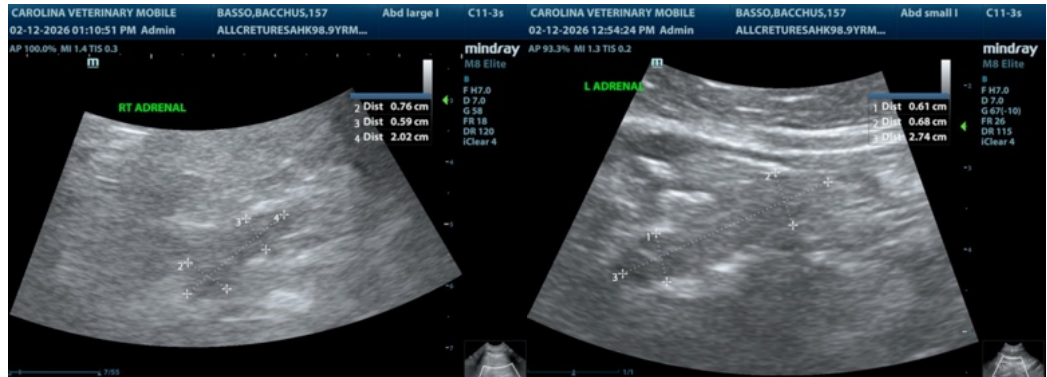Dr. McLean

INVOICE

71526

DATE

2/12/26





PATIENT

Bacchus Basso

SPECIES

Canine

BREED

Golden Retriever

SEX

Neutered male

AGE

8 years

WEIGHT

70 lbs

INTERPRETED BY

Remo Lobetti, BVSc,
MMedVet (Med),
PhD, Dipl. ECVIM

**IMAGING
PERFORMED BY**

Ginny Dodd, DVM

HOSPITAL NAME

All Creatures

REFERRING VET

Dr. McLean

INVOICE

71526

DATE

2/12/26

The information and recommendations provided are based on the images presented by the referring veterinarian/sonographer. No evaluation can be communicated regarding pathology that was not visible in the image/video clips provided.

Thank you for this referral. If the clinical or image interpretation does not parallel your findings or if I can be of any further assistance please contact me.

Remo Lobetti, BVSc, MMedVet (Med), PhD, Dipl. ECVIM (Internal Medicine)

info@sonopath.com