



**PATIENT**

Oliver Nelson

**SPECIES**

Canine

**BREED**

Retriever Mix

**SEX**

Neutered male

**AGE**

9 years

**WEIGHT**

79 lbs

**INTERPRETED BY**

Remo Lobetti, BVSc,  
MMedVet (Med),  
PhD, Dipl. ECVIM

**IMAGING PERFORMED BY**

Kathleen Byrnes

**HOSPITAL NAME**

Armstrong Animal  
Clinic

**REFERRING VET**

Dr. Dolan

**INVOICE**

69472

**DATE**

12/22/25

**PRESENTING CLINICAL SIGNS**

History: P initially presented for mobility issues and pain in hind limbs Concern for other issue going on with elevated liver values

Abnormal PE/Chem/CBC/UA Results: ALKP 1,101 (previously 167 last year)

**ULTRASONOGRAPHIC EXAMINATION OF THE ABDOMEN**

**Urinary System**

The urinary bladder is full with a normal thickness and smooth appearance of the wall. Normal anechoic urine with no sediment or uroliths evident.

Normal appearance of the trigone area, proximal urethra, and iliac blood vessels.

Normal appearance and size of the iliac lymph nodes. Ureters not visualized, which can be considered a normal finding.

Normal renal size (left measured 8.3 cm, right measured 7.9 cm), architecture, echogenic appearance, cortico-medullary differentiation, which maintains a 1:3 cortex to medulla ratio, pelvis, and capsule. No infarcts, mineralization or renoliths evident. Normal color flow pattern is evident in both kidneys.

The prostate is small and hypoechogenic measuring 1.1 cm in width.

**Adrenal Glands**

Normal shape, echogenic appearance, size, position, and appearance of the visible peri-adrenal vasculature. Left adrenal gland measured 3.43 cm in length x 0.85 cm and 0.93 cm in width. The right adrenal gland measured 3.16 cm in length x 0.77 cm in width.

**Spleen**

Normal size and echogenic appearance. Smooth homogenous parenchyma and regular curvilinear capsule. Normal volume of the splenic vasculature without any overt congestion or thrombosis evident. No inflammatory, neoplastic, infarction, or infiltrative changes evident. The spleen measured 3.0 cm in width.

**Liver**

Normal size with a diffuse, increased echogenic and coarse appearance, normal portal markings, and regular curvilinear capsule. No nodules or masses evident. Normal appearance of the hepatic and portal vasculature.



**PATIENT**

Oliver Nelson

**SPECIES**

Canine

**BREED**

Retriever Mix

**SEX**

Neutered male

**AGE**

9 years

**WEIGHT**

79 lbs

**INTERPRETED BY**

Remo Lobetti, BVSc,  
MMedVet (Med),  
PhD, Dipl. ECVIM

**IMAGING PERFORMED BY**

Kathleen Byrnes

**HOSPITAL NAME**

Armstrong Animal  
Clinic

**REFERRING VET**

Dr. Dolan

**INVOICE**

69472

**DATE**

12/22/25

***Gallbladder***

The gallbladder is small containing a small amount of non-adhered, hyperechogenic sediment. Normal thickness and echogenic appearance of the wall. Normal size and appearance of the cystic and common bile duct.

***Gastrointestinal***

Normal appearance of the stomach, duodenum, small intestine, ileo-cecal junction, and colon with no loss of layering, 1:3 muscularis to mucosa ratio, normal wall thickness and peristaltic activity, and no distension of the lumen.

***Pancreas***

The visible sections of the pancreas are of normal size and echogenic appearance with a regular capsule. Normal echogenic appearance of the mesentery and fat surrounding the pancreas.

***Free Abdomen***

Normal mesenteric lymph nodes.

No ascites evident.

Normal size and ratio of the portal vein, caudal vena cava and aorta. The portal vein measured 0.94 cm in diameter, caudal vena cava measured 0.89 cm in diameter, aorta measured 0.88 cm in diameter.

**ULTRASONOGRAPHIC FINDINGS**

- Hepatopathy.
- Gallbladder sediment.

**INTERPRETATION OF THE FINDINGS & FURTHER RECOMMENDATIONS**

The likely etiologies for the hepatopathy would be reactive hyperplasia, early nodular hyperplasia, vacuolar and metabolic with hepatitis and infiltrative neoplasia a highly unlikely differential diagnosis.

The gallbladder sediment is an incidental finding.

Further assessment would be FNA cytology of the liver; however, a tru cut or wedge biopsy may be required for a final etiological diagnosis.

Specific therapy would be dependent on an etiological diagnosis. Symptomatic management that can be considered for the hepatopathy and the gallbladder sediment would be the use of Ursodiol with regular monitoring of liver enzyme activity.



**PATIENT**

Oliver Nelson

**SPECIES**

Canine

**BREED**

Retriever Mix

**SEX**

Neutered male

**AGE**

9 years

**WEIGHT**

79 lbs

**INTERPRETED BY**

Remo Lobetti, BVSc,  
 MMedVet (Med),  
 PhD, Dipl. ECVIM

**IMAGING PERFORMED BY**

Kathleen Byrnes

**HOSPITAL NAME**

Armstrong Animal  
 Clinic

**REFERRING VET**

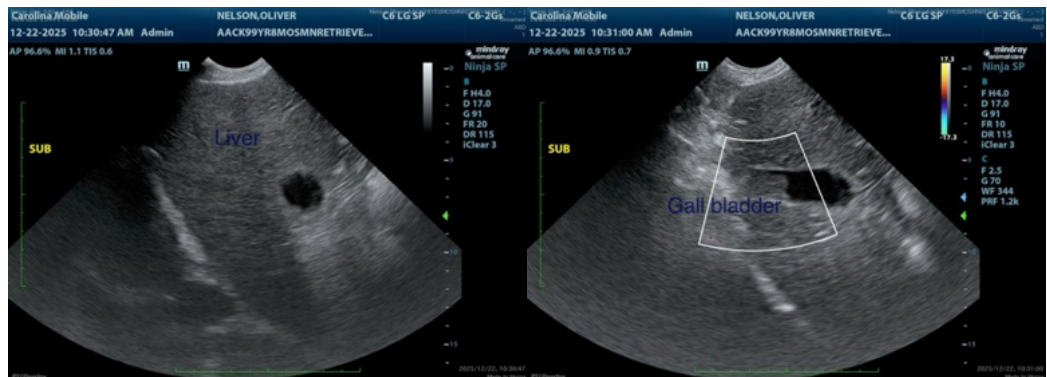
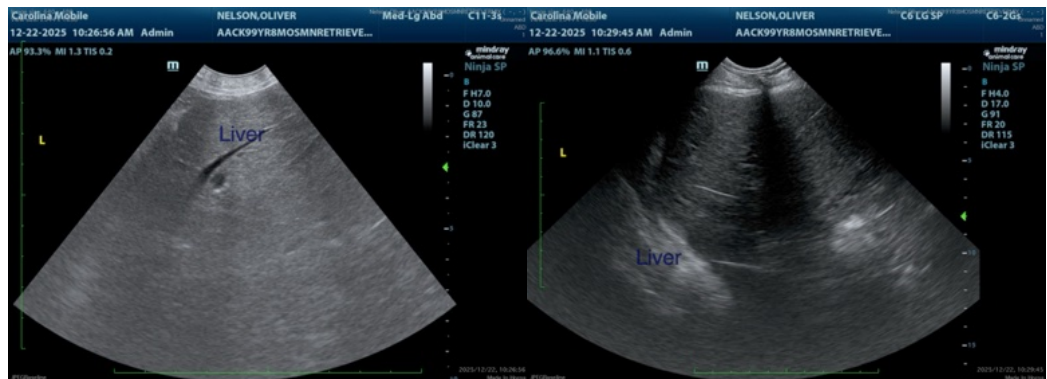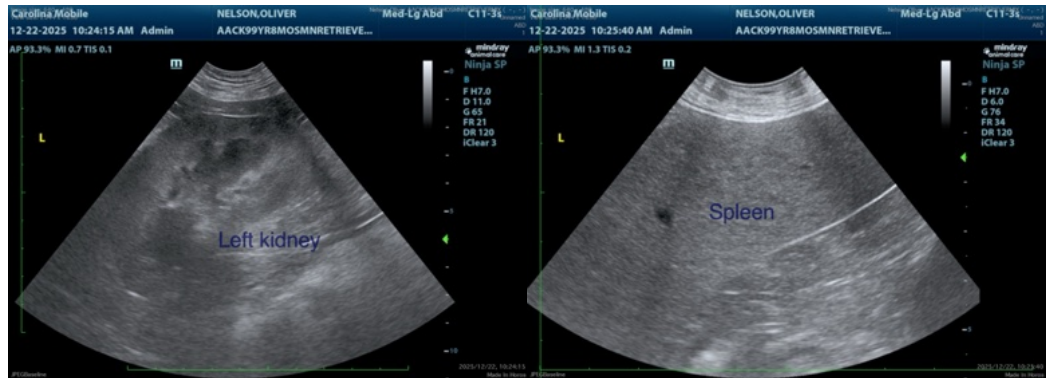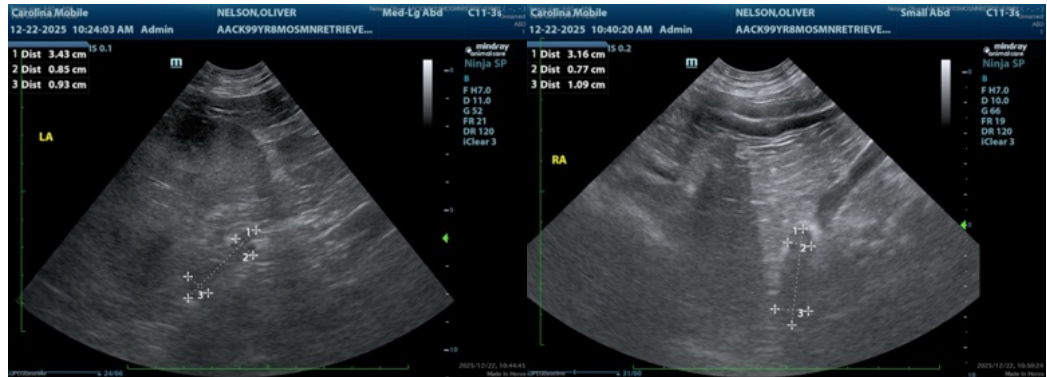Dr. Dolan

**INVOICE**

69472

**DATE**

12/22/25





**PATIENT**

Oliver Nelson

**SPECIES**

Canine

**BREED**

Retriever Mix

**SEX**

Neutered male

**AGE**

9 years

**WEIGHT**

79 lbs

**INTERPRETED BY**

Remo Lobetti, BVSc, MMedVet (Med), PhD, Dipl. ECVIM

**IMAGING PERFORMED BY**

Kathleen Byrnes

**HOSPITAL NAME**

Armstrong Animal Clinic

**REFERRING VET**

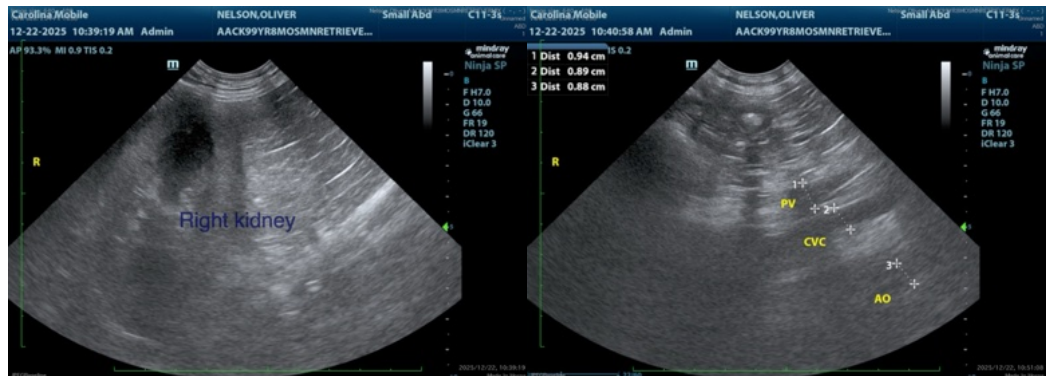
Dr. Dolan

**INVOICE**

69472

**DATE**

12/22/25



The information and recommendations provided are based on the images presented by the referring veterinarian/sonographer. No evaluation can be communicated regarding pathology that was not visible in the image/video clips provided.

Thank you for this referral. If the clinical or image interpretation does not parallel your findings or if I can be of any further assistance please contact me.

Remo Lobetti, BVSc, MMedVet (Med), PhD, Dipl. ECVIM (Internal Medicine)

[info@sonopath.com](mailto:info@sonopath.com)