



PATIENT

Jackson Rogers

SPECIES

Canine

BREED

Boston Terrier

SEX

Neutered male

AGE

12 years

WEIGHT

25.3 lbs

INTERPRETED BY

Remo Lobetti, BVSc,
 MMedVet (Med),
 PhD, Dipl. ECVIM

IMAGING PERFORMED BY

Kathleen Byrnes

HOSPITAL NAME

Scotts Creek AH

REFERRING VET

Dr. Rendazzo

INVOICE

69953

DATE

1/9/26

PRESENTING CLINICAL SIGNS

History: P presented for stiffness in hind legs, PU/PD, incontinence, loose stools RDVM fast scan-suspect bladder mass, liver enlarged, hyperechoic mass
 Glu 139, K+ 5.5, CI 101, ALT 273, ALP 2254, GGT 165, Chol 384, CK 305, Monos 1004, Eos 36 T4 0.7 usg 1.038, Prot 3+, Bld 2+, Epith 1+, Rbcs 20-30 per hpf ACTH Stim Pre 2.62, Post 14.34

ULTRASONOGRAPHIC EXAMINATION OF THE ABDOMEN

Urinary System

The urinary bladder is full with an irregular, mottled echogenic vascularized and infiltrative mass on the dorsal wall extending towards the trigone, but not involving the trigon area. The mass measures 0.9 x 1.7 cm in size. The rest of the wall is of normal thickness with a smooth appearance. A small amount of floating, hyperechogenic sediment is present. No uroliths evident.

Normal appearance of the trigone area, proximal urethra, and iliac blood vessels.

Normal appearance and size of the iliac lymph nodes. Ureters not visualized, which can be considered a normal finding.

Normal renal size (left measured 5.7 cm, right measured 7.3 cm), architecture, echogenic appearance, cortico-medullary differentiation, which maintains a 1:3 cortex to medulla ratio, pelvis, and capsule. No infarcts, mineralization or renoliths evident. Normal color flow pattern is evident in both kidneys.

The prostate is small and hypoechogenic measuring 0.8 cm in width.

Adrenal Glands

The adrenal glands are bilaterally enlarged maintaining normal shape, echogenic appearance and appearance of the visible peri-adrenal vasculature. The left adrenal gland measured 2.43 cm in length x 0.8 cm and 0.94 cm in width. The right adrenal gland measured 2.58 cm in length x 0.6 cm and 0.95 cm in width.

Spleen

Normal size and echogenic appearance. Smooth homogenous parenchyma and regular curvilinear capsule. Normal volume of the splenic vasculature without any overt congestion or thrombosis evident. Diffuse, parenchymal mineralization is present. No inflammatory, neoplastic, infarction, or infiltrative changes evident. The spleen measured 1.3 cm in width.

Liver

Normal size with a diffuse increased echogenic and coarse appearance, normal portal markings, and regular curvilinear capsule. Few, hyperechogenic parenchymal nodules were present and measured up



PATIENT

Jackson Rogers

SPECIES

Canine

BREED

Boston Terrier

SEX

Neutered male

AGE

12 years

WEIGHT

25.3 lbs

INTERPRETED BY

Remo Lobetti, BVSc,
MMedVet (Med),
PhD, Dipl. ECVIM

IMAGING PERFORMED BY

Kathleen Byrnes

HOSPITAL NAME

Scotts Creek AH

REFERRING VET

Dr. Rendazzo

INVOICE

69953

DATE

1/9/26

to 1.2 x 2.1 cm in size. A large, irregular, hypoechogenic parenchymal mass is noted in the cranial aspect of the right lobe measuring 3.3 x 6.5 cm in size with areas of mineralization.

Gallbladder

The gallbladder is full containing a moderate amount of non-adhered, hyperechogenic sediment. Normal thickness and echogenic appearance of the wall. Normal size and appearance of the cystic and common bile duct.

Gastrointestinal

Normal appearance of the stomach, duodenum, small intestine, ileo-cecal junction, and colon with no loss of layering, 1:3 muscularis to mucosa ratio, normal wall thickness and peristaltic activity, and no distension of the lumen.

Pancreas

The visible sections of the pancreas are of normal size and echogenic appearance with a regular capsule. Normal echogenic appearance of the mesentery and fat surrounding the pancreas.

Free Abdomen

Normal mesenteric lymph nodes.

No ascites evident.

Thorax

Normal appearance of the heart. No pericardial or pleural effusion evident.

ULTRASONOGRAPHIC FINDINGS

- Hepatopathy.
- Hepatic nodules.
- Hepatic mass.
- Urinary bladder mass.
- Bilateral adrenomegaly.
- Splenic mineralization.
- Urinary bladder sediment.
- Gallbladder sediment.



PATIENT

Jackson Rogers

SPECIES

Canine

BREED

Boston Terrier

SEX

Neutered male

AGE

12 years

WEIGHT

25.3 lbs

INTERPRETED BY

Remo Lobetti, BVSc,
 MMedVet (Med),
 PhD, Dipl. ECVIM

IMAGING PERFORMED BY

Kathleen Byrnes

HOSPITAL NAME

Scotts Creek AH

REFERRING VET

Dr. Rendazzo

INVOICE

69953

DATE

1/9/26

INTERPRETATION OF THE FINDINGS & FURTHER RECOMMENDATIONS

Etiologies for the hepatopathy would be reactive hyperplasia, nodular hyperplasia, vacuolar and metabolic with hepatitis and infiltrative neoplasia highly unlikely differential diagnosis.

The most likely etiology for the hepatic nodules would be incidental nodular hyperplasia.

Etiologies for the hepatic mass would be neoplasia, granuloma and possibly organized hematoma.

The most likely etiology for the urinary bladder mass would be neoplasia with granuloma and chronic bacterial cystitis a less likely differential diagnosis.

The appearance of the adrenal glands would be consistent with pituitary dependent Cushing's disease.

The most likely etiology for the urinary bladder sediment would be hematuria with crystalluria and bacterial cystitis a less likely differential diagnosis.

Although the splenic mineralization is most likely an incidental finding, it can be associated with Cushing's disease.

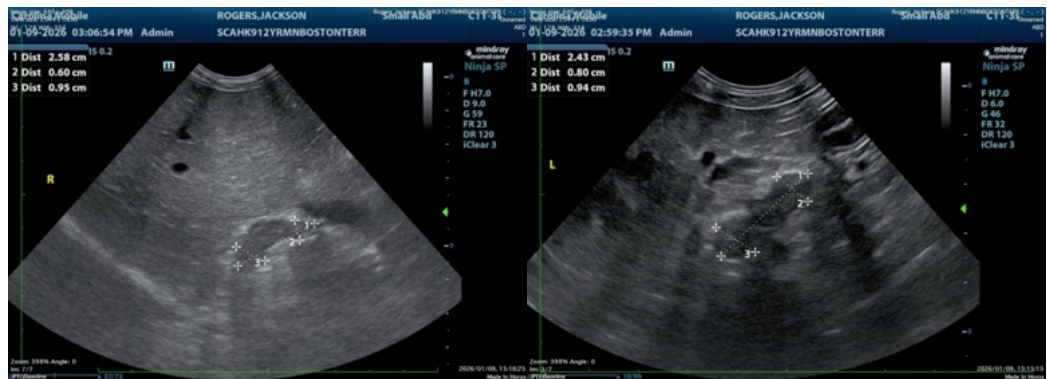The gallbladder sediment is most likely an incidental finding.

Further assessment would be urine culture, BRAF analysis and or catheter assisted aspirate of the urinary bladder mass, three view thoracic radiographs and FNA cytology of the liver and hepatic mass.

As the urinary bladder mass is infiltrative and extending towards the trigone area, surgical resection would not appear feasible.

If surgery is being contemplated for the hepatic mass, then CT scan would be recommended.

Further therapy would be dependent on an etiological diagnosis.





PATIENT

Jackson Rogers

SPECIES

Canine

BREED

Boston Terrier

SEX

Neutered male

AGE

12 years

WEIGHT

25.3 lbs

INTERPRETED BY

Remo Lobetti, BVSc,
 MMedVet (Med),
 PhD, Dipl. ECVIM

IMAGING PERFORMED BY

Kathleen Byrnes

HOSPITAL NAME

Scotts Creek AH

REFERRING VET

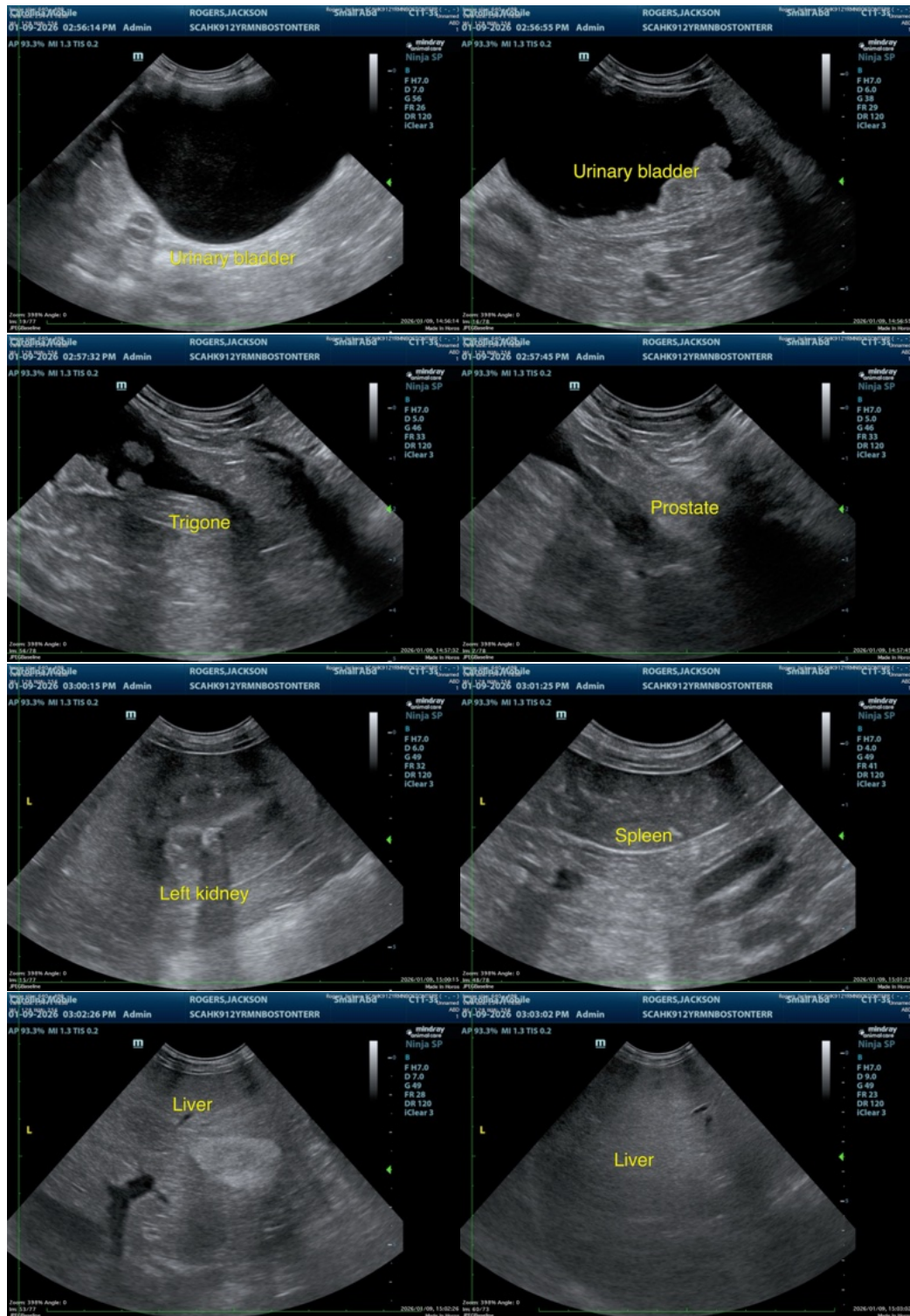
Dr. Rendazzo

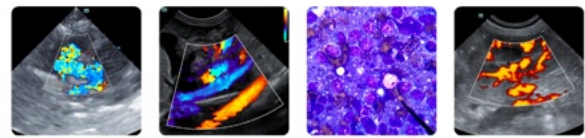
INVOICE

69953

DATE

1/9/26





PATIENT

Jackson Rogers

SPECIES

Canine

BREED

Boston Terrier

SEX

Neutered male

AGE

12 years

WEIGHT

25.3 lbs

INTERPRETED BY

Remo Lobetti, BVSc,
 MMedVet (Med),
 PhD, Dipl. ECVIM

IMAGING PERFORMED BY

Kathleen Byrnes

HOSPITAL NAME

Scotts Creek AH

REFERRING VET

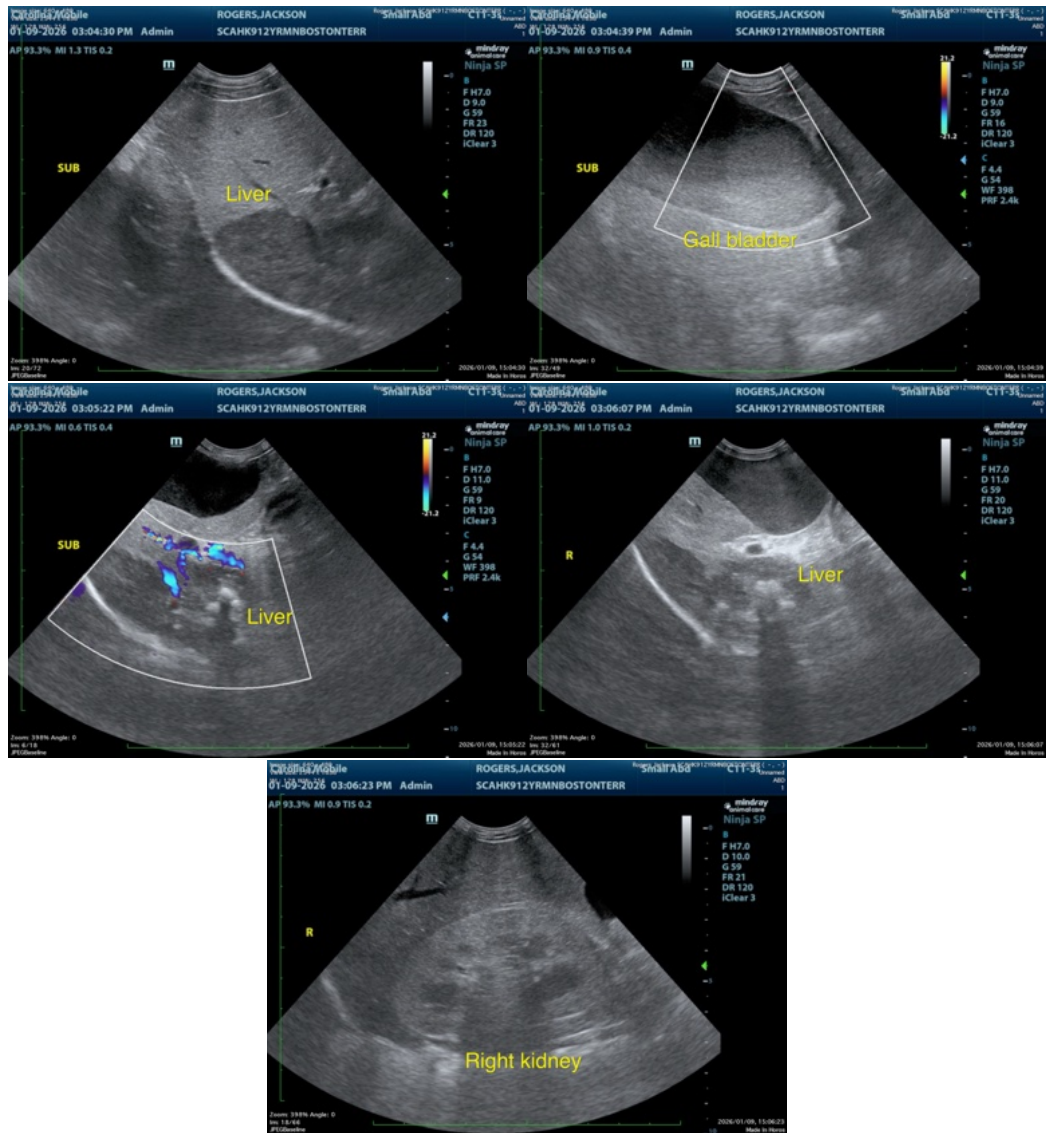
Dr. Rendazzo

INVOICE

69953

DATE

1/9/26



The information and recommendations provided are based on the images presented by the referring veterinarian/sonographer. No evaluation can be communicated regarding pathology that was not visible in the image/video clips provided.

Thank you for this referral. If the clinical or image interpretation does not parallel your findings or if I can be of any further assistance please contact me.

Remo Lobetti, BVSc, MMedVet (Med), PhD, Dipl. ECVIM (Internal Medicine)

info@sonopath.com